



HAL
open science

Three-dimensional biometrics using weight-bearing imaging shows relationship between knee and hindfoot axial alignment

Maryama Dufrenot, Louis Dagneaux, Celine Fernando, Patrick Chabrand, Matthieu Ollivier, François Lintz

► To cite this version:

Maryama Dufrenot, Louis Dagneaux, Celine Fernando, Patrick Chabrand, Matthieu Ollivier, et al.. Three-dimensional biometrics using weight-bearing imaging shows relationship between knee and hindfoot axial alignment. *Orthopaedics & Traumatology: Surgery & Research*, 2023, 109 (5), pp.103482. 10.1016/j.otsr.2022.103482 . hal-04285622

HAL Id: hal-04285622

<https://hal.umontpellier.fr/hal-04285622>

Submitted on 22 Feb 2024

HAL is a multi-disciplinary open access archive for the deposit and dissemination of scientific research documents, whether they are published or not. The documents may come from teaching and research institutions in France or abroad, or from public or private research centers.

L'archive ouverte pluridisciplinaire **HAL**, est destinée au dépôt et à la diffusion de documents scientifiques de niveau recherche, publiés ou non, émanant des établissements d'enseignement et de recherche français ou étrangers, des laboratoires publics ou privés.

Three-dimensional biometrics using weight-bearing imaging shows relationship between knee and hindfoot axial alignment

Maryama Dufrenot^{a,b,c,*}, Louis Dagneaux^{d,e}, Celine Fernando^f, Patrick Chabrand^{a,b},
Matthieu Ollivier^{a,b}, François Lintz^f

^a CNRS, institut des sciences du mouvement Étienne-Jules Marey, UMR 7287, Aix-Marseille université, 163, avenue de Luminy, 13009 Marseille, France

^b Institut du membre inférieur et de l'appareil locomoteur, APHM, hôpital Sainte-Marguerite, 270, boulevard de Sainte-Marguerite, 13009 Marseille, France

^c Newclip Technics, PA de la Lande Saint-Martin, 45, rue des Garottières, 44115 Haute-Goulaine, France

^d Département de chirurgie orthopédique du membre inférieur, CHU de Montpellier, hôpital Lapeyronie, 371 avenue du Doyen Gaston-Giraud, 39295 Montpellier cedex 05, France

^e Laboratoire de mécanique et génie civil (LMGC), université de Montpellier, 860, rue de Saint-Priest, 34090 Montpellier, France

^f Service de chirurgie du pied et de la cheville, Ramsay Santé – clinique de l'Union, boulevard de Ratalens, 31240 Saint-Jean, France

A B S T R A C T

Background: Existence of a relationship between knee and hindfoot alignments is commonly accepted, but not clearly proven. While studied in the coronal plane using 2D imaging, axial alignment has not been studied yet, likely requiring 3D measurements. We aimed to investigate how knee and hindfoot rotational alignments are related using 3D biometrics and modern 3D weight-bearing technologies.

Hypothesis: Hindfoot alignment is correlated with femoral and tibial torsions.

Patients and methods: All patients who underwent both weight-bearing CT (WBCT) and low dose biplanar radiographs (LDBR) were selected in this retrospective observational study, resulting in a cohort of 157 lower limbs from 99 patients. Patients' pathologies were stratified in subgroups and those with a history of trauma or surgery affecting lower limb alignment were excluded. Foot Ankle Offset was calculated from WBCT; femoral and tibial torsions and coronal alignment were calculated from LDBR, respectively. **Results:** Overall, mean Foot Ankle Offset was 1.56% (SD 7.4), mean femoral anteversion was 15.6° (SD 9.5), and mean external tibial torsion was 32.6° (SD 7.6). Moderate negative correlation between Tibial Torsion and Foot Ankle Offset was found in the whole series ($\rho = -0.23$, $p = 0.003$) and for non-pathologic patients ($\rho = -0.27$, $p = 0.01$). Linear models to estimate Tibial Torsion with Foot Ankle Offset and conversely were found, with a low adjusted R^2 ($3\% < R^2 < 7\%$). No relationship was found between FAO and femoral torsion.

Discussion: External tibial rotation was associated with varus hindfoot configuration in the group without pathologies, suggesting that compensatory mechanisms may occur between knee and hindfoot alignments. In pathological cases, however, the same relationship wasn't found, raising concerns about compensatory failure in spite of the numbers available. We didn't find similar correlations with the femur possibly because the hip has a degree of liberty in the axial plane.

Level of evidence: III, retrospective comparative study.

1. Introduction

Normal function in any lower limb joint requires biomechanical adaptations at distinct levels to ensure motion and stability under load. Muscles, tendons, ligaments, and bones must adjust, leading to compensatory mechanisms. As such, it is commonly accepted

that knee and hindfoot alignment are related [1,2]. A recent study highlighted a correlation in coronal plane between knee valgus and hindfoot valgus for patients without surgery or trauma that could affect knee or hindfoot alignment [3]. However, the mechanism of this relationship remains unclear, as well as its existence in other subsets of patients. Relationships between knee and foot rotational alignment have not been investigated yet.

Two-dimensional methods were considered the gold standard for lower-limb alignment measurement, regardless of their biases, which influence measurements and their interpretations (patient

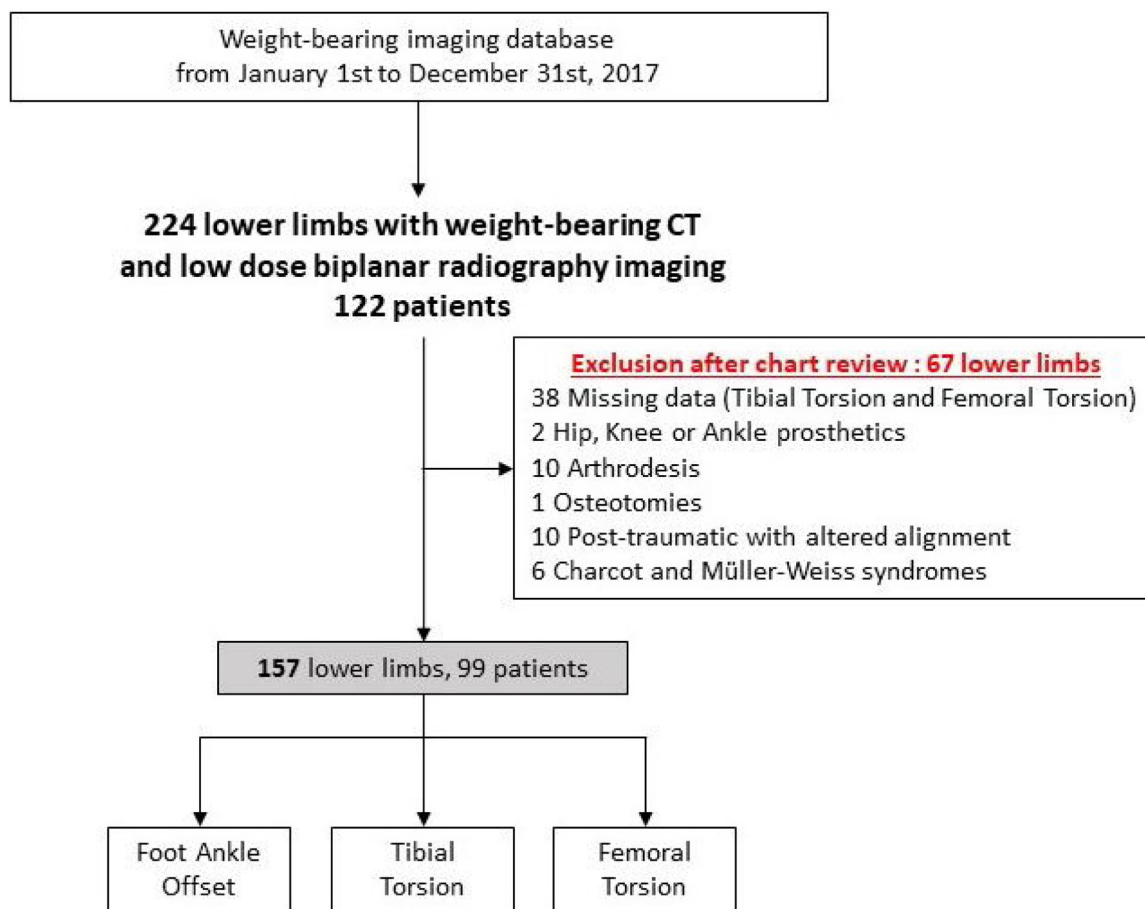


Fig. 1. Flow chart.

positioning, projections, fan effect) [4,5]. Bones and joints are 3D objects; thus, 3D biometrics are necessary to fully understand ongoing interactions. This point is even more important when measurements are used for pre- or postoperative assessment [6]. Recently, 3D weight-bearing imaging using Cone Beam CT or stereoradiography have enabled measurements (biometrics) with low dose exposure. Biplanar stereoradiography is an alternative to conventional radiography, which reduces dose exposure and allows for lower limb rotational alignment assessment, avoiding the use of CT-scan. Weight-bearing CT (WBCT) imaging is an alternative to conventional CT, with an irradiation comparable to conventional plain radiographs series for the foot. Three-dimensional weight-bearing acquisition also helps to refine diagnosis, as joints space and bones position are modified compared to supine position [7–9].

The aim of this study was to investigate relationships between hip, knee, and foot axial alignments using 3D biometrics and modern weight-bearing technologies. We hypothesized that external tibial rotation should correlate with hindfoot varus, and, or, femoral anteversion.

2. Patients and methods

2.1. Patients

Patients who underwent bilateral Weight-Bearing CT and Low-Dose Biplanar Radiography (LDBR) in 2017 as part of standard of care follow-up, were selected retrospectively (Fig. 1). Indications were by order of frequency: preoperative assessment for foot or ankle fusion, ankle instability, fractures, foot or ankle undetermined pain (Table 1). All healthy or asymptomatic contralateral

Table 1
Patients' pathologies.

Pathology	Number of feet	Pathology group
Ankle lateral instability	19 (50%)	Lateral laxity and/or medial arthrosis <i>n</i> = 38 (55%)
Ankle medial arthrosis	4 (11%)	
Talonavicular arthrosis	1 (3%)	Medial laxity and/or lateral arthrosis <i>n</i> = 34 (49%)
Cavus, varus and cavovarus foot	5 (13%)	
Tarsometatarsal arthrosis 2/3	1 (3%)	Other <i>n</i> = 7 (1%)
Fibular tendinopathy	1 (3%)	
Talar dome articular lesions	3 (8%)	
Lateral chronic laxity	2 (5%)	
Varus knee	2 (5%)	
Flat foot	19 (56%)	
Posterior tibial tendinopathy or instability	2 (6%)	
Calcaneonavicular synchondrosis	1 (3%)	
Subtalar arthrosis	1 (3%)	
Brown Sequard syndrome	1 (3%)	
Hallux valgus	5 (71%)	
Haglund syndrome	2 (29%)	

One pathology per patient was considered for clarity. Number of cases and percentage over the considered group (bold) and whole series (italic) are presented.

limbs were included too. Mean age was 51 years (standard deviation (SD) 16), mean body mass index (BMI) was 26 kg/cm² (SD 5), 52% being females (Table 2).

3. Methods

Weight-bearing CT images were acquired using a PedCAT™ unit (CurveBeam LLC, Hatfield, PA, USA), while patients were standing still in a comfortable position. A standardized imaging protocol

	Min	Max	Mean	Standard deviation
Age (years)	18	82	50.6	16.5
Body Mass Index (kg/m ²)	17.4	37.7	26.2	4.9
Foot Ankle Offset (%)	-13.8	24.6	1.6	5.4
Tibial torsion (°)	9	62	32	7.6
Femoral torsion (°)	-9	43	15.6	9.5
Sex		83 (53%)		
Male		74 (47%)		
Female				
Lower limb side		77 (49%)		
Right		80 (51%)		
Left				
Pathology groups		84		
Non-pathologic		23		
Medial laxity		42		
Lateral laxity		8		
Other				
Coronal alignment groups				
Knee				
Normal			115	
Varus			14	
Valgus			15	
Valgus			8	
Valgus			5	
Hindfoot				
Varus			14	
Valgus			15	
Valgus			8	
Valgus			5	

and settings were used: tube voltage, 96 kV; tube current, 7.5 mAs; matrix, 160 × 160 × 130; pixel size, 0.4 mm; and slice interval, 0.4 mm.

The EOS System (EOS imaging, Paris, France) was used for lower-limb LDBR imaging, including pelvic rim. Patients placed one foot slightly anterior to the other and lower limb neutral position was controlled relative to patellar position. Bone 3D surface reconstruction was performed in the SterEOS software (EOS Imaging, Paris, France) by one of the author (MD) [10].

3.1. Methods of assessment

Hindfoot alignment was assessed on WBCT images using the Foot Ankle Offset (FAO), a fully 3D measurement in the axial plane [11,12]. To calculate the FAO, 4 landmarks were identified on the PedCAT images (Fig. 2): centermost point of the talar dome, first (M1) and fifth (M5) metatarsal head lowest points and calcaneus lowest point (C). The last 3 points defined a plane, on which the talar point was projected (T). The FAO was the ratio of the distance between T and the middle line of the foot (connecting C and the middle of [M1M5]), divided by the length of the same line, given in percentage. In the axial plane, it gives an indication about the ankle offset relatively to the foot: it can be a medial or lateral. If foot and ankle are perfectly aligned, FAO = 0%.

One of the authors positioned the landmarks (LD, Fig. 2) and the FAO was calculated using TALAS™, a semi-automatic software (CurveBeam, Hatfield, PA USA).

Tibial Torsion and Femoral Torsion were calculated from EOS views in SterEOS (Fig. 2). Conventionally, femoral anteversion and external tibial torsion were considered positive.

Coronal alignments and pathology sorting was performed. Alignment subgroups were constituted as previously described, taking into account combinations of knee varus/valgus and neutral alignment, assessed using Hip Knee Angle (HKA) and hindfoot varus/valgus based on published boundaries [3,13–15]:

- neutral knee alignment: $-3^\circ < \text{HKA} < 3^\circ$;

- knee varus and hindfoot varus: $\text{HKA} < -3^\circ$ and $\text{FAO} < 2.3\%$;
- knee varus and hindfoot valgus: $\text{HKA} < -3^\circ$ and $\text{FAO} > 2.3\%$;
- knee valgus and hindfoot varus: $\text{HKA} > 3^\circ$ and $\text{FAO} < 2.3\%$;
- knee valgus and hindfoot valgus: $\text{HKA} > 3^\circ$ and $\text{FAO} > 2.3\%$.

Regarding foot and ankle pathology, 4 subgroups were constituted (Table 1): medial laxity pathology and/or lateral arthrosis (medial laxity), lateral laxity pathology and/or medial arthrosis (lateral laxity), other pathology, non-pathologic (lower limbs without knee, ankle and foot pathology) [16–18].

3.2. Statistical analysis

Statistics were done using R 1.2.5001 (R project for statistical computing <https://www.r-project.org/foundation/>), with $\alpha = 0.05$.

Normality was assessed using the Shapiro-Wilk test. Subgroup variables distribution was compared using Kruskal-Wallis and Kruskal-Nemenyi post hoc tests. When Kruskal-Wallis and Kruskal-Nemenyi post hoc tests were significant, Pearson's rho (parametric) or Spearman's rho (non-parametric) correlation test was performed. Correlation variables were FAO and Tibial Torsion. In subgroups with significant correlation, simple linear regression models were calculated. Linear relationships were studied for the whole group and subgroups.

Proper results analysis required post hoc power calculation for correlation and adjusted R-squared (R^2) calculation for regression. The latter allowed regression models comparison and power estimation.

4. Results

Variables distributions are presented in Table 2 (whole series) and in Online material (subgroups). Kruskal-Nemenyi post hoc test was significant for Tibial Torsion and FAO (Table 3, $0.01 < p < 0.04$). Tibial Torsion was significantly higher for men than women (Table 3, Wilcoxon test, $p = 0.04$).

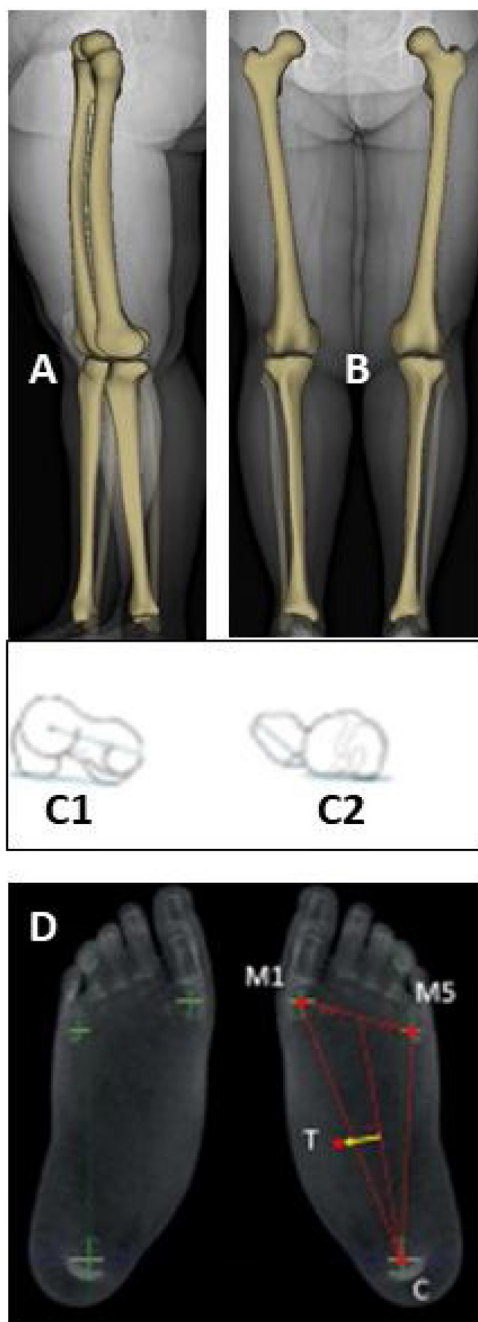


Fig. 2. Weight-bearing lower limb imaging. Low dose biplanar radiography (A: sagittal, B: coronal) and 3D reconstruction to measure femoral (C1) and tibial (C2) torsions. Weightbearing CT to measure Foot Ankle Offset (D).

Kruskal-Wallis test for Femoral Torsion wasn't significant ($p=0.05$), so it wasn't considered for correlation nor regression. Moderate negative correlation between Tibial Torsion and FAO and linear models were found (Fig. 3, $\rho=-0.23$, $p=0.003$ and $\rho=-0.27$, $p=0.01$).

In the whole series and the non-pathologic group, when distal tibia rotates externally relative to proximal tibia, hindfoot varus increases. In the whole series, 3% of FAO changes can be predicted by Tibial torsion modifications, and 6% of Tibial Torsion changes can be predicted by FAO modifications. In the non-pathologic group, 3% of FAO changes can be predicted by Tibial Torsion modifications, and 7% of Tibial Torsion changes can be predicted by FAO modifications.

5. Discussion

In this study, linear negative correlation between Tibial Torsion and FAO and significant regression models were found. Our hypothesis was partially confirmed. We didn't find relationship between axial hip and knee nor hindfoot alignments.

In literature, studies about knee and foot alignment can be found in the context of total knee arthroplasty and supramalleolar osteotomy [2,19,20]. These findings can't be compared to our study because we focused on relationship for which natural degenerative processes were at work. For patients without surgery, previous studies using conventional radiographs always considered knee and hindfoot alignments in the coronal plane, because their axial components can only be assessed using 3D imaging modalities (Table 4). Desai et al. showed no difference in axial knee alignment for patients with primary symptomatic flatfoot compared to control subject, which is consistent with the absence of correlation in the medial laxity group of our study [20]. Norton et al. found a regression model for which 10% of the variance in the overall hindfoot angle could be explained by changes in the ankle line convergence angle [24]. This last angle considered a coronal axis that could be affected by changes in Tibial Torsion, as distal tibia shape on X-ray images depends on tibia rotation. In our study, 3% to 7% of FAO or Tibial Torsion variance could be explained by modifications in the other one. These findings can be compared bearing in mind that our results also accounted for non-pathologic patients, which weren't included in their study. Tibial torsion in the population is known to be higher in men than female, which was confirmed in the present study. It does not have an influence in our findings: for a same value of FAO, Tibial Torsion would be equivalent for men and women, and conversely. Nejima et al. investigated knee torsional and coronal alignments using Tibial Torsion, Femoral Torsion, HKA, and two other angles, but they didn't include foot alignment. They didn't find correlation between Femoral Torsion, Tibial Torsion and HKA, as in the present study [25]. The absence of correlation with Femoral Torsion could be explained by the fact that hip has an important range of motion in the axial plane, unlike knee and hindfoot [26]. Thus, knee has to adapt to foot, but it doesn't have to adapt to hip. Dagneaux et al. used the FAO to investigate knee and foot coronal alignment [3]. In our study, FAO was used for hindfoot both coronal and axial alignment. It's a recent measurement of hindfoot varus/valgus, which is known to be a coronal deformity, while measured in the axial plane and considering foot rotation, which makes it is comparable to Tibial and Femoral Torsions. It's a reliable measurement with intra- and inter-class correlation coefficient of 0.99 and 0.97 respectively [12]. Mean FAO in population with neutral alignment is $2.3\% \pm 2.9\%$.

Knee and foot relationships are multidimensional, occurring simultaneously in all planes (coronal, axial, sagittal). We focused on the axial plane, while coronal alignment combinations were considered to create subgroups. As such, our statistical approach was multi-dimensional, integrating both coronal and axial components. Moreover, our results highlighted that relationships between Tibial Torsion and FAO are small, meaning that knee and hindfoot relationships cannot be explained using bone biometrics only. It is reasonable to hypothesize that knee and hindfoot alignments interactions aren't linear and could be affected by other parameters, like soft tissue laxity or BMI, for example. Innovative multidimensional method for nonlinear analysis would give the opportunity to fully investigate these relationships and provide more data on limits between physiologic and pathologic conditions.

We acknowledge several limitations in the present study. First, sample size is a weakness given the number of subjects in specific subgroups other pathology ($n=8$), Valgus Knee/Varus Hindfoot ($n=8$) and Varus Knee/Varus Hindfoot ($n=5$). It could explain why no correlations were found in these subgroups.

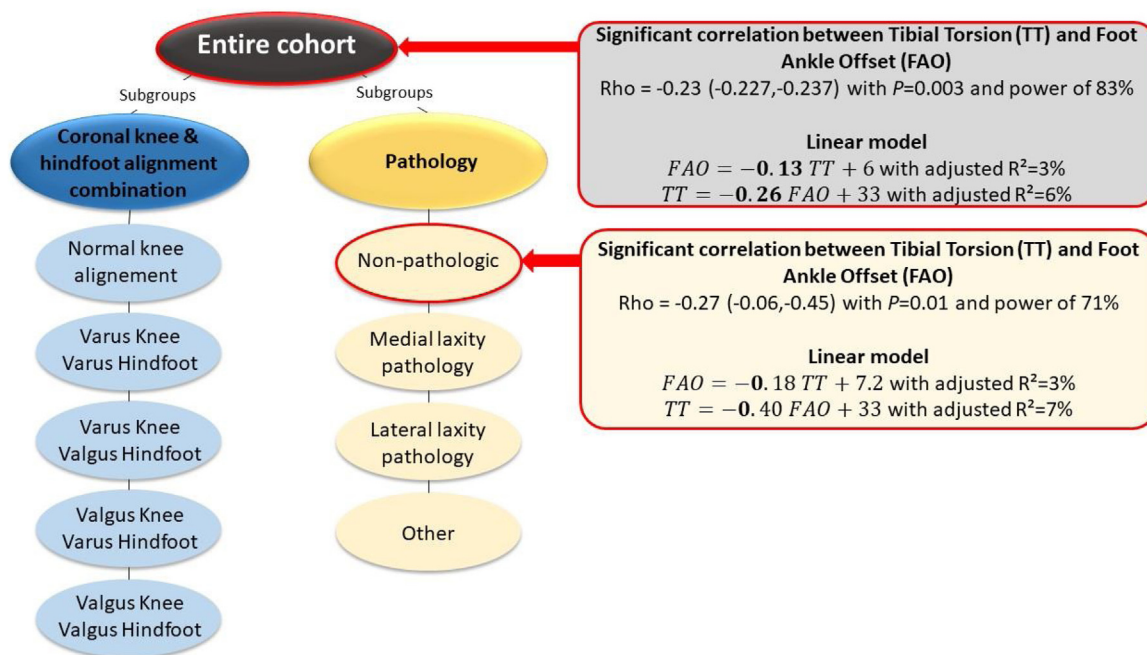


Fig. 3. Linear correlation and regression results. Moderate negative correlations were found between tibial torsion (TT) and Foot Ankle Offset (FAO) in whole series ($\rho = -0.23$, power = 3%) and non-pathologic group ($\rho = -0.27$, power = 71%). Linear models to estimate FAO using TT and conversely were found, with low adjusted R^2 ($3\% < R^2 < 7\%$).

Table 3

Kruskal-Wallis, Kruskal-Nemenyi post hoc and Wilcoxon tests p -values (significant are colored).

	Kruskal-Wallis test		Wilcoxon test		
	Knee and hindfoot coronal alignment	Pathology	Sex		
Foot Ankle Offset	< 0.001 ^a	< 0.001 ^a	0.54		
Tibial torsion	0.07	0.63	0.04 ^a		
Femoral torsion	0.57	0.05	0.90		
Kruskal-Nemenyi post hoc test for Foot Ankle Offset by coronal alignment					
	Knee Hindfoot	Normal	Varus Varus	Varus Valgus	Valgus Varus
Knee Varus	Varus	0.08			
Varus	Valgus	0.02 ^a	< 0.01 ^a		
Valgus	Varus	0.22	0.99	< 0.01 ^a	
Valgus	Valgus	0.05	0.01 ^a	0.93	< 0.01 ^a
Kruskal-Nemenyi post hoc test for Foot Ankle Offset by pathology					
	Non-pathologic	Medial laxity	Lateral laxity		
Medial laxity	< 0.01 ^a				
Lateral laxity	0.23	< 0.01 ^a			
Other	0.99	0.04 ^a	0.90		

^a p -values that are significant.

Another explanation may be that the standard model by which a correlation exists in asymptomatic or normal patients may not apply once symptoms or pathology is installed. With 3D imaging democratization, further studies should allow to include more patients in subgroups and explore relationships with sufficient statistical power. When considering 157 lower limbs and looking at normal knee alignment ($n = 115$) and non-pathologic ($n = 84$) subgroups, representative of a healthy knee and hindfoot population, we found a good correlation power (83%) between FAO and Tibial Torsion in the whole series and slightly less in the

non-pathologic group (73%). It could be interesting to compare our results with those of a subset of healthy volunteers but exposing them to unnecessary radiation raises ethical concerns. Secondly, 3D EOS reconstructions were used to assess tibia and femur rotational alignment. It uses 3D parametric models and statistical inference to approximate bones shape based on two orthogonal 2D X-rays [17], which does not exactly represent real 3D bones shape. The automatically generated model can be manually re-adjusted to get closer to actual bones configuration, but the bone's shape doesn't affect its axis. It has been applied in

Table 4

Literature review regarding knee and foot alignment relationships without surgery.

Authors	Year	Biometric		Group	Results
		Knee	Foot		
Dagneaux et al. [3]	2020	2D	3D	OA: K/L < 3	Correlation: hindfoot valgus and knee valgus ($\rho = 0.53, p = 0.01$)
Burssens et al. [21]	2020	2D	2D	OA: Takakura ≥ 1 OA: Takakura = 0	Correlation: hindfoot valgus and knee varus ($\rho = -0.38, p < 0.0001$) Correlation: hindfoot varus and knee varus ($\rho = 0.46, p < 0.0001$) Hindfoot valgus and knee valgus ($\rho = 0.4, p < 0.0001$)
Mansur et al. [22]	2020	2D	2D	OA: AOFAS score > 54 (hindfoot)	Correlation: hindfoot varus and knee valgus ($\rho = 0.56, p < 0.05$) Association between knee valgus and hindfoot varus
Ohi et al. [23]	2017	2D	2D	OA: K/L ≥ 1	Linear model: knee valgus and pronation angle of the calcaneus (regression coefficient 0.33 per degree, $p = 0.005$)
Norton et al. [24]	2015	2D	2D	OA: K/L ≥ 3	Correlation: knee valgus and hindfoot varus ($\rho = -0.03, p < 0.0012$) Knee varus and hindfoot valgus ($\rho = -0.35, p > 0.0001$) Correlation was stronger in patients with larger deformities Linear model: 10% of variance in hindfoot angle can be explained by changes in ankle convergence angle

OA: osteoarthritis; K/L: Kellgren-Lawrence.

clinical practice and is widely used for bones deformity assessment (including pediatrics) [27]. The EOS measurements are reliable, with an inter- and intraclass correlation coefficients of 0.82 and > 0.83 for Tibial Torsion and 0.84 and > 0.79 for Femoral Torsion, respectively [13,28]. Correlation with those measured on conventional CT-scanner has also been shown [29]. This might change in the future, with WBCT emergence as high as knee and hip level, which should allow more precise evaluation and correlation.

6. Conclusion

Our results confirm that tibia external rotation from proximal to distal is associated with a more varus hindfoot configuration in the group without pathologies and the whole series. This seems to confirm that compensatory mechanisms exist between knee and hindfoot. However, no correlation was highlighted in specific pathologic populations, possibly because these mechanisms fail when pathologies are installed. Further studies should include larger cohorts and more variables to investigate axial alignment relationships in pathologic subgroups with sufficient statistical power. It would allow to determine if, in clinical practice, tibial nor femoral rotation should be considered in foot realignment procedures, and conversely. We didn't find similar correlations with the femur, possibly because the hip has an important range of motion in the axial plane.

Ethical review committee statement

All procedures performed satisfied the ethical standard of the 1964 Helsinki Declaration and its later amendments or comparable ethical standards. The study also followed STROBE (Strengthening the Reporting of Observational Studies in Epidemiology) guidelines.

The ethical approval from Ramsay Santé Institutional Ethics Committee was obtained. IRB number: COS-RGDS-2018-05-002-Avis IRB-LINTZ-F.

Disclosure of interest

MD is a paid employee of Newclip technics.

LD is a paid consultant of Newclip technics.

MO is a paid consultant of Newclip technics.

PC has contracts with Newclip Technics, RLC Systems, Selenium medical.

FL is a paid consultant of CurveBeam LLC, is a board/committee member of AFCP, EFAS, International WBCT Society and took out a patent for TALAS™.

The CF author declares that he has no competing interest.

Funding

This research didn't receive any specific grant from funding agencies in the public, commercial, or not-for-profit sectors.

Contributions

- [1] Okamoto Y, Otsuki S, Jotoku T, Nakajima M, Neo M. Clinical usefulness of hindfoot assessment for total knee arthroplasty: persistent postoperative hindfoot pain and alignment in pre-existing severe knee deformity. *Knee Surg Sports Traumatol Arthrosc* 2017;25:2632–9.

- [2] Jeong BO, Kim TY, Baek JH, Jung H, Song SH. Following the correction of varus deformity of the knee through total knee arthroplasty, significant compensatory changes occur not only at the ankle and subtalar joint, but also at the foot. *Knee Surg Sports Traumatol Arthrosc* 2018; <http://dx.doi.org/10.1007/s00167-018-4840-7>.
- [3] Dagneaux L, Dufrenot M, Bernasconi A, Bedard NA, de Cesar Netto C, Lintz F. Three-dimensional biometrics to correlate hindfoot and knee coronal alignments using modern weightbearing imaging. *Foot Ankle Int* 2020; <http://dx.doi.org/10.1177/1071100720938333> [1071100720938333].
- [4] Kawakami H, Sugano N, Yonenobu K, Yoshikawa H, Ochi T, Hattori A, et al. Effects of rotation on measurement of lower limb alignment for knee osteotomy. *J Orthop Res* 2004;22:1248–53.
- [5] Baverel L, Brilhault J, Odri G, Boissard M, Lintz F. Influence of lower limb rotation on hindfoot alignment using a conventional two-dimensional radiographic technique. *Foot Ankle Surg* 2017;23:44–9; <http://dx.doi.org/10.1016/j.fas.2016.02.003>.
- [6] Barbotte F, Delord M, Pujol N. Coronal knee alignment measurements differ on long-standing radiographs vs. by navigation. *Orthop Traumatol Surg Res* 2021;103112; <http://dx.doi.org/10.1016/j.otsr.2021.103112>.
- [7] Thawait GK, Demehri S, AlMuhit A, Zbijewski W, Yorkston J, Del Grande F, et al. Extremity cone-beam CT for evaluation of medial tibiofemoral osteoarthritis: initial experience in imaging of the weight-bearing and non-weight-bearing knee. *Eur J Radiol* 2015;84:2564–70; <http://dx.doi.org/10.1016/j.ejrad.2015.09.003>.
- [8] Segal NA, Nevitt MC, Lynch JA, Niu J, Torner JC, Guermazi A. Diagnostic performance of 3D standing CT imaging for detection of knee osteoarthritis features. *Phys Sportsmed* 2015;43:213–20; <http://dx.doi.org/10.1080/00913847.2015.1074854>.
- [9] Richter M, Lintz F, de Cesar Netto C, Barg A, Burssens A. Results of more than 11,000 scans with weightbearing CT – impact on costs, radiation exposure, and procedure time. *Foot Ankle Surg* 2019; <http://dx.doi.org/10.1016/j.fas.2019.05.019> [S1268773119300967].
- [10] Yan W, Xu X, Xu Q, Yan W, Sun Z, Jiang Q, et al. Femoral and tibial torsion measurements based on EOS imaging compared to 3D CT reconstruction measurements. *Ann Transl Med* 2019;7:10.
- [11] Lintz F, Welck M, Bernasconi A, Thornton J, Cullen NP, Singh D, et al. 3D biometrics for hindfoot alignment using weightbearing CT. *Foot Ankle Int* 2017;38:684–9.
- [12] Zhang JZ, Lintz F, Bernasconi A, the Weight Bearing CT, International Study Group, Zhang S. 3D biometrics for hindfoot alignment using weightbearing computed tomography. *Foot Ankle Int* 2019;40:720–6.
- [13] Gaumétou E, Quijano S, Ilharborde B, Presedo A, Thoreux P, Mazda K, et al. EOS analysis of lower extremity segmental torsion in children and young adults. *Orthop Traumatol Surg Res* 2014;100:147–51; <http://dx.doi.org/10.1016/j.otsr.2013.09.010>.
- [14] Nam D, Shah RR, Nunley RM, Barrack RL. Evaluation of the 3-dimensional, weight-bearing orientation of the normal adult knee. *J Arthroplasty* 2014;29:906–11; <http://dx.doi.org/10.1016/j.arth.2013.10.024>.
- [15] Siboni R, Vialla T, Joseph E, LiArno S, Faizan A, Martz P, et al. Coronal and sagittal alignment of the lower limb in Caucasians: analysis of a 3D CT database. *Orthop Traumatol Surg Res* 2022;108:103251; <http://dx.doi.org/10.1016/j.otsr.2022.103251>.
- [16] Perera A, Guha A. Clinical and radiographic evaluation of the cavus foot. *Foot Ankle Clin* 2013;18:619–28; <http://dx.doi.org/10.1016/j.fcl.2013.08.010>.
- [17] Boerum DHV, Sangeorzan BJ. Biomechanics and pathophysiology of flat foot. *Foot Ankle Clin* 2003;419–30; [http://dx.doi.org/10.1016/s1083-7515\(03\)00084-6](http://dx.doi.org/10.1016/s1083-7515(03)00084-6).
- [18] Czajka CM, Tran E, Cai A, DiPreta JA. Ankle sprains and instability. *Med Clin North Am* 2014;98(2):313–29; <http://dx.doi.org/10.1016/j.mcna.2013.11.003>.
- [19] Cho W-S, Cho H-S, Byun S-E. Changes in hindfoot alignment after total knee arthroplasty in knee osteoarthritic patients with varus deformity. *Knee Surg Sports Traumatol Arthrosc* 2017;25:3596–604; <http://dx.doi.org/10.1007/s00167-016-4278-8>.
- [20] Desai SS, Shetty GM, Song H-R, Lee SH, Kim TY, Hur CY. Effect of foot deformity on conventional mechanical axis deviation and ground mechanical axis deviation during single leg stance and two leg stance in genu varum. *Knee* 2007;14:452–7; <http://dx.doi.org/10.1016/j.knee.2007.07.009>.
- [21] Burssens ABM, Buedts K, Barg A, Vluggen E, Demey P, Saltzman CL, et al. Is lower-limb alignment associated with hindfoot deformity in the coronal plane? A weightbearing CT analysis. *Clin Orthop* 2020;478:154–68; <http://dx.doi.org/10.1097/CORR.0000000000001067>.
- [22] Mansur H, Rocha FA, Sousa Filho PGTD, Castro Junior IMD. Relationship between the knee and hindfoot axes in patients with severe knee osteoarthritis. *Acta Orthopédica Bras* 2020;28:229–32.
- [23] Ohi H, Iijima H, Aoyama T, Kaneda E, Ohi K, Abe K. Association of frontal plane knee alignment with foot posture in patients with medial knee osteoarthritis. *BMC Musculoskelet Disord* 2017;18:246.
- [24] Norton AA, Callaghan JJ, Amendola A, Phisitkul P, Wongsak S, Liu SS, et al. Correlation of knee and hindfoot deformities in advanced knee OA: compensatory hindfoot alignment and where it occurs. *Clin Orthop Relat Res* 2015;473:166–74.
- [25] Nejima S, Akamatsu Y, Kobayashi H, Tsuji M, Mitsunashi S, Sasaki T, et al. Relationship between lower limb torsion and coronal morphologies of the femur and tibia in patients with medial knee osteoarthritis. *BMC Musculoskelet Disord* 2020;21:254.
- [26] Polkowski GG, Clohisy JC. Hip biomechanics. *Sports Med Arthrosc Rev* 2010;18:56–62.
- [27] Delin C, Silvera S, Bassinet C, Thelen P, Rehel J-L, Legmann P, et al. Ionizing radiation doses during lower limb torsion and anteversion measurements by EOS stereoradiography and computed tomography. *Eur J Radiol* 2014;83:371–7.
- [28] Chaibi Y, Cresson T, Aubert B, Hausselle J, Neyret P, Hauger O, et al. Fast 3D reconstruction of the lower limb using a parametric model and statistical inferences and clinical measurements calculation from biplanar X-rays. *Comput Methods Biomech Biomed Engin* 2012;15:457–66.
- [29] Buck FM, Guggenberger R, Koch PP, Pfirrmann CWA. Femoral and tibial torsion measurements with 3D models based on low-dose biplanar radiographs in comparison with standard CT measurements. *Am J Roentgenol* 2012;199:W607–12.