



**HAL**  
open science

## Teledentistry and forensic odontology: Cross-sectional observational comparative pilot study

Nicolas Giraudeau, C. Duflos, Chloé Moncayo, Ganesh Marin, Eric Baccino,  
Laurent Martrille, Camille Inquimbert

### ► To cite this version:

Nicolas Giraudeau, C. Duflos, Chloé Moncayo, Ganesh Marin, Eric Baccino, et al.. Teledentistry and forensic odontology: Cross-sectional observational comparative pilot study. *Forensic Science International*, Elsevier, 2021, 326, pp.110932. 10.1016/j.forsciint.2021.110932 . hal-03610803

**HAL Id: hal-03610803**

**<https://hal.umontpellier.fr/hal-03610803>**

Submitted on 16 Mar 2022

**HAL** is a multi-disciplinary open access archive for the deposit and dissemination of scientific research documents, whether they are published or not. The documents may come from teaching and research institutions in France or abroad, or from public or private research centers.

L'archive ouverte pluridisciplinaire **HAL**, est destinée au dépôt et à la diffusion de documents scientifiques de niveau recherche, publiés ou non, émanant des établissements d'enseignement et de recherche français ou étrangers, des laboratoires publics ou privés.



## Teledentistry and forensic odontology: Cross-sectional observational comparative pilot study



N. Giraudeau<sup>a,b,\*</sup>, C. Duflos<sup>c</sup>, C. Moncayo<sup>b</sup>, G. Marin<sup>c</sup>, E. Baccino<sup>d</sup>, L. Martrille<sup>d,e</sup>,  
C. Inquimbert<sup>b,f</sup>

<sup>a</sup> CEPEL, UMR 5112, CNRS, Université de Montpellier, Montpellier, France

<sup>b</sup> Dental department, University Hospital of Montpellier, Univ Montpellier, Montpellier, France

<sup>c</sup> Service Clinical Research and Epidemiology Unit, Medical Information Department, CHU Montpellier, Univ Montpellier, Montpellier, France

<sup>d</sup> Forensic Medicine Unit, CHU de Montpellier, Univ Montpellier, Montpellier, France

<sup>e</sup> Aix Marseille Univ, CNRS, EFS, ADES, Marseille, France

<sup>f</sup> Systematic Health Care, EA 4129, University of Lyon 1, Lyon, France

### ARTICLE INFO

#### Article history:

Received 18 February 2021

Received in revised form 2 July 2021

Accepted 20 July 2021

Available online 28 July 2021

#### Keywords:

Forensic dentistry  
Teledentistry  
Odontogram  
Identification  
Telemedicine

### ABSTRACT

Forensic dentistry is the branch of forensic science concerned with the study of teeth and jaws. To facilitate the work of experts, new comparative identification tools are emerging, with digital techniques such as the intra-oral camera, which are revolutionising current techniques in forensic dentistry.

**Objective:** The aim of this study is to evaluate the diagnostic quality of the post-mortem odontogram carried out remotely via a video of the oral cavity using an intra-oral camera. The gold standard is the post-mortem odontogram obtained via the standard identification technique during the clinical examination.

**Materials and methods:** 25 deceased patients were included in the study and the data were collected in the Forensic Medicine and Thanatology Department at the University Hospital of Montpellier. The protocol was divided into three stages: the gold standard consultation, the recording of videos with the Soprocare® camera, and the remote analysis of the images obtained. The gold standard consultation and the remote analysis were carried out by two separate dental surgeons responsible for completing a clinical file, used to establish the odontogram of the deceased patient.

**Results:** The study was carried out on 25 deceased subjects, between 13 May and 12 June 2019. Our sample was composed of 68% men and 32% women. A sensitivity threshold of 0.97 was observed for the performance of the odontogram, i.e., for all the teeth actually present in the mouth for all subjects in the study, 97% of them were identified with the videos taken using the intraoral camera. The examination with the intra-oral camera demonstrated a good diagnostic performance in the detection of missing teeth with a PPV of 97.9% and a NPV of 98.2%. Practitioner became more skilled at recording the videos with the intra-oral camera. One can therefore note an ease in the handling of this digital tool, which gradually improved with the number of subjects included in the study

**Conclusions:** The Soprocare® intraoral camera has an acceptable diagnostic validity in establishing the odontogram of the deceased. It enables fundamental elements to be detected with optimal efficiency. However, several points still need to be improved, in order to make the use of the camera during data collection as easy and efficient as possible.

© 2021 The Authors. Published by Elsevier B.V.  
CC BY-NC-ND 4.0

## 1. Introduction

In France, teledentistry is a form of remote medical practice using information and communication technologies. It brings together one

or more healthcare professionals, including a medical professional and, where appropriate, other professionals providing care to the patient. Teledentistry has the potential to improve access to care, particularly in under-resourced areas [1,2]. It enables improved efficiency and organisation through coordinated care as close as possible to the patients' home [3–5]. In the literature, several authors have highlighted the value of teledentistry [6,7]. Within the Montpellier team, teledentistry has been used for more than 6 years,

\* Corresponding author at: CEPEL, UMR 5112, CNRS, Université de Montpellier, Montpellier, France.

E-mail address: [nicolas.giraudeau@umontpellier.fr](mailto:nicolas.giraudeau@umontpellier.fr) (N. Giraudeau).

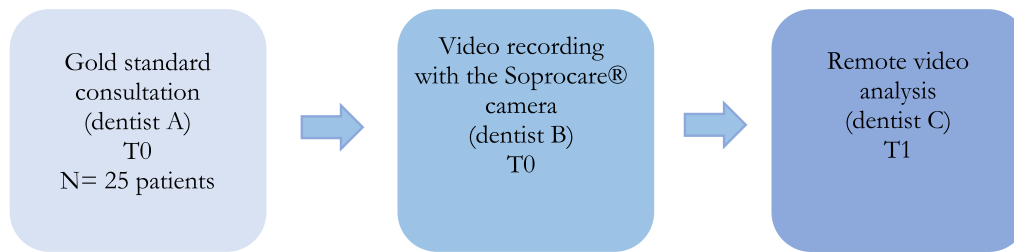


Fig. 1. Study flow.

particularly in the organisation of care for elderly patients [8] and for people with disabilities [9]. This field has evolved considerably in recent years thanks to new technologies and the digital age. To facilitate the work of experts, new examination tools are now emerging, and in particular, intra-oral cameras [10–14].

Very few studies have researched teledentistry in the field of forensic dentistry. The forensic dentist, a member of the forensic team, is commissioned, for example, by the judicial authorities to identify corpses and study bite marks on living or deceased persons. Specifically, in France, His/her contribution to the identification is based on the establishment of an odontogram, which is then distributed to the national network of odontologists to search for compatible odontograms among their patients. However, not all regions of France have enough specialists in forensic dentistry, which can delay the identification of an individual. The problem is even more acute during mass disasters, which require the deployment of several experts in the same place in order to identify the victims. The establishment of a post-mortem odontogram via telemedicine is innovative in that it has never been used in forensic odontology. The collection of post-mortem data could thus be carried out by someone other than the forensic odontology expert and in locations that were previously difficult to access. However, the quality of identification by oral telemedicine is not assured in this context. In the consultation centre [14], the sensitivity of the odontogram carried out by teledentistry was perfectly accurate in 99.9% of patients. The forensic examination differs from the clinical examination in terms of where it takes place, the condition of the deceased person, and the time between death and data collection, which could alter the accuracy of the odontogram via teledentistry.

An odontogram is a set of observations made on the teeth. The quality of an odontogram carried out in teledentistry is therefore based on the quality of each of these observations. The aim of this study is to evaluate the diagnostic validity of the elements constituting the post-mortem odontogram, carried out using images collected via an intra-oral camera in subjects autopsied for medical or judicial reasons.

## 2. Materials and methods

### 2.1. Trial design

This is a transversal observational study for the validation of clinical evaluation tools on deceased subjects from the Forensic Medicine and Thanatology Department at the University Hospital of Montpellier. This study was conducted between 13 May and 12 June 2019. The study protocol was approved by the Ethics Committee in accordance with French standards (Institutional Review Board IRB Montpellier) under the number: 2019\_IRB-MTP\_05-04. The study was conducted in accordance with the Declaration of Helsinki.

### 2.2. Patients

25 deceased over-18-year-olds from the Forensic Medicine and Thanatology Department at the University Hospital of Montpellier were included in the study. The inclusion criteria to constitute our sample were as follows: deceased subjects, aged over 18 years old and autopsied in the Forensic Medicine and Thanatology Department at the University Hospital of Montpellier. There were no non-inclusion criteria. Information concerning the deceased was anonymous. An anonymity number was assigned to each subject.

### 2.3. Study interventions

#### 2.3.1. The different techniques

- Gold Standard technique: The Gold Standard corresponds to a traditional consultation using a mirror and a straight probe.
- Teledentistry: The remote consultation was carried out using a Soprocure camera (Acteon group, Merignac, France). The images were stored on specific teledentistry software and then read by a remote operator.

### 2.4. Protocol

The protocol consisted of 3 stages: the gold standard examination, the recording of videos and the remote analysis of the images obtained (Fig. 1). All the data were recorded in an online research file developed by the University Hospital of Montpellier.

The first dental surgeon (A) performed all the gold standard examinations corresponding to a typical consultation. The data were directly recorded in a clinical file and the procedure time was measured. The second dentist (B) collected data with the intra-oral camera on the software provided. The data were collected at the very beginning of the subjects' autopsies and the acquisition time was recorded. For the Soprocure camera, we used the DAYLIGHT mode, which projects "daylight" light, and we chose the lowest magnification, which provides an excellent visibility of dental surfaces. The camera, which was connected to the computer, allows live images to be viewed and recorded by the operator performing the procedure, making these images an integral part of the post-mortem record. The intra-oral camera passes over the vestibular surfaces of the teeth, then over the occlusal surfaces, and finally over the palatal and lingual surfaces. 4 videos were made per deceased person, one per quadrant.

The software enabled the patient's dental diagram to be established. It was instantaneously sent to the server, so that no data were stored on the computer. The confidentiality of medical information was thus totally preserved. The transfer was done via VPN to an approved health data server.

The last dentist (C) was asynchronously and remotely connected to the secure server through the telemedicine platform and was able

**Table 1**  
Table of results – analysis of sensitivity (Se) and specificity (Sp) for each evaluation criterion.

Parameter	n: denominator	Sensitivity	95% CI	n: denominator	Specificity	95% CI
Tooth missing	292	0.97	0.94	0.99	508	0.99
Residual root	33	0.88	0.72	0.97	767	1.00
Metal crown	26	0.96	0.80	1.00	774	1.00
Ceramic crown	20	0.80	0.56	0.94	780	1.00
Fracture	8	0.88	0.47	1.00	792	1.00
Temporary restoration	1	1.00	0.03	1.00	799	1.00
Rotation / deviation	4	0.50	0.07	0.93	796	1.00
Surfaces with composite	16	0.44	0.20	0.70	3984	1.00
Surfaces with amalgam	9	1.00	0.66	1.00	3991	1.00
Decayed surfaces	16	0.31	0.11	0.59	3984	1.00

to fill in the same clinical file to establish the post-mortem odontogram.

The dentists worked with one another blindly. Practitioners A and C were experienced practitioners, both were associate professors at the University of Montpellier and were working in the Department of First Consultations and Telemedicine in the Department of Odontology at the University Hospital of Montpellier. Practitioner B was a junior practitioner who had received specific training regarding the use of the camera.

## 2.5. Data grid

The data grid was inspired by Interpol DVI 600 PM [15] for the identification of victims and the file used by the Forensic Medicine and Thanatology service during the identification of corpses. This grid made it possible to record:

- Present and absent teeth
- Dental hygiene
- Any clinical particularities visible without XRay (presence of a residual root, metal crown, ceramic crown, prosthesis, tooth fracture, temporary restoration, dental rotation/deviation, conservative treatment (composite resins, amalgams), decayed surfaces)

## 2.6. Study outcomes

The main judgement criterion was the presence of the tooth. The secondary assessment criteria were: the presence of a residual root, metal crown, ceramic crown, prosthesis, tooth fracture, temporary restoration, dental rotation/deviation, conservative care (composite resins, amalgams), decayed surfaces and the time required to allow the learning curve to be estimated.

## 2.7. Statistical analysis

The data collection was carried out on a secure software programme with an anonymity number (attribution of a random number) and then the data were transcribed in an Excel file. The statistical analysis was carried out at the Medical Information Department at the University Hospital of Montpellier using the SAS version 9.2 software programme (SAS Institute, Cary, N.C.) with a significance threshold of 0.05.

For the teeth characteristics, each tooth constituted a statistical unit. The maximum total number of units was therefore 800 (25 patients, 32 teeth). Similarly, for the surface characteristics, the maximum number was 4000. For each endpoint, we calculated the values of sensitivity (Se), specificity (Sp), positive predictive value (PPV) and negative predictive value (NPV) for each of the analysed endpoints. These data are presented with their confidence intervals (Wald's Method).

A learning curve was created by applying smoothing splines to the procedure durations, represented according to the procedure order.

## 3. Results

### 3.1. Patient characteristics

The study was carried out on 25 deceased subjects with an average age of 59.5+/-19.1 years (extrema: 19–87 years), between 13 May and 12 June 2019. Our sample was composed of 68% men and 32% women.

### 3.2. Performance of the remote consultation by patient

#### 3.2.1. Sensitivity and specificity analysis

From Table 1, we can see that we do not have a particularly sensitive or specific result for each judgement criterion analysed. We can see that for almost all the judgement criteria, the specificity value is equivalent to 1, i.e. there are no false positives in the video analysis; if the criterion was detected at a distance, it means that the criterion can only be detected remotely if it is actually present in the mouth at the gold standard examination.

A sensitivity of 0.97 was observed for the performance of the odontogram, i.e., for all the teeth actually present in the mouth for all subjects in the study, 97% of them were identified with the videos taken using teledentistry.

Errors in the establishment of the post-mortem odontogram according to the video analysis mainly concerned tooth surfaces with caries (1/3 of the cases identified) or conservative restorations such as composite resins, for which a lower sensitivity was noted compared to the other assessment criteria analysed (44% of surfaces with composite resin and 31% of decayed surfaces were detected).

### 3.3. Learning curve (Fig. 2)

As the data were collected, practitioner B became more skilled at recording the videos with the intra-oral camera. One can therefore note an ease in the handling of this digital tool, which gradually improved with the number of subjects included in the study, going from an average video duration for each sector of one minute to 35 s. The time needed to film the 4 sectors in the mouth decreased from 4 min 45 s to 2 min 30 s ( Fig. 2).

## 4. Discussion

### 4.1. Statistical bias

Potential selection bias: the need for identification by odontogram was not a criterion for inclusion. Most of the people included were therefore not in this identification context. In an identification context, the passage of the intra-oral camera, or the establishment of

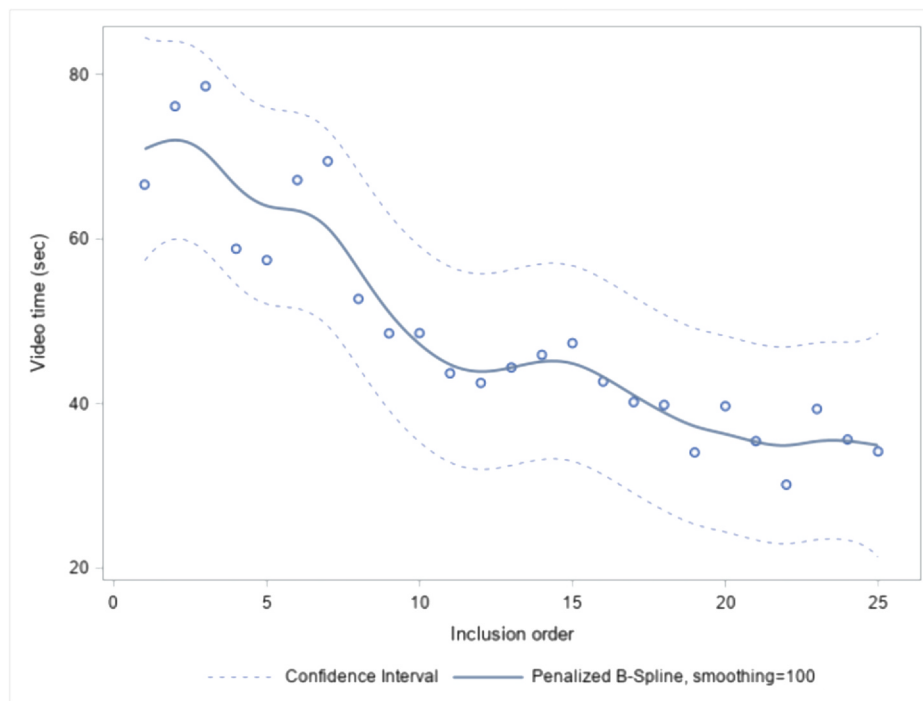


Fig. 2. Learning curve of video recordings using the Soprocare camera.

the odontogram using the images may be more difficult, particularly in a traumatic context.

Classification bias was avoided because all examinations were blind. We can highlight a lack of statistical power with wide confidence intervals. This is due to the small sample size. This study was a pilot study to see if it was feasible. This was confirmed by the first results.

#### 4.2. Sensitivity on the "cavity" factor

The major differences between the two techniques were on carious lesions and teeth treated with composite resin. These differences contradict the study previously conducted by the same team and the same device [14] where the sensitivity was 86.7% on 594 teeth. The difference between the two studies is most certainly due to the absence of fluorescence in the study within the forensic department. The same can be said for the sensitivity of composites. The presence of composite resin on a dental surface is more easily objectifiable with fluorescence. The teledentist's lack of experience practising of deceased patients could also explain the low sensitivity of cavities and composite resins. He usually carried out teleconsultations on elderly patients [8], people with disabilities [9] or inmates [16].

The differences between the two techniques should be viewed in the context whereby two practitioners who are physically present could also have a different interpretation, notably on the presence of tooth enamel demineralization (early tooth decay) or the presence of a composite.

Moreover, during an identification, a cavity is not the most interesting element, since the comparison with the previous dental scheme (practised by the dental surgeon of the deceased) may not reveal the cavity. Indeed, the cavity could have appeared between the last appointment with the dental surgeon and the death of the individual. Cavities and composite resins decrease the accuracy of teledentistry. This study needs to be the first of several, in order to improve the accuracy.

In addition, in the context of identification by odontogram, the concordance of two odontograms is evaluated. Not all differences

have the same weight. For example, in the event of many missing teeth, making the identification of certain remaining teeth could be very unpredictable, an error in the identification of one tooth will be little considered by the practitioner. Our data, which demonstrate that these errors are rare, allow us to assume that the identification of individuals will be little modified. However, this remains to be confirmed in an ad hoc study.

#### 4.3. The learning time

Like any new practice, it takes time to learn how to use the intra-oral camera. Figure 3 shows a learning curve similar to that assessed in the previous comparative study [14]. The recording time is even shorter in this study in the forensic medicine department (4 min (average time) for recording 4 sectors in the forensic medicine department compared to 11 min in the comparative study with 200 living patients). This difference is most certainly due to the 'co-operation' of the deceased. It is important to note that the camera was inserted by a young dental surgeon. He had never used this camera before this study but he was used to examining mouths, and therefore had more cues than an autopsy room attendant who was not used to examining mouths.

#### 4.4. Use of oral teledentistry for post-mortem identification

The number of specialists in odontological identification is not the same in all forensic medicine units in France or in the world and unfortunately it is a very small number. This study shows that identification using teledentistry may offer interesting possibilities for future use, even though some limitations need to be dealt with. This indispensable element in the use of this innovative procedure is not the only parameter for considering the implementation of teledentistry in all forensic medicine units in France and elsewhere. Indeed, it is important to think about implementing this type of system within a unit. Work has been done on this [17,18] but never in the context of a forensic unit. It would be remarkably interesting to be able to assess the capacity to integrate teledentistry into the organisation of a forensic medicine unit.



The use of this innovative procedure in a forensic medicine unit without a dental surgeon could enable them to facilitate identification and, above all, shorten the storage time of bodies in the unit. The dental surgeon would no longer have to travel at the expense of his or her usual activity and could analyse the data on the server from his or her usual place of practice, in between two appointments or when a patient in his or her practice has not honoured his or her appointment. It is important to work on improving the accuracy of the teledentistry technique to ensure the obtention of the same odontogram as in a face-to-face consultation. This study aims to open the possibility of using teledentistry in forensic dentistry and to identify the limitations at that time.

#### 4.5. Limitations of teledentistry for post-mortem odontological identification

As with any innovative practice, getting potential users on board can sometimes be difficult. It is important to position this telemedicine practice as a tool in forensic medicine units. In the event of poor recording by the operator or excessive doubt by the remote expert, a second image capture can be envisaged, or the dental surgeon expert can travel to carry out the identification in the traditional way. Even if we are convinced of the interest of this practice, we believe that in certain very particular cases, telemedicine cannot replace traditional identification. However, it enables a triage - simple cases could be carried out by teledentistry and other cases via a traditional consultation - which could save time for several people in the forensic medicine department and of course, for the dental expert.

## 5. Conclusion

Examination by teledentistry produced encouraging results compared to the clinical examination when analysing the jaws of the deceased patient. This study suggests that teledentistry could be used as a new, non-invasive identification tool in mass disasters, thus saving time in recording post-mortem data because it eliminates the need for the forensic odontology expert's presence at the autopsy site. Furthermore, it offers better working conditions and the obtention of an accurate post-mortem odontogram, allowing the deceased person's integrity to be preserved. However, several aspects still need to be improved, especially accuracy, in order to make the use of the intra-oral camera as easy and efficient as possible. These include training competent personnel in intra-oral imaging, and the transmission of data and information relating to the deceased. Further research, to both improve accuracy and find the best device to enable a consultation that is the same as a face-to-face examination, needs to be carried out. Research to evaluate the implementation of this type of teledentistry programme for dental identification in a forensic medicine unit would be particularly interesting.

### CRedit authorship contribution statement

**Giraudeau N:** Conceptualization, Investigation, Resources, Writing – original draft, Supervision. **Duflos C:** Methodology, Formal

analysis, Writing – review & editing. **Moncayo C:** Investigation, Data curation, Writing – original draft. **Marin G:** Methodology, Formal analysis, Writing – review & editing. **Baccino E:** Conceptualization, Validation, Resources, Writing – review & editing, Supervision. **Martrille L:** Methodology, Validation, Writing – review & editing. **Inquimbert C:** Conceptualization, Investigation, Writing – original draft, Project administration.

### Conflict of interest

Authors declare no conflict of interest.

### References

- [1] J. Friction, H. Chen, Using teledentistry to improve access to dental care for the underserved, *Dent. Clin. North Am.* 53 (3) (2009) 537–548.
- [2] K.V.G. Reddy, Using teledentistry for providing the specialist access to rural Indians, *Indian J. Dent. Res.* 22 (2) (2011) 189.
- [3] S.J. Daniel, S. Kumar, Teledentistry: a key component in access to care, *J. Evid.-Based Dent. Pr.* 14 (Suppl) (2014) 201–208.
- [4] M. Irving, R. Stewart, H. Spallek, A. Blinkhorn, Using teledentistry in clinical practice as an enabler to improve access to clinical care: a qualitative systematic review, *J. Telemed. Telecare* 24 (3) (2018) 129–146.
- [5] A. Tynan, L. Deeth, D. McKenzie, C. Bourke, S. Stenhouse, J. Pitt, et al., Integrated approach to oral health in aged care facilities using oral health practitioners and teledentistry in rural Queensland, *Aust. J. Rural Health* (2018).
- [6] M. Estai, S. Bunt, Y. Kanagasingam, E. Kruger, M. Tennant, Diagnostic accuracy of teledentistry in the detection of dental caries: a systematic review, *J. Evid.-Based Dent. Pr.* 16 (3) (2016) 161–172.
- [7] S.J. Daniel, S. Kumar, Comparison of dental hygienists and dentists: clinical and teledentistry identification of dental caries in children, *Int. J. Dent. Hyg.* 15 (4) (2017) e143–e148.
- [8] N. Giraudeau, J. Valcarcel, H. Tassery, B. Levallois, F. Cuisinier, P. Tramini, F. Vialla, *Projet e-DENT: téléconsultation bucco-dentaire en EHPAD*, *Eur. Res. Telemedicine/La Rech. Eur. En. Téléméd.* 3 (2) (2014) 51–56.
- [9] O. Roy, T. Dodin, S. Vénuat, A. Dagregorio, C. Inquimbert, J. Valcarcel, et al., Oral care in facilities for disabled people: interest of teledentistry, *J. Dent. Oral. Maxillofac. Res.* 5 (4) (2019) 1–4.
- [10] D.T. Kopycka-Kedzierawski, R.J. Billings, Comparative effectiveness study to assess two examination modalities used to detect dental caries in preschool urban children, *Telemed. J. E Health* 19 (11) (2013) 834–840.
- [11] N. Giraudeau, C. Inquimbert, R. Delafoy, P. Tramini, J. Valcarcel, F. Meroueh, Teledentistry, new oral care tool for prisoners, *Int. J. Prison Health* 13 (2) (2017) 124–134.
- [12] B.M. Purohit, A. Singh, A. Dwivedi, Utilization of teledentistry as a tool to screen for dental caries among 12-year-old school children in a rural region of India, *J. Public Health Dent.* 77 (2) (2017) 174–180.
- [13] K.C. Pentapati, P. Mishra, M. Damania, S. Narayanan, G. Sachdeva, G. Bhalla, Reliability of intra-oral camera using teledentistry in screening of oral diseases – pilot study, *Saudi Dent. J.* 29 (2) (2017) 74–77.
- [14] C. Inquimbert, S. Hirata-Tsuchiya, S. Yoshii, N. Molinari, E. Nogue, C. Roy, et al., Concordance study between regular face-to-face dental diagnosis and dental telediagnosis using fluorescence, *J. Telemed. Telecare* (2020) 1357633×19894111.
- [15] Interpol, Post Mortem INTERPOL DVI Form [Internet]. [quoted 15 December 2020]. Available at: (<https://www.interpol.int/How-we-work/Forensics/Disaster-Victim-Identification-DVIR>).
- [16] C. Inquimbert, I. Balacianu, N. Huyghe, J. Padeloup, P. Tramini, F. Meroueh, S. Montal, S. Bencharit, N. Giraudeau, Applications of teledentistry in a French inmate population: a one-year observational study, *PLOS One* 16 (4) (2021) e0247778.
- [17] R. Petcu, C. Kimble, R. Ologeanu-Taddei, I. Bourdon, N. Giraudeau, Assessing patient's perception of oral teleconsultation, *Int. J. Technol. Assess. Health Care* 33 (02) (2017) 147–154.
- [18] Petcu, R., 2020, Multiple stakeholders' analysis of a store-and-forward oral teleconsultation system in France. [Montpellier]: University of Montpellier.