



HAL
open science

Assessment of left ventricular dyssynchrony by speckle tracking echocardiography in children with duchenne muscular dystrophy

Nicolas Lanot, Marie Vincenti, Hamouda Abassi, Charlene Bredy, Audrey Agullo, Lucie Gamon, Thibault Mura, Kathleen Lavastre, Gregoire de La Villeon, Catherine Barrea, et al.

► **To cite this version:**

Nicolas Lanot, Marie Vincenti, Hamouda Abassi, Charlene Bredy, Audrey Agullo, et al.. Assessment of left ventricular dyssynchrony by speckle tracking echocardiography in children with duchenne muscular dystrophy. *International Journal of Cardiovascular Imaging*, 2022, 38 (1), pp.79-89. 10.1007/s10554-021-02369-y . hal-03562536

HAL Id: hal-03562536

<https://hal.umontpellier.fr/hal-03562536>

Submitted on 12 Apr 2023

HAL is a multi-disciplinary open access archive for the deposit and dissemination of scientific research documents, whether they are published or not. The documents may come from teaching and research institutions in France or abroad, or from public or private research centers.

L'archive ouverte pluridisciplinaire **HAL**, est destinée au dépôt et à la diffusion de documents scientifiques de niveau recherche, publiés ou non, émanant des établissements d'enseignement et de recherche français ou étrangers, des laboratoires publics ou privés.

Assessment of Left Ventricular Dyssynchrony by Speckle Tracking Echocardiography in Children with Duchenne Muscular Dystrophy

Nicolas Lanot

Centre Hospitalier Universitaire de Montpellier: Centre Hospitalier Regional Universitaire de Montpellier

Marie Vincenti

Centre Hospitalier Universitaire de Montpellier: Centre Hospitalier Regional Universitaire de Montpellier

Hamouda Abassi

Centre Hospitalier Universitaire de Montpellier: Centre Hospitalier Regional Universitaire de Montpellier

Charlene Bredy

Centre Hospitalier Universitaire de Montpellier: Centre Hospitalier Regional Universitaire de Montpellier

Audrey Agullo

Centre Hospitalier Universitaire de Montpellier: Centre Hospitalier Regional Universitaire de Montpellier

Lucie Gamon

Centre Hospitalier Universitaire de Montpellier: Centre Hospitalier Regional Universitaire de Montpellier

Thibault Mura

Centre Hospitalier Universitaire de Montpellier: Centre Hospitalier Regional Universitaire de Montpellier

Kathleen Lavastre

Centre Hospitalier Universitaire de Montpellier: Centre Hospitalier Regional Universitaire de Montpellier

Gregoire De La Villeon

Centre Hospitalier Universitaire de Montpellier: Centre Hospitalier Regional Universitaire de Montpellier

Catherine Barrea

Cliniques Universitaires Saint-Luc

Pierre Meyer

Centre Hospitalier Universitaire de Montpellier: Centre Hospitalier Regional Universitaire de Montpellier

François Rivier

Centre Hospitalier Universitaire de Montpellier: Centre Hospitalier Regional Universitaire de Montpellier

Albano Melli

Montpellier University: Universite de Montpellier

Jeremy Fauconnier

Université de Montpellier: Universite de Montpellier

Olivier Cazorla

Université de Montpellier: Universite de Montpellier

Alain Lacampagne

Université de Montpellier: Universite de Montpellier



Pascal AMEDRO (✉ p-amedro@chu-montpellier.fr)

Montpellier University Hospital <https://orcid.org/0000-0003-3649-0294>

Keywords: cardiac dyssynchrony, speckle tracking, DMD, heart failure, pediatrics

Posted Date: May 13th, 2021

DOI: <https://doi.org/10.21203/rs.3.rs-510752/v1>

License:   This work is licensed under a Creative Commons Attribution 4.0 International License. [Read Full License](#)

Version of Record: A version of this preprint was published at The International Journal of Cardiovascular Imaging on December 14th, 2021. See the published version at <https://doi.org/10.1007/s10554-021-02369-y>.

Abstract

Purpose Prognosis of Duchenne muscular dystrophy (DMD) is related to cardiac dysfunction. Two dimensional-speckle tracking echocardiography (2D-STE) has recently emerged as a non-invasive functional biomarker for early detection of DMD-related cardiomyopathy. This study aimed to determine, in DMD children, the existence of a left ventricle (LV) dyssynchrony using 2D-STE analysis.

Methods This prospective controlled study enrolled 25 boys with DMD (mean age 11.0 ± 3.5 years) with normal LV ejection fraction and 50 age-matched controls. Three measures were performed to assess LV mechanical dyssynchrony: the opposing-wall delays (longitudinal and radial analyses), the modified Yu index, and the time-to-peak delays of each segment. Feasibility and reproducibility of 2D-STE dyssynchrony were evaluated.

Results All three mechanical dyssynchrony criteria were significantly higher in the DMD group than in healthy subjects: (1) opposing-wall delays in basal inferoseptal to basal anterolateral segments (61.4 ± 45.3 msec vs. 18.3 ± 50.4 msec, $P < 0.001$, respectively) and in mid inferoseptal to mid anterolateral segments (58.6 ± 35.3 msec vs. 42.4 ± 36.4 msec, $P < 0.05$, respectively), (2) modified Yu index (33.3 ± 10.1 msec vs. 28.5 ± 8.1 msec, $P < 0.05$, respectively), and (3) most of time-to-peak values, especially in basal and mid anterolateral segments. Feasibility was excellent and reliability was moderate to excellent, with ICC values ranging from 0.49 to 0.97.

Conclusion Detection of LV mechanical dyssynchrony using 2D-STE analysis is an easily and reproducible method in pediatrics. The existence of an early LV mechanical dyssynchrony visualized using 2D-STE analysis in children with DMD before the onset of cardiomyopathy represents a perspective for future pediatric drug trials in the DMD-related cardiomyopathy prevention.

Clinical Trial Registration Clinicaltrials.gov NCT02418338. Post-hoc study, registered on April 16, 2015.

Introduction

Duchenne muscular dystrophy (DMD) is an X-linked recessive myopathy leading to loss of dystrophin, a constitutive protein of muscle architecture. First symptoms usually appear by the age of 3 and result in loss of independent walking a few years later. Then, progressive symptoms occur, such as respiratory muscle weakness, skeletal deformations or gastro-intestinal disorders [1].

Heart failure due to progressive dilated cardiomyopathy usually occurs at the end of adolescence, and represents the main cause of death in this population [2]. Clinical presentation of DMD-related cardiomyopathy is often misleading, with poor symptomatology, less marked left ventricle (LV) dilatation, and worse prognosis than other etiologies of heart failure [3, 4].

Early identification of DMD-related cardiomyopathy is crucial in order to initiate heart failure medical treatments, improve quality of life, and try to slow down the progression of cardiomyopathy [5]. Cardiac screening is usually based on non-invasive echocardiography standard parameters, such as left ventricle ejection fraction (LVEF) and LV diameter, which are reliable and reproducible measures in pediatrics. However, alteration of those parameters appears at a late stage in DMD-related cardiomyopathy natural history. Modern cardiac imaging tools, such as two-dimensional speckle tracking echocardiography (2D-STE), have shown some interest in terms of feasibility and early assessment of alteration in DMD-related cardiomyopathy [3, 6, 7]. Indeed, from a prospective controlled study, we recently reported the existence of 2D-STE anomalies in children with DMD, before the onset of cardiomyopathy, especially in the longitudinal strain of basal inferolateral and anterolateral segments [6].

In the adult population with cardiomyopathy, such segmental myocardial alterations may be associated with cardiac dyssynchrony, regardless of the LVEF value [8–10]. Basically, cardiac dyssynchrony corresponds to nonsynchronous myocardial contractions, possibly related to three mechanisms: the electrical dyssynchrony, the mechanical dyssynchrony, and the excitation-contraction coupling anomalies [11, 12]. Ultimately, cardiac dyssynchrony may lead to hemodynamic failure [13–15].

To our knowledge, the existence of a cardiac dyssynchrony in children with DMD, before the onset of cardiomyopathy, has not been reported. Yet, in the modern era, pediatric DMD drug trials require reliable and non-invasive cardiac biomarkers. Identifying a pre-symptomatic cardiac biomarker would be of great interest in this population.

Therefore, this study aimed to identify cardiac dyssynchrony in children with DMD, before the onset of cardiomyopathy, in comparison with healthy age-matched control subjects.

Methods

Study design and patients

The patients included in this post-hoc study were screened from our recently published pediatric cohort [6]. We prospectively enrolled 0 to 18-year-old male with DMD and healthy age-matched controls recruited in three pediatric cardiology centers (Montpellier University Hospital, Montpellier, France; Saint-Pierre Institute, Palavas-Les-Flots, France; Cliniques Universitaires St-Luc, UCL University, Brussels, Belgium). Children with DMD were screened during their routine annual follow-up. For the present study, we included only patients with a normal left ventricular systolic function (LVEF \geq 55% by the Simpson biplane method) from the previously reported cohort [6]. In the control group, we included age-matched boys referred to the outpatient pediatric cardiology consultation for minor symptoms (e.g., innocent murmur, chest pain, palpitations, or sports certificate) and with normal physical examination, electrocardiogram, and conventional echocardiography. Children with any chronic disease, or under any treatment, were not included in the control group. Demographic and clinical data were collected in both groups. In the DMD group, cardiac treatment was noted and muscular stage was defined as follows: presymptomatic, early ambulatory, late ambulatory, early non-ambulatory, and late non-ambulatory [16].

Conventional and 2D-strain echocardiography

A single sonographer who traveled to the recruiting sites performed all echocardiographic examinations using the Vivid E9 ultrasound system (General Electric Healthcare, Little Chalfont, United Kingdom) and following the current echocardiographic guidelines [17]. Image acquisition procedures were harmonized using similar setting for each site: global gain, lateral gain, contrast, frame rates of 60 to 80 frames/sec to optimize myocardial deformation analysis, harmonic imaging, image colorizing, and probes adapted to the size and weight of the child (8 or 5 MHz). Three cardiac-cycle loops were systematically recorded in the following views: apical four-, three-, and two-chamber views, and parasternal short-axis view focused on the papillary muscles. Whenever that was not possible, patient was excluded but reported as missing data in feasibility analysis.

Systolic and diastolic LV and right ventricle (RV) standard echocardiography parameters were measured.

Longitudinal LV 2D-strain analyses were performed off-line by a single investigator blinded of patient information, using the EchoPAC software (General Electric, version 203). Longitudinal LV 2D-strain analyses were carried out according to the consensus document of the EACVI/ASE/Industry Task Force [18]. The LV longitudinal and radial global and regional 2D-strain, and strain rate, were automatically calculated by the software after analysis of the 3 longitudinal and the parasternal short-axis views.

Assessment of LV dyssynchrony

- Electrical LV dyssynchrony

From a 12-lead electrocardiogram (ECG), a single operator measured the duration of QRS intervals expressed in milliseconds (msec) on the V5 lead. For each subject, three measures were taken and averaged. To assess electrical dyssynchrony, QRS duration Z-scores were calculated using Chubb et al. formula [19], and we compared Z-scores values between DMD and control groups. Indeed, no evidence-based criteria have been described for electrical dyssynchrony in pediatrics. Based on epidemiological studies, cut-off values for prolonged QRS duration in pediatrics have been previously reported (90 msec in children < 4 years, and 100 msec in 4–16 year-old children) [20]. More recently, Chubb et al. have determined pediatric Z-scores, and defined a cut-off value of 2.1 for prolonged QRS duration [19].

- Mechanical LV dyssynchrony

After performing 2D-strain analyses, the software generates deformation curves for each LV wall segment as a function of time, using a color code for each segment. Two sliders were manually positioned by a single investigator at the beginning of two consecutive QRS complexes, corresponding to the onset of ventricular depolarization, to mark the beginning and the end of the cardiac cycle on the curves graph. Then, the electrosystolic delay, e.g. the « time-to-peak » delay, was recorded. The time-to-peak delay was defined as the time between the beginning of the QRS complex and the systolic strain peak (Fig. 1). The systolic strain peak was defined as the maximum strain value during ventricular systole (occurring before aortic valve closure). The software provided an automatic calculation of time-to-peak delay for each segment, as represented in the shape of a 16-segment bull's eye model [18]. Due to known significant heart rate variability in children [21], all time-to-peak values were corrected using Bazett's formula, as recommended by Thomas et al [22].

To measure LV longitudinal mechanical dyssynchrony, three measures were performed: (1) the opposing-wall delay, corresponding to the delay between the systolic strain peak of two opposite walls, on basal and mid-levels[23, 24]; (2) the modified Yu index, corresponding to the standard-deviation of time-to-peak values in the 12 basal and midwall segments [25], and measured using 2D-STE analysis in this study; and (3) the comparison of time-to-peak delays for each segment between DMD and control groups [26].

To assess LV radial dyssynchrony, we measured the anteroseptal-posterior opposing-wall delay, corresponding to the delay between the systolic strain peak of the mid posterior and the anteroseptal segments in parasternal short axis view [27–30]. This parameter was manually calculated by the same investigator: the systolic strain peak was identified on the curves graph, then the software automatically calculated the respective time-to-peak delay, and finally we deduced the anteroseptal-posterior opposing-wall delay.

Feasibility and reproducibility analysis

Patients with a poor acoustic window or a poor-quality ECG pattern (illegible or containing less than one complete cardiac cycle) were excluded from dyssynchrony analysis and collected as feasibility data.

To assess interobserver and intraobserver reproducibility, a second analysis of time-to-peak delays in the 16 LV segments was performed by the same investigator and by a second investigator (AA), with no access to the results of first analysis, on a subset of 20 patients randomly selected from the two groups.

Statistical analysis

Each child with DMD was matched with 2 control subjects according to four age groups (0–4 years, 5–8 years, 9–12 years, and 13–17 years). The characteristics of the children enrolled in the study were described with proportions for categorical variables and with means and standard deviation values for continuous variables. The comparisons of

echocardiographic parameters (conventional, 2D-strain and dyssynchrony analyses) between children with DMD and control subjects were performed using linear mixed models. These models included a random intercept specific to matched triads. DMD and age were entered as fixed effects in models.

In accordance with recommendations published in Shrout and Fleiss [31], we evaluated the reproducibility of the performed measurements by calculating intraclass correlation coefficients (ICC) of type (2,1) for interobserver and intraobserver reliability, as only one investigator was responsible for the double analysis to assess intraobserver reliability, and a single pair of investigators produced the two analyses to assess interobserver reliability. As defined by Koo et al., ICC values less than 0.5, between 0.5 and 0.75, between 0.75 and 0.9, and greater than 0.90 were indicative of poor, moderate, good, and excellent reliability, respectively [32]. Analyses were performed using SAS version 9 (SAS Institute, Cary, NC, USA). The statistical significance was set at 0.05.

Results

Population

A total of 75 children were enrolled in the study, including 25 patients with DMD (mean age, 11.0 ± 3.5 years) and 50 age-matched healthy male controls (mean age, 10.0 ± 3.3 years). The heart rate was significantly higher in the DMD group than in healthy subjects (95 ± 13 bpm vs. 74 ± 12 bpm, $P < 0.01$, respectively). Cardiovascular symptoms were reported in only one child with DMD (exercise-induced dyspnea). The main muscular stage was “early non-ambulatory”. Combination therapy with corticosteroids and angiotensin converting enzyme (ACE) inhibitors was the most common drug treatment. Demographic and clinical data are summarized in Table 1.

Table 1
Population characteristics

Clinical parameters		DMD group (N = 25)	Control group (N = 50)	P-value
Age (year)		11.0 ± 3.5	10.0 ± 3.25	NA
Weight (kg)		37.7 ± 15.3	37.5 ± 15.5	0.14
Height (cm)		136.5 ± 16.0	143.1 ± 19.6	< 0.001
BMI (kg/m ²)		19.1 ± 5.6	17.5 ± 3.0	0.14
Systolic blood pressure (mmHg)		107.8 ± 10.1	107.1 ± 13.2	0.75
Diastolic blood pressure (mmHg)		61.6 ± 7.9	56.1 ± 8.0	0.01
Heart rate (bpm)		95.4 ± 12.9	73.8 ± 11.7	< 0.001
Muscular stage	Pre-symptomatic	3 (12%)	-	-
	Early ambulatory	5 (20%)	-	-
	Late ambulatory	3 (12%)	-	-
	Early non-ambulatory	13 (52%)	-	-
	Late non-ambulatory	1 (4%)	-	-
Cardiac treatment	None	2 (8%)	-	-
	Corticosteroids	2 (8%)	-	-
	ACE inhibitors	5 (20%)	-	-
	Corticosteroids + ACE inhibitors	14 (56%)	-	-
	Others	2 (8%)	-	-
Cardiovascular symptoms		1 (4%)	-	-
Legend: BMI, body mass index; ACE, angiotensin conversion enzyme; NA, non applicable (age-matched controls). Results are presented in mean ± standard deviation (SD) or N (%).				

Conventional and 2D-strain echocardiography variables

Mean LVEF was normal and similar between groups (63% ± 5% in the DMD group vs. 64% ± 5% in the control group, $P = 0.8$). No significant LV dilatation was observed in the DMD group. RV conventional variables were normal and similar between the two groups. Conventional echocardiography variables are reported in Table 2.

Table 2
Conventional echocardiography variables

Conventional echocardiography variables		DMD group (N = 25)	Controls (N = 50)	Adjusted difference between groups*		
		Mean ± SD	Mean ± SD	Coefficient	[95% CI]	P-value
Left ventricle	LVEF (%)	63.5 ± 5.1	63.8 ± 5.0	-0.25	[-2.5; 2.0]	0.8
	LVIDd (mm)	39.3 ± 4.2	42.3 ± 4.2	-3.83	[-5.5; -2.1]	< 0.001
	E/A ratio	1.8 ± 0.4	2.2 ± 0.6	-0.39	[-0.7; -0.1]	0.01
	E deceleration time (msec)	144.4 ± 25.7	175.8 ± 37.0	-35.02	[-52.5; -17.6]	< 0.001
	E/E'	5.8 ± 1.9	5.7 ± 1.1	0.15	[-0.5; 0.8]	0.7
	Wall stress (g/cm ²)	49.9 ± 14.9	42.7 ± 10.8	7.69	[1.2; 14.2]	0.02
	VCFc (s ⁻¹)	1.4 ± 0.4	1.3 ± 0.2	0.15	[0.0; 0.3]	0.03
Right ventricle	TAPSE (mm)	19.5 ± 2.5	20.8 ± 3.4	-1.42	[-2.9; 0.1]	0.06
	S wave (TDI) (cm/s)	13.0 ± 2.4	12.9 ± 1.9	0.08	[-0.9; 1.1]	0.9
	TEI index (TDI)	0.4 ± 0.1	0.4 ± 0.1	-0.02	[-0.1; 0.1]	0.6
	IVC %	62.3 ± 19.4	69.3 ± 17.1	-7.05	[-16.9; 2.8]	0.2
Legend: LVEF, left ventricle ejection fraction (Simpson biplane); LVIDd, left ventricle internal diastolic diameter; TDI, tissue Doppler imaging; VCFc, contraction velocity corrected by cardiac frequency; TAPSE, tricuspid annular plane systolic excursion; TEI, myocardial performance index; IVC %, inferior vena cava collapse index.						
*Difference between groups adjusted for age.						

Global LV 2D-strain values were significantly lower in the DMD group than in the control group, for both longitudinal analysis (-16.8% ± 3.9% vs. -20.6% ± 2.6%, $P < 0.0001$, respectively) and radial analysis (22.7% ± 11.3% vs. 31.7% ± 14.0%, $P < 0.002$, respectively). Regional 2D-strain values were significantly lower in the DMD group for LV inferolateral, anterolateral, anterior and inferior regions, with a greatest difference for the inferior and anterolateral segments. No differences were observed in terms of strain rate (for both longitudinal and radial analyses) and regional 2D-strain for LV basal anteroseptal, inferoseptal and apical anterior segments. Global and regional LV 2D-strain and strain rate analyses are reported in supplementary Table S1 (longitudinal strain) and supplementary Table S2 (radial strain).

Left ventricular dyssynchrony analysis

- Electrical LV dyssynchrony

No QRS widening was observed in the DMD group. Mean QRS complex measures were not significantly different between DMD and control groups (83 ± 10 msec vs. 85 ± 11 msec, $P = 0.07$, respectively). Z-scores of QRS width were normal and similar between the two groups (-0.2 ± 0.8 vs. 0.2 ± 0.9, $P = 0.08$, respectively).

- Mechanical LV dyssynchrony

The basal inferoseptal to basal anterolateral opposing-wall delay was significantly higher in the DMD group than in healthy subjects (61.4 ± 45.3 msec vs. 18.3 ± 50.4 msec, $P < 0.001$, respectively). Similarly, the mid inferoseptal to mid anterolateral opposing-wall delay was significantly higher in the DMD group than in healthy controls (58.6 ± 35.3 msec vs. 42.4 ± 36.4 msec, $P < 0.05$, respectively). There was a trend for a higher difference between the basal anteroseptal and basal inferolateral segments in the DMD group than in healthy controls (-47.6 ± -63.8 msec vs. -30.2 ± -41.1 msec, $P = 0.11$, respectively). No other difference was observed in the longitudinal analysis, as well as in the radial analysis.

The modified Yu index was significantly higher in the DMD group than in healthy subjects (33.3 ± 10.1 msec vs. 28.5 ± 8.1 msec, $P < 0.05$, respectively).

Time-to-peak delays in the DMD group were significantly increased in basal and mid anterior and anterolateral segments, as well as in the apical lateral segment (Fig. 2, Table 3).

Table 3
Opposing-wall delays in longitudinal and radial 2D-strain analyses

			DMD group		Controls		Adjusted difference between groups*		
			N	Mean ± SD	N	Mean ± SD	Coefficient	[95% CI]	P- value
LV longitudinal opposing-wall delay	Basal segments ¹	4-chamber view	25	61.4 ± 45.3	50	18.3 ± 50.4	46.8	[23.1; 70.5]	< 0.001
		3-chamber view	25	-47.6 ± 63.8	50	-30.2 ± 41.1	-19.7	[-44.3; 4.8]	0.11
		2-chamber view	25	9.9 ± 50.6	50	5.2 ± 45.4	0.2	[-0.5; 0.9]	0.64
	Mid segments ²	4-chamber view	25	58.6 ± 35.3	50	42.4 ± 36.4	18.0	[0.2; 35.8]	< 0.05
		3-chamber view	25	-20.4 ± 51.7	50	-12.6 ± 40.1	-9.5	[-31.1; 12.1]	0.38
		2-chamber view	25	18.1 ± 45.6	50	14.3 ± 38.3	2.4	[-17.9; 22.8]	0.81
LV radial mechanical opposing-wall delay		23	-17.3 ± 29.3	49	-24.2 ± 33.5	8.2	[-8.6; 25.1]	0.33	
Legend: LV, left ventricle.									
*Difference between groups adjusted for age; corrected by heart rate (using Bazett's formula); significant <i>p-values</i> are marked in bold.									
1LV mechanical dyssynchrony was assessed as the difference between the time-to-peak value of the basal inferoseptal and the basal anterolateral segments (4-chambers view), between the basal inferolateral and the basal anteroseptal segments (3-chamber view), and between the basal inferior and the basal anterior segments (2-chamber view).									
2LV mechanical dyssynchrony was assessed as the difference between the time-to-peak value of the mid inferoseptal and the mid anterolateral segments (4-chamber view), between the mid inferolateral and the mid anteroseptal segments (3-chamber view), and between the mid inferior and the basal anterior segments (2-chamber view).									

Feasibility and reproducibility analysis

From our previously reported database [6], 30 children with DMD and 72 healthy control subjects were eligible for the study. The proportion of patients excluded from dyssynchrony analysis was similar in the two groups (5 out of 30 patients, *i.e.* 16.7% in the DMD group, and 13 out of 72 patients, *i.e.* 18.0% in the control group). In the DMD group, one subject (3.3%) was excluded due to poor acoustic window, making LV dyssynchrony analysis impossible, and four subjects (13.3%) had a poor-quality ECG pattern. In two patients (6.7%), 2D-strain analysis was only possible in apical views.

In the control group, one subject (1.4%) was excluded from analysis due to poor acoustic window, making LV dyssynchrony analysis impossible, and 12 subjects (16.7%) had a poor-quality ECG pattern. In one patient (3.4%), 2D-strain analysis was only possible in apical views. Therefore, LV dyssynchrony analysis was feasible in a total of 59 healthy subjects. As 25 children with DMD were enrolled in the study, 50 age-matched healthy subjects were selected in order to respect the 1:2 case-control study design.

Intra-observer and inter-observer reliability analyses of time-to-peak delays in the 16 LV segments were reported in Table 4. We found moderate to excellent levels of reliability with ICC values ranging from 0.60 to 0.97 for intraobserver variability and from 0.49 to 0.94 for interobserver variability.

Table 4
Intra- and interobserver variability of time-to-peak delays

LV segments	Intraobserver variability (N = 20)		Interobserver variability (N = 20)	
	ICC	[95% CI]	ICC	[95% CI]
Basal anterior	0.78	[0.53; 0.91]	0.81	[0.58; 0.92]
Basal anteroseptal	0.82	[0.62; 0.93]	0.85	[0.99; 0.94]
Basal inferoseptal	0.89	[0.74; 0.95]	0.77	[0.51; 0.90]
Basal inferior	0.60	[0.24; 0.82]	0.49	[0.08; 0.76]
Basal inferolateral	0.89	[0.75; 0.96]	0.74	[0.44; 0.89]
Basal anterolateral	0.91	[0.79; 0.96]	0.73	[0.44; 0.88]
Mid anterior	0.62	[0.27; 0.83]	0.72	[0.42; 0.88]
Mid anteroseptal	0.74	[0.45; 0.88]	0.72	[0.42; 0.88]
Mid inferoseptal	0.91	[0.79; 0.96]	0.84	[0.65; 0.93]
Mid inferior	0.87	[0.71; 0.95]	0.71	[0.41; 0.87]
Mid inferolateral	0.91	[0.78; 0.94]	0.66	[0.32; 0.85]
Mid anterolateral	0.96	[0.88; 0.98]	0.92	[0.81; 0.96]
Apical anterior	0.85	[0.67; 0.94]	0.94	[0.86; 0.98]
Apical septal	0.97	[0.94; 0.99]	0.94	[0.85; 0.98]
Apical inferior	0.96	[0.90; 0.98]	0.79	[0.52; 0.91]
Apical lateral	0.94	[0.86; 0.98]	0.87	[0.69; 0.94]
Legend: CI, confidence interval; ICC, intraclass correlation coefficient.				

Discussion

This prospective controlled study reported, for the first time, the existence of a left ventricular regionalized mechanical dyssynchrony in children with DMD with a normal LV systolic function. Indeed, using 2D-STE analysis, all three mechanical dyssynchrony criteria evaluated in this study were significantly higher in the DMD group than in healthy matched subjects: (1) basal inferoseptal to basal anterolateral opposing-wall delay and mid inferoseptal to mid

anterolateral opposing-wall delay, (2) modified Yu index, and (3) most of time-to-peak delays, especially in basal and mid anterolateral segments.

Interestingly, this study found a segmental LV mechanical dyssynchrony before the onset of DMD-related cardiomyopathy or any clinical symptoms, as no patient with LV systolic dysfunction or LV dilatation was enrolled. LV mechanical dyssynchrony was more pronounced in the basal and mid anterolateral segments, which is concordant with LV 2D-strain anomalies previously observed in similar segments [6, 7].

Indeed, selective damage in those segments may be related to regional myocardial scar, which has been found to be higher in lateral than in septal segments, even with a preserved LV systolic function. Hor et al. have previously reported that LV mechanical dyssynchrony in DMD with end-stage cardiac dysfunction was associated with extensive infero- and anterolateral fibrosis [33]. Using cardiac magnetic resonance imaging, Bilchick et al. have also shown that myocardial scar affected the LV anterolateral segment eight times more than the septal wall, regardless of LV systolic function [34]. Furthermore, analyses on anatomopathology, electrocardiograms, and vectorcardiograms in DMD patients have suggested that fibrosis would start from the epimyocardial portion of the LV lateral wall, then reach the septal wall, and finally extend to the entire thickness of the myocardial wall [35]. DMD-related fibrosis has been associated with myocardial stiffness, reduced myocyte compliance and increased susceptibility to stretch-mediated calcium overload, inducing cell necrosis [36]. Moreover, LV mechanical dyssynchrony could modify myocardial gene expression and aggravate heart failure, as described in mouse models of cardiac remodeling [37]. However, the reason why fibrosis first involves this specific ventricular region remains unknown.

In this pediatric cohort, 2D-STE dyssynchrony analyses have shown good feasibility and reproducibility, as previously reported in children without any cardiac disease [38]. Indeed, in our study, analyses were technically possible in more than 80% of children in both DMD and healthy subjects, which is in line with the STAR study in adult heart failure [23]. Overall, reproducibility was good to excellent, especially in segments where mechanical LV dyssynchrony was observed.

Other ultrasound methods have been used to measure mechanical LV dyssynchrony [39]. However, M-mode and tissue Doppler imaging (TDI) do not provide simultaneous sampling in multiple segments. Color-coded tissue Doppler, tissue synchronization imaging and 3D-echocardiography provide simultaneous sampling of multiple segments, but require high-end ultrasound equipment and are difficult to use in current practice [40]. 2D-STE analysis is little affected by translational and tethering motions [41, 42], and is not angle dependent. Moreover, 2D-STE semi-automated processing improves reproducibility and provides a global assessment of LV wall deformations, with easier use than other methods [40].

In this study, no electrical dyssynchrony was observed in children with DMD. Indeed, QRS intervals were similar between DMD and healthy subjects, using both raw values and pediatric Z-scores. This result is in line with the study from Hor et al., using cardiac magnetic resonance imaging in children with DMD and finding that the existence of a LV mechanical dyssynchrony did not involve electrical dyssynchrony in the DMD population [33]. Therefore, measuring QRS intervals remains insufficient for assessing cardiac damage in patients with DMD.

Currently, cardiomyopathy prevention represents one of the most challenging clinical research issues in children with DMD [43]. Conventional echocardiography parameters have failed to determine drugs' efficacy (angiotensin-converting enzyme inhibitors, β -blockers, corticosteroids) on DMD cardiomyopathy onset and progression rate [5, 44–47]. Moreover, available tools to evaluate cardiac function may not be very specific (biological blood tests), difficult to perform in pediatric patients (cardiac magnetic resonance imaging), or too invasive (myocardial biopsy). Therefore, using mechanical dyssynchrony as a novel non-invasive cardiac biomarker in current (phosphodiesterase-5 inhibitors, COX-inhibiting nitric oxide donors, poloxamer 188) or future pediatric DMD drug trials would be of great interest.

The results of this study evidently question the interest of cardiac resynchronization therapy (CRT) in the DMD population. In adult symptomatic heart failure with impaired systolic LV function and LV mechanical dyssynchrony, CRT may improve symptoms and LV reverse remodeling, regardless of QRS width [48, 49]. However, in adult ischemic heart disease, the existence of inferior fibrosis reaching more than 50% wall thickness is associated with a nonresponse to CRT [50]. LV pacing may reduce the progression of DMD-related cardiomyopathy, by decreasing ventricular work at each heartbeat, and therefore reducing damage to the myocyte membrane [34, 36]. By analogy, we may hypothesize that CRT could prevent LV mechanical dyssynchrony at an early stage of the cardiomyopathy, inducing a clinical benefit for the patient. Nevertheless, more evidence is necessary to support that CRT is useful in the DMD population free from heart failure.

Study limitations

The original study was not designed to use mechanical dyssynchrony as a primary outcome [6]. As a result, the population from this post-hoc study included a small number of patients and controls. No subgroup analyses could be performed, however all three mechanical dyssynchrony criteria reached statistical significance.

No cut-off values to define LV electrical or mechanical dyssynchrony have been established in the pediatric population. As a result, we used a case-control study design to compare DMD patients to age-matched healthy subjects. Further studies are needed to define LV dyssynchrony thresholds in pediatrics.

The cross-sectional design of this study limits the use of LV mechanical dyssynchrony as a prognostic marker of LV dysfunction. Indeed, further longitudinal cohort studies will need to determine whether LV mechanical dyssynchrony can be used as a surrogate outcome for heart failure in the DMD population.

Conclusion

LV mechanical dyssynchrony involving the basal and mid anterolateral segments seemed to affect children with DMD before the onset of relevant patterns of cardiomyopathy. Detection of LV mechanical dyssynchrony using the 2D-STE analysis is an easily and reproducible method, which may be of interest in clinical practice.

The existence of 2D-STE mechanical dyssynchrony despite normal LV size and function represents an important perspective for future pediatric drug trials in DMD-related cardiomyopathy prevention. Further prospective studies will be necessary to confirm that cardiac dyssynchrony parameters may be used as reliable surrogate outcomes for heart failure in patients with DMD.

Abbreviations

2D-strain

two-dimensional strain

2D-STE

two-dimensional speckle tracking echocardiography

ACE

angiotensin converting enzyme.

CRT

cardiac resynchronization therapy

DMD

Duchenne muscular dystrophy

ECG

electrocardiogram
ICC
intraclass correlation coefficient
LV
left ventricle
LVEF
left ventricle ejection fraction (biplane Simpson)
LVIDd
left ventricle internal diastolic diameter
RV
right ventricle
TDI
tissue Doppler imaging
VCF_c
contraction velocity corrected by cardiac frequency

Declarations

Funding

This work was supported by grants from Montpellier University Hospital Clinical Research Institutional Grant [PHRC-MERRI UF 9458] and from the French National Muscular Dystrophy Association [AFM 20225].

Conflicts of Interest

The authors declare that they have no conflict of interest.

Availability of data and material

The data that support the findings of this study are available from the corresponding author, upon reasonable request.

Code availability

Not applicable.

Author's contributions

Pascal Amedro and Alain Lacampagne conceived and designed the study. Pascal Amedro, Jeremy Fauconnier, Olivier Cazorla and Alain Lacampagne obtained funding. Pascal Amedro supervised this work. Nicolas Lanot and Marie Vincenti performed image acquisition and analysis. Lucie Gamon and Thibault Mura performed the statistical analysis. Pascal Amedro, Nicolas Lanot, Marie Vincenti, Hamouda Abassi, Gregoire De La Villeon, Kathleen Lavastre, Albano C. Meli, Olivier Cazorla, Jeremy Fauconnier, and Alain Lacampagne drafted the manuscript. All authors discussed the results and contributed to the final revision of the manuscript.

Ethics approval

The study was conducted in compliance with the Good Clinical Practices protocol and Declaration of Helsinki principles. The South Mediterranean IV Ethics Committee (2014-A01764-44) in France and the UCL Ethics Committee (2016-28AVR-192) in Belgium approved the study.

Consent to participate

Informed consent was obtained from all parents or legal guardians.

Consent for publication

Informed consent was obtained from all parents or legal guardians. Only anonymized data has been published.

Acknowledgments

We thank all our patients and their families for their participation in the study, and Anne Cadene for the quality of study monitoring.

Sources of funding

This work was supported by grants from Montpellier University Hospital Clinical Research Institutional Grant [PHRC-MERRI UF 9458] and from the French National Muscular Dystrophy Association [AFM 20225].

Ethical standards

The study was conducted in compliance with the Good Clinical Practices protocol and Declaration of Helsinki principles. The South Mediterranean IV Ethics Committee (2014-A01764-44) in France and the UCL Ethics Committee (2016-28AVR-192) in Belgium approved the study, which was registered on ClinicalTrials.gov (NCT02418338). Informed consent was obtained from all parents or legal guardians.

References

1. Guiraud S, Aartsma-Rus A, Vieira NM, Davies KE, van Ommen G-JB, Kunkel LM. The Pathogenesis and Therapy of Muscular Dystrophies. *Annu Rev Genomics Hum Genet.* 2015;16:281–308. <https://doi.org/10.1146/annurev-genom-090314-025003>
2. Kamdar F, Garry DJ. Dystrophin-Deficient Cardiomyopathy. *J Am Coll Cardiol.* 2016;67:2533–46. <https://doi.org/10.1016/j.jacc.2016.02.081>
3. Spurney CF, McCaffrey FM, Cnaan A, Morgenroth LP, Ghelani SJ, Gordish-Dressman H, et al. Feasibility and Reproducibility of Echocardiographic Measures in Children with Muscular Dystrophies. *J Am Soc Echocardiogr Off Publ Am Soc Echocardiogr.* 2015;28:999–1008. <https://doi.org/10.1016/j.echo.2015.03.003>
4. Connuck DM, Sleeper LA, Colan SD, Cox GF, Towbin JA, Lowe AM, et al. Characteristics and outcomes of cardiomyopathy in children with Duchenne or Becker muscular dystrophy: a comparative study from the Pediatric Cardiomyopathy Registry. *Am Heart J.* 2008;155:998–1005. <https://doi.org/10.1016/j.ahj.2008.01.018>
5. Duboc D, Meune C, Lerebours G, Devaux J-Y, Vaksman G, Bécane H-M. Effect of perindopril on the onset and progression of left ventricular dysfunction in Duchenne muscular dystrophy. *J Am Coll Cardiol.* 2005;45:855–7. <https://doi.org/10.1016/j.echo.2018.10.017>
6. Amedro P, Vincenti M, De La Villeon G, Lavastre K, Barrea C, Guillaumont S, et al. Speckle-Tracking Echocardiography in Children With Duchenne Muscular Dystrophy: A Prospective Multicenter Controlled Cross-Sectional Study. *J Am Soc Echocardiogr Off Publ Am Soc Echocardiogr.* 2019;32:412–22. <https://doi.org/10.1016/j.echo.2018.10.017>
7. Mertens L, Ganame J, Claus P, Goemans N, Thijs D, Eyskens B, et al. Early regional myocardial dysfunction in young patients with Duchenne muscular dystrophy. *J Am Soc Echocardiogr Off Publ Am Soc Echocardiogr.* 2008;21:1049–54. <https://doi.org/10.3233/jnd-160194>

8. Chang S-A, Kim H-K, Kim D-H, Kim Y-J, Sohn D-W, Oh B-H, et al. Left ventricular systolic and diastolic dyssynchrony in asymptomatic hypertensive patients. *J Am Soc Echocardiogr Off Publ Am Soc Echocardiogr*. 2009;22:337–42. <https://doi.org/10.1016/j.echo.2009.01.024>
9. Wang J, Kurrelmeyer KM, Torre-Amione G, Nagueh SF. Systolic and diastolic dyssynchrony in patients with diastolic heart failure and the effect of medical therapy. *J Am Coll Cardiol*. 2007;49:88–96. <https://doi.org/10.1016/j.jacc.2006.10.023>
10. Edvardsen T, Helle-Valle T, Smiseth OA. Systolic Dysfunction in Heart Failure with Normal Ejection Fraction: Speckle-Tracking Echocardiography. *Prog Cardiovasc Dis*. 2006;49:207–14. <https://doi.org/10.1016/j.pcad.2006.08.008>
11. Yu CM, Bax JJ, Monaghan M, Nihoyannopoulos P. Echocardiographic evaluation of cardiac dyssynchrony for predicting a favourable response to cardiac resynchronisation therapy. *Heart*. BMJ Publishing Group Ltd; 2004;90:vi17–22. <https://doi.org/10.1136/hrt.2004.048322>
12. Vardas PE, Auricchio A, Blanc J-J, Daubert J-C, Drexler H, Ector H, et al. Guidelines for cardiac pacing and cardiac resynchronization therapy: The Task Force for Cardiac Pacing and Cardiac Resynchronization Therapy of the European Society of Cardiology. Developed in collaboration with the European Heart Rhythm Association. *Eur Heart J*. 2007;28:2256–95. <https://doi.org/10.1093/eurheartj/ehm305>
13. Littmann L, Symanski JD. Hemodynamic implications of left bundle branch block. *J Electrocardiol*. 2000;33:115–21. <https://doi.org/10.1054/jelc.2000.20330>
14. Saxon LA, Kerwin WF, Cahalan MK, Kalman JM, Olgin JE, Foster E, et al. Acute effects of intraoperative multisite ventricular pacing on left ventricular function and activation/contraction sequence in patients with depressed ventricular function. *J Cardiovasc Electrophysiol*. 1998;9:13–21. <https://doi.org/10.1111/j.1540-8167.1998.tb00862.x>
15. Kerwin WF, Botvinick EH, O’Connell JW, Merrick SH, DeMarco T, Chatterjee K, et al. Ventricular contraction abnormalities in dilated cardiomyopathy: effect of biventricular pacing to correct interventricular dyssynchrony. *J Am Coll Cardiol*. 2000;35:1221–7. [https://doi.org/10.1016/s0735-1097\(00\)00555-6](https://doi.org/10.1016/s0735-1097(00)00555-6)
16. Birnkrant DJ, Bushby K, Bann CM, Apkon SD, Blackwell A, Brumbaugh D, et al. Diagnosis and management of Duchenne muscular dystrophy, part 1: diagnosis, and neuromuscular, rehabilitation, endocrine, and gastrointestinal and nutritional management. *Lancet Neurol*. 2018;17:251–67. [https://doi.org/10.1016/s1474-4422\(18\)30024-3](https://doi.org/10.1016/s1474-4422(18)30024-3)
17. Lopez L, Colan SD, Frommelt PC, Ensing GJ, Kendall K, Younoszai AK, et al. Recommendations for quantification methods during the performance of a pediatric echocardiogram: a report from the Pediatric Measurements Writing Group of the American Society of Echocardiography Pediatric and Congenital Heart Disease Council. *J Am Soc Echocardiogr Off Publ Am Soc Echocardiogr*. 2010;23:465–95; quiz 576–7. <https://doi.org/10.1016/j.echo.2010.03.019>
18. Voigt J-U, Pedrizzetti G, Lysyansky P, Marwick TH, Houle H, Baumann R, et al. Definitions for a common standard for 2D speckle tracking echocardiography: consensus document of the EACVI/ASE/Industry Task Force to standardize deformation imaging. *J Am Soc Echocardiogr Off Publ Am Soc Echocardiogr*. 2015;28:183–93. <https://doi.org/10.1093/ehjci/jeu184>
19. Chubb H, Ceresnak SR, Motonaga KS, Dubin AM. A proposed method for the calculation of age-dependent QRS duration z-scores. *J Electrocardiol*. 2020;58:132–4. <https://doi.org/10.1016/j.jelectrocard.2019.12.004>
20. Surawicz Borys, Childers Rory, Deal Barbara J., Gettes Leonard S. AHA/ACCF/HRS Recommendations for the Standardization and Interpretation of the Electrocardiogram. *Circulation*. American Heart Association; 2009;119:e235–40. <https://doi.org/10.1016/j.jacc.2008.12.013>
21. Thomas TO, Jefferies JL, Lorts A, Anderson JB, Gao Z, Benson DW, et al. Autonomic Dysfunction: A Driving Force for Myocardial Fibrosis in Young Duchenne Muscular Dystrophy Patients? *Pediatr Cardiol*. 2015;36:561–8. <https://doi.org/10.1007/s00246-014-1050-z>

22. Thomas VC, Cumbermack KM, Lamphier CK, Phillips CR, Fyfe DA, Fornwalt BK. Measures of dyssynchrony in the left ventricle of healthy children and young patients with dilated cardiomyopathy. *J Am Soc Echocardiogr Off Publ Am Soc Echocardiogr*. 2013;26:142–53. <https://dx.doi.org/10.1016%2Fj.echo.2012.10.014>
23. Tanaka H, Nesser H-J, Buck T, Oyenuga O, Jánosi RA, Winter S, et al. Dyssynchrony by speckle-tracking echocardiography and response to cardiac resynchronization therapy: results of the Speckle Tracking and Resynchronization (STAR) study. *Eur Heart J*. 2010;31:1690–700. <https://doi.org/10.1093/eurheartj/ehq213>
24. Risum N, Jons C, Olsen NT, Fritz-Hansen T, Bruun NE, Hojgaard MV, et al. Simple regional strain pattern analysis to predict response to cardiac resynchronization therapy: rationale, initial results, and advantages. *Am Heart J*. 2012;163:697–704. <https://doi.org/10.1016/j.ahj.2012.01.025>
25. Yu C-M, Chau E, Sanderson JE, Fan K, Tang M-O, Fung W-H, et al. Tissue Doppler echocardiographic evidence of reverse remodeling and improved synchronicity by simultaneously delaying regional contraction after biventricular pacing therapy in heart failure. *Circulation*. 2002;105:438–45. <https://doi.org/10.1161/hc0402.102623>
26. Bharucha T, Khan R, Mertens L, Friedberg MK. Right Ventricular Mechanical Dyssynchrony and Asymmetric Contraction in Hypoplastic Heart Syndrome are Associated with Tricuspid Regurgitation. *J Am Soc Echocardiogr*. 2013;26:1214–20. <https://doi.org/10.1016/j.echo.2013.06.015>
27. Zhang X, Ha S, Wang X, Shi Y, Duan S, Li Z. Speckle tracking echocardiography: clinical applications in cardiac resynchronization therapy. *Int J Clin Exp Med*. 2015;8:6668–76.
28. Suffoletto MS, Dohi K, Cannesson M, Saba S, Gorcsan J. Novel speckle-tracking radial strain from routine black-and-white echocardiographic images to quantify dyssynchrony and predict response to cardiac resynchronization therapy. *Circulation*. 2006;113:960–8. <https://doi.org/10.1161/circulationaha.105.571455>
29. Gorcsan J, Oyenuga O, Habib PJ, Tanaka H, Adelstein EC, Hara H, et al. The Relationship of Echocardiographic Dyssynchrony to Long-Term Survival Following Cardiac Resynchronization Therapy. *Circulation*. 2010;122:1910–8. <https://dx.doi.org/10.1161%2FCIRCULATIONAHA.110.954768>
30. Gorcsan J, Tanabe M, Bleeker GB, Suffoletto MS, Thomas NC, Saba S, et al. Combined longitudinal and radial dyssynchrony predicts ventricular response after resynchronization therapy. *J Am Coll Cardiol*. 2007;50:1476–83. <https://doi.org/10.1016/j.jacc.2007.06.043>
31. Shrout PE, Fleiss JL. Intraclass correlations: uses in assessing rater reliability. *Psychol Bull*. 1979;86:420–8.
32. Koo TK, Li MY. A Guideline of Selecting and Reporting Intraclass Correlation Coefficients for Reliability Research. *J Chiropr Med*. 2016;15:155–63. <https://dx.doi.org/10.1016%2Fj.jcm.2016.02.012>
33. Hor KN, Wansapura JP, Al-Khalidi HR, Gottliebson WM, Taylor MD, Czosek RJ, et al. Presence of mechanical dyssynchrony in Duchenne muscular dystrophy. *J Cardiovasc Magn Reson Off J Soc Cardiovasc Magn Reson*. 2011;13:12. <https://doi.org/10.1186/1532-429X-13-12>
34. Bilchick KC, Salerno M, Plitt D, Dori Y, Crawford TO, Drachman D, et al. Prevalence and distribution of regional scar in dysfunctional myocardial segments in Duchenne muscular dystrophy. *J Cardiovasc Magn Reson Off J Soc Cardiovasc Magn Reson*. 2011;13:20. <https://dx.doi.org/10.1186%2F1532-429X-13-20>
35. Frankel KA, Rosser RJ. The pathology of the heart in progressive muscular dystrophy: epimyocardial fibrosis. *Hum Pathol*. 1976;7:375–86. [https://doi.org/10.1016/s0046-8177\(76\)80053-6](https://doi.org/10.1016/s0046-8177(76)80053-6)
36. Yasuda S, Townsend D, Michele DE, Favre EG, Day SM, Metzger JM. Dystrophic heart failure blocked by membrane sealant poloxamer. *Nature*. 2005;436:1025–9. <https://doi.org/10.1038/nature03844>
37. Bilchick KC, Saha SK, Mikolajczyk E, Cope L, Ferguson WJ, Yu W, et al. Differential regional gene expression from cardiac dyssynchrony induced by chronic right ventricular free wall pacing in the mouse. *Physiol Genomics*. 2006;26:109–15. <https://doi.org/10.1152/physiolgenomics.00281.2005>

38. Wilke L, Abellan Schneyder FE, Roskopf M, Jenke AC, Heusch A, Hensel KO. Speckle tracking stress echocardiography in children: interobserver and intraobserver reproducibility and the impact of echocardiographic image quality. *Sci Rep. Nature Publishing Group*; 2018;8:1–12. <https://doi.org/10.1038/s41598-018-27412-2>
39. Bleeker GB, Yu C-M, Nihoyannopoulos P, de Sutter J, Van de Veire N, Holman ER, et al. Optimal use of echocardiography in cardiac resynchronisation therapy. *Heart Br Card Soc.* 2007;93:1339–50. <https://dx.doi.org/10.1136%2Fhrt.2005.076422>
40. Anderson LJ, Miyazaki C, Sutherland GR, Oh JK. Patient selection and echocardiographic assessment of dyssynchrony in cardiac resynchronization therapy. *Circulation.* 2008;117:2009–23. <https://doi.org/10.1161/circulationaha.107.721332>
41. Urheim Stig, Edvardsen Thor, Torp Hans, Angelsen Bjørn, Smiseth Otto A. Myocardial Strain by Doppler Echocardiography. *Circulation.* 2000;102:1158–64. <https://doi.org/10.1161/01.cir.102.10.1158>
42. Edvardsen T, Skulstad H, Aakhus S, Urheim S, Ihlen H. Regional myocardial systolic function during acute myocardial ischemia assessed by strain Doppler echocardiography. *J Am Coll Cardiol.* 2001;37:726–30. [https://doi.org/10.1016/s0735-1097\(00\)01160-8](https://doi.org/10.1016/s0735-1097(00)01160-8)
43. McNally EM, Kaltman JR, Benson DW, Canter CE, Cripe LH, Duan D, et al. Contemporary cardiac issues in Duchenne muscular dystrophy. Working Group of the National Heart, Lung, and Blood Institute in collaboration with Parent Project Muscular Dystrophy. *Circulation.* 2015;131:1590–8. <https://doi.org/10.1161/circulationaha.114.015151>
44. Spurney C, Shimizu R, Morgenroth LP, Kolski H, Gordish-Dressman H, Clemens PR, et al. Cooperative International Neuromuscular Research Group Duchenne Natural History Study demonstrates insufficient diagnosis and treatment of cardiomyopathy in Duchenne muscular dystrophy. *Muscle Nerve.* 2014;50:250–6. <https://doi.org/10.1002/mus.24163>
45. Viollet L, Thrush PT, Flanigan KM, Mendell JR, Allen HD. Effects of angiotensin-converting enzyme inhibitors and/or beta blockers on the cardiomyopathy in Duchenne muscular dystrophy. *Am J Cardiol.* 2012;110:98–102. <https://doi.org/10.1016/j.amjcard.2012.02.064>
46. Ogata H, Ishikawa Y, Ishikawa Y, Minami R. Beneficial effects of beta-blockers and angiotensin-converting enzyme inhibitors in Duchenne muscular dystrophy. *J Cardiol.* 2009;53:72–8. <https://doi.org/10.1016/j.jjcc.2008.08.013>
47. Matthews E, Brassington R, Kuntzer T, Jichi F, Manzur AY. Corticosteroids for the treatment of Duchenne muscular dystrophy. *Cochrane Database Syst Rev.* 2016;CD003725. <https://doi.org/10.1002/14651858.cd003725.pub4>
48. Bleeker GB, Holman ER, Steendijk P, Boersma E, van der Wall EE, Schalij MJ, et al. Cardiac resynchronization therapy in patients with a narrow QRS complex. *J Am Coll Cardiol.* 2006;48:2243–50. <https://doi.org/10.1016/j.jacc.2006.07.067>
49. Yu C-M, Chan Y-S, Zhang Q, Yip GWK, Chan C-K, Kum LCC, et al. Benefits of cardiac resynchronization therapy for heart failure patients with narrow QRS complexes and coexisting systolic asynchrony by echocardiography. *J Am Coll Cardiol.* 2006;48:2251–7. <https://doi.org/10.1016/j.jacc.2006.07.054>
50. Bleeker Gabe B., Kaandorp Theodorus A.M., Lamb Hildo J., Boersma Eric, Steendijk Paul, de Roos Albert, et al. Effect of Posterolateral Scar Tissue on Clinical and Echocardiographic Improvement After Cardiac Resynchronization Therapy. *Circulation. American Heart Association*; 2006;113:969–76. <https://doi.org/10.1161/circulationaha.105.543678>

Figures

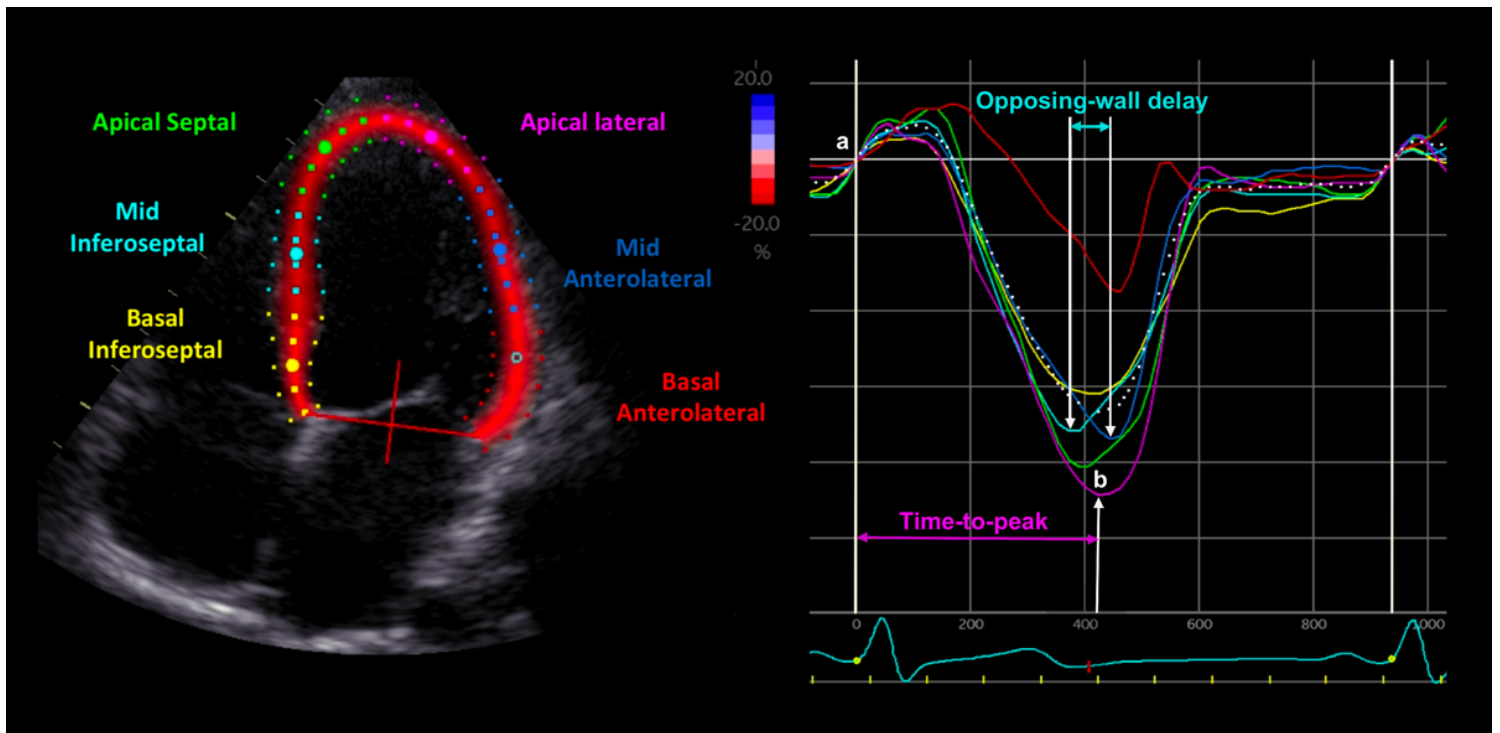


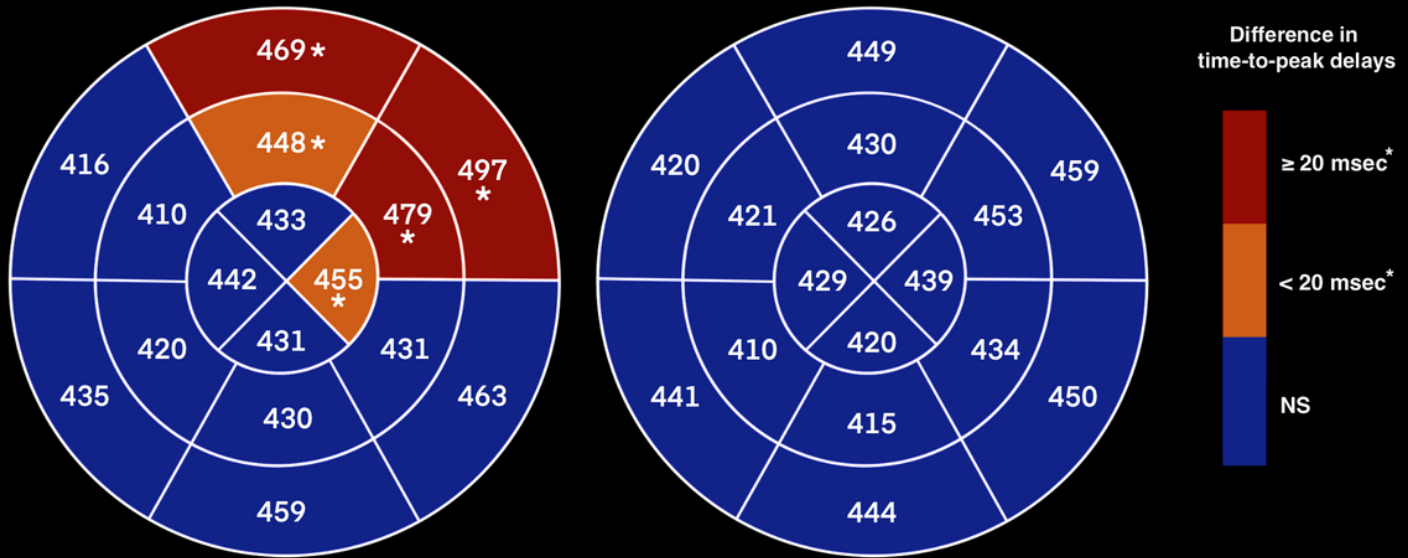
Figure 1

LV longitudinal mechanical dyssynchrony analysis using 2D-STE Legend: On the left side, the LV apical 4-chamber view is automatically divided into 6 segments. On the right side, six color curves represent the 2D-strain deformation corresponding to those segments during a cardiac cycle (simultaneous electrocardiogram is seen at the bottom): yellow (basal inferoseptal segment), light blue (mid inferoseptal segment), green (apical septal segment), purple (apical lateral segment), dark blue (mid anterolateral segment), and red (basal anterolateral segment). Here, the time-to-peak delay of the apical lateral segment (purple curve) is measured between the beginning of the QRS interval (a) and the systolic strain peak (b); and the opposing-wall delay between the two mid segments is measured between the systolic strain peak of the mid inferoseptal segment (light blue curve) and the systolic strain peak of the mid anterolateral segment (dark blue curve).

Mean corrected time-to-peak delays

Children with DMD

Healthy matched controls



Values are expressed in msec
* Significant P-values (comparison between DMD and control groups)

Figure 2

Comparison of LV longitudinal time-to-peak delays between DMD and control groups Legend: The two figures represent, for each group, the time-to-peak delay of each LV segment, corrected by heart rate (using Bazett's formula, expressed in msec), using the 16-segment bull's eye model of myocardial segmentation. The boxes in red represent the segments for which time-to-peak delays were significantly different ($P < 0.05$) between the two groups with a magnitude of the difference ≥ 20 msec (basal anterolateral, mid anterolateral, and basal anterior segments). The boxes in orange represent the segments for which time-to-peak delays were significantly different ($P < 0.05$) between the two groups with a magnitude of the difference < 20 msec (mid anterior and apical lateral segments). The boxes in blue represent the segments for which time-to-peak delays were not significantly different between the two groups (NS, non-significant).

Supplementary Files

This is a list of supplementary files associated with this preprint. Click to download.

- [SupplementaryTableS1.doc](#)
- [SupplementaryTableS2.doc](#)