



**HAL**  
open science

## **Case report of osteomyelitis of the mandible in osteopetrosis and management considerations**

Sarah Allal, Valentin Rabuel, Charline Gengler, Catherine Douchet, Francois Allal, Narcisse Zwetyenga

### ► **To cite this version:**

Sarah Allal, Valentin Rabuel, Charline Gengler, Catherine Douchet, Francois Allal, et al.. Case report of osteomyelitis of the mandible in osteopetrosis and management considerations. *International Journal of Surgery Case Reports*, 2021, 81, pp.105813. <10.1016/j.ijscr.2021.105813>. <hal-03404273>

**HAL Id: hal-03404273**

**<https://hal.umontpellier.fr/hal-03404273v1>**

Submitted on 16 Dec 2021

**HAL** is a multi-disciplinary open access archive for the deposit and dissemination of scientific research documents, whether they are published or not. The documents may come from teaching and research institutions in France or abroad, or from public or private research centers.

L'archive ouverte pluridisciplinaire **HAL**, est destinée au dépôt et à la diffusion de documents scientifiques de niveau recherche, publiés ou non, émanant des établissements d'enseignement et de recherche français ou étrangers, des laboratoires publics ou privés.



Distributed under a Creative Commons CC BY-NC-ND 4.0 - Attribution - Non-commercial use - No Derivative Works - International License



Contents lists available at ScienceDirect

## International Journal of Surgery Case Reports

journal homepage: [www.casereports.com](http://www.casereports.com)

## Case report of osteomyelitis of the mandible in osteopetrosis and management considerations

Sarah Allal<sup>a,\*</sup>, Valentin Rabuel<sup>a</sup>, Charline Gengler<sup>a</sup>, Catherine Douchet<sup>b</sup>, François Allal<sup>c</sup>, Narcisse Zwetyenga<sup>a,d</sup><sup>a</sup> Department of Maxillofacial and Oral Surgery, University Hospital of Dijon, 2 boulevard du Maréchal de Lattre de Tassigny, BP 77908, 21079, Dijon cedex, France<sup>b</sup> Department of Pathology, University Hospital of Dijon, Dijon, France<sup>c</sup> MARBEC, Univ. Montpellier, Ifremer, CNRS, IRD, 34250, Palavas-les-Flots, France<sup>d</sup> CIC-EC 1432 (Centre d'Investigation clinique - Epidémiologie clinique) - Pr QUANTIN Catherine, Chirurgie endocrinienne, Dr GOUDET Pierre, France

## ARTICLE INFO

## Article history:

Received 9 February 2021

Received in revised form 4 March 2021

Accepted 20 March 2021

Available online 23 March 2021

## Keywords:

Osteomyelitis

Mandible

Case report

Osteopetrosis

Management

## ABSTRACT

**INTRODUCTION AND IMPORTANCE:** Osteopetrosis is a poorly known and probably underdiagnosed pathology. It is caused by various genetic abnormalities resulting in osteoclast dysfunction. Functional and aesthetic consequences have a major impact on the patient's quality of life. Ten percent of osteopetrosis cases develop osteomyelitis that usually involves the mandible. Management of this complication remains complex and often unsatisfactory.

**CASE PRESENTATION:** We report a case of a 62-year-old woman with osteopetrosis, complicated by mandibular osteomyelitis with intra-oral bone exposure and submental fistulas. Management was performed with antibiotic therapy and surgical necrotic resection. This cured the fistulas but the bone exposure persisted.

**DISCUSSION:** This case report highlights the difficulty of achieving complete healing of osteomyelitis in osteopetrosis. Antibiotic therapy, surgical management, or even hyperbaric oxygen therapy are required, but must be adapted to the case. A free flap procedure is undesirable but, when it is necessary, a bone marrow transplant could be considered to restore osteoclast function.

**CONCLUSION:** The management of mandibular osteomyelitis in patients with osteopetrosis must adapt to the situation and severity. To avoid most cases of osteomyelitic complications in patients suffering from osteopetrosis, we propose that a preventive strategy of better dental care should be considered.

© 2021 The Authors. Published by Elsevier Ltd on behalf of IJS Publishing Group Ltd. This is an open access article under the CC BY-NC-ND license (<http://creativecommons.org/licenses/by-nc-nd/4.0/>).

## 1. Introduction

Osteopetrosis, also known as Albers-Schoenberg disease [1] and marble bone disease [2,3], was first described in 1904 by the German radiologist Albers-Schoenberg [1,4–7]. This rare genetic bone disorder [1,6] is characterized by an increase in cortical bone mass at the expense of the medullary bone, resulting from a defect in osteoclastic function [1,4]. The genetic basis of osteopetrosis is of two types: autosomal recessive (ARO) and autosomal dominant (ADO) [8]. ARO is a pediatric form leading to severe prognosis, diagnosis is usually made at birth, with a typical dysmorphism and bone marrow failure [9]. Conversely, ADO often remains asymptomatic for many years. It is the most common form of osteopetrosis

with an incidence of 1:20,000 [10]. Diagnosis is usually based on radiological and/or clinical observations after a separate complication such as fracture or infection. Typically, ADO patients display short stature and stout bones, they may suffer from localized or generalized bone pain. Osteosclerosis is visible radiologically, in particular with loss of the corticomedullary gradient [11]. Fractures are frequent and can occur even after minor shocks. One major complication of ADO is osteomyelitis of the mandible, which concerns 10% of the patients. This complication mostly occurs after dental infection [12,13] and deeply impacts the patient's quality of life. The infection, which affects both genders equally [12], results from the combined action of bacterial contamination and loss of vascularization in the mandible [14]. Persisting mandible exposure, necrotic bone sequester, basilar rim fistula, mandible bone suppuration and mandible adjacent collection are classically observed [12]. Management involves antibiotic therapy and surgical treatments including tooth extraction, necrosis sequester removal, abscess drainage, or fistulas cures. In addition, hyperbaric oxygen therapy may be an option [15]. Overall, cure is achieved in less than 50% of cases

\* Corresponding author.

E-mail address: [sarah.allal.cmf@gmail.com](mailto:sarah.allal.cmf@gmail.com) (S. Allal).

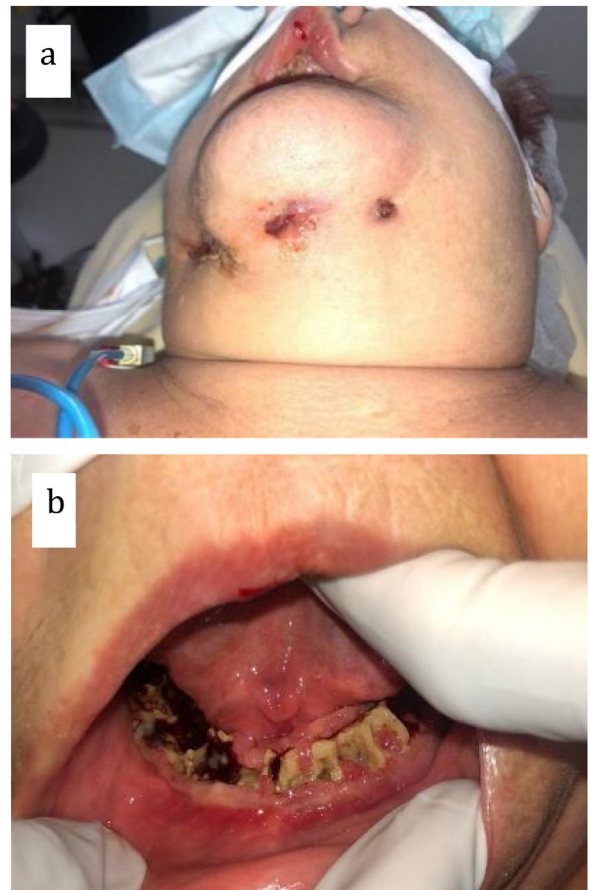
<sup>1</sup> "I warrant that all the authors listed above have made a significant contribution to this manuscript and have agreed to its submission to the international journal of surgery case report".

[12], preventing prosthetic dental rehabilitation [16]. Thus, the recurrence of symptoms has major functional and aesthetic consequences, which affect the quality of life due to feeding difficulties, pain, tooth loss and sometimes purulent discharges. Moreover, reconstruction management is complex for the underlying bone and immunosuppressive pathology of ADO patients. This case, reported in line with the SCARE 2020 criteria [17], highlights an update of current management of osteomyelitis in ADO patients and suggests potential perspectives in its management.

**2. Case presentation**

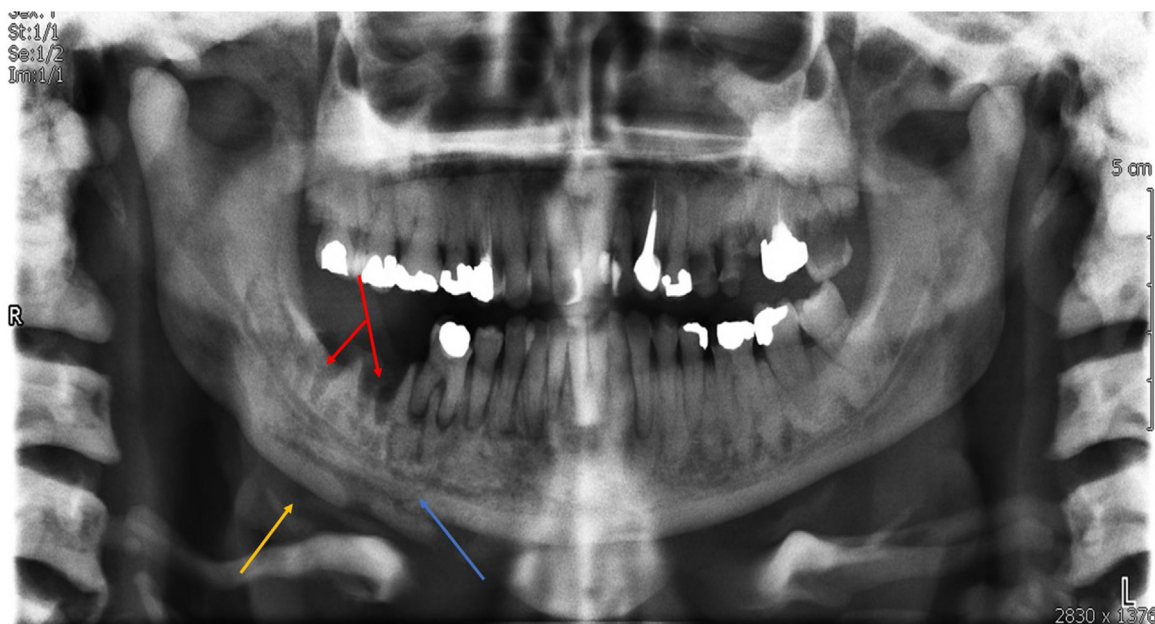
A 62-year-old Caucasian female was referred to our Department of Oral and Maxillofacial Surgery by her family physician for chronic chin fistulas and mandibular bone exposure. Symptoms onset was 6 months prior, following the extraction of 2 mandibular molars. Patient history revealed a diagnosis of osteopetrosis at 30, after numerous lower limb fractures. No molecular sequencing was performed to establish a genetic basis. The surgical history comprised a hip joint prosthesis and several femoral and tibial osteosyntheses. No other personal or family medical history was reported. The patient was an active smoker. Facial examination revealed osteomyelitis from tooth 33 to tooth 48, associated with 3 fistulas (Fig. 1). Intraoral examination revealed widely exposed necrotic alveolar bone in the right mandibular area, confirming diagnosis of osteomyelitis. A written consent was provided.

The dental panoramic X-ray revealed laminated aspects of the mandible, indicating periosteal osteogenic processes. The vacant alveolis' silhouettes suggested an absence of post-extraction scarring (Fig. 2). On CT scan, the mandible presented a plurilamellar aspect (Fig. 3), mainly on the right. Alveolar hypodense gaps suggested necrosis. Cortical ruptures indicated chronic osteomyelitis. No collection was viewed. Fistulous paths were visualized, draining the basilar rim. The CT scan also revealed typical signs of osteopetrosis, such as generalized sclerosis (with obliteration of the medullary spaces and loss of the corticomedullar guard) of facial bones, sinuses obliterations, endobone formations and osteocondensation of the sella turcica (Figs. 2–4 and supplementary Figs. 1 and 2). In the limbs, trabecular bone was destroyed on the long

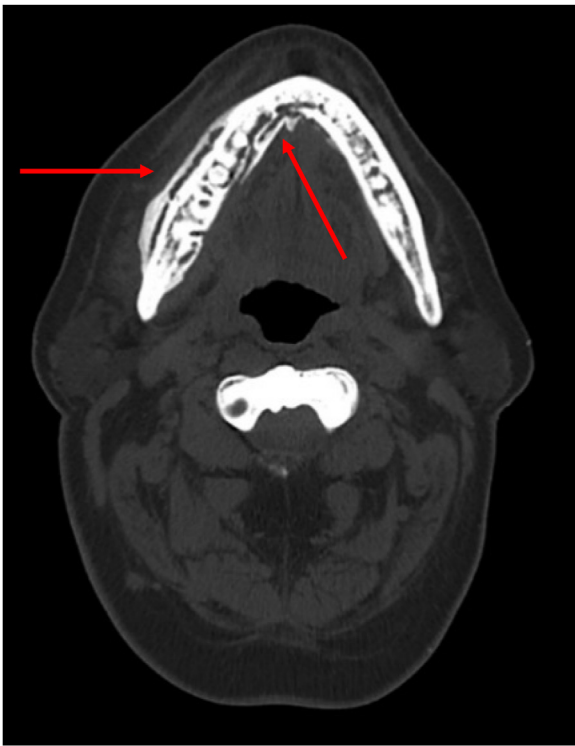


**Fig. 1.** Photographs: 1a. submental fistulas, 1b. mandibular right side after extractions.

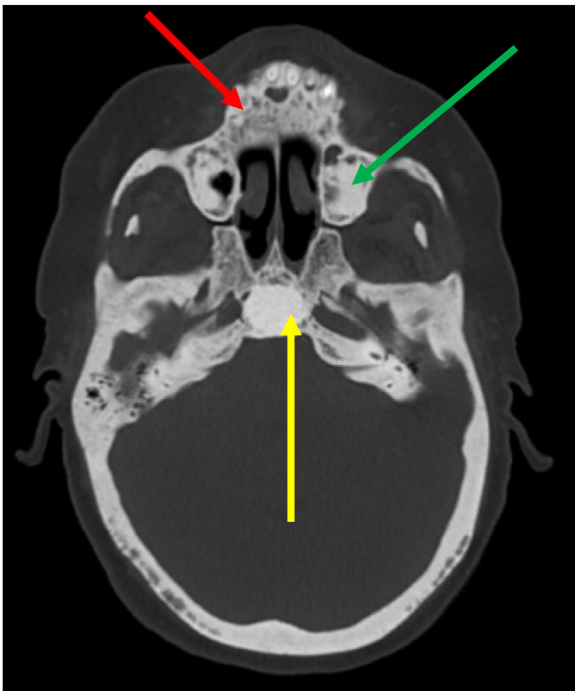
bone metaphyses. We observed typical endobone aspects (supplementary Fig. 1). Osteosynthesis plates of the limb and hip joint prostheses were observable (supplementary Fig. 2). A biological



**Fig. 2.** Panoramic x-ray. The yellow arrow shows laminated appearance of the basilar rim, the blue arrow shows cortical ruptures, the red arrow shows alveolar silhouettes. Maxillary and mandibular osteosclerosis is observable with loss of corticomedullar gradient, and by their intense opacity.



**Fig. 3.** CT scan cross sections, bone window. The red arrows show the plurilamellar aspect of the body of the mandible.



**Fig. 4.** CT scan cross-sections, bone window, the yellow arrow shows osteocondensation of the sella turcica, the red arrow shows with maxillary osteosclerosis, the green arrow shows maxillary intrasinusal osteogenic processes.

assessment revealed normocytic anemia, normochromic anisocytosis and moderate thrombocytopenia.

For the first 6 months, the patient was primarily treated with sequential antibiotic therapy using Amoxicillin/Clavulanic acid, then with Clindamycin adapted to the antibiogram. This treatment was effective and well-tolerated but infection recurred in each

antibiotic window and the bone exposure continued to increase. The senior maxillofacial surgeon performed a procedure to extract all mandibular teeth (except 37 and 38), with minimal bone trimming and closure of the oroantral fistulas. Given the severe anemia (hemoglobin 75 g/L), two homologous red blood cells transfusions were performed during the procedure. A bone biopsy during surgery showed non-specific hypercondensing osteonecrosis, optically empty necrotic lacunae, sometimes nested with foci of actinomyces and absence of vessels. The bone structure showed constitutional architectural abnormalities such as disorganization of the bone lamellae and near absence of connective tissue (supplementary Fig. 3).

Postoperatively, the patient received 45 days of Clindamycin and daily mouthwashes of metronidazole. Over the next 5 months, the fistulas did not recur but intraoral bone exposure remained unresolved.

### 3. Discussion

More than 10% of ADO is associated with osteomyelitis of the mandible, which represents 2–3 times more than after head and neck radiotherapy, and 1000 to 10,000 times more than after bisphosphonates [22]. Although this complication is not fatal, quality of life is profoundly affected.

#### 3.1. Patient management and outcome

In the case presented, a 62-year-old woman suffered from mandibular osteomyelitis. Tooth extraction, bone trimming, fistula cures, and antibiotic treatment, stabilized the infection. However, bone exposure remained and the risk of recurrence of infection is high due to the persistence of ischemia and contamination of the bone [18]. The prospect is to continue regular patient follow-up in our department. Depending on developments, antibiotic treatments and/or minimal debridement will be proposed. A local flap to cover the bone exposure could also be performed. The objective is to preserve mandibular bone capital.

#### 3.2. Therapeutic issues

Whatever the context, a patient with osteopetrosis must be managed comprehensively, with a multidisciplinary approach. Patients have immune fragility with, in particular, anemia, hypocalcemia, thrombocytopenia. Firstly, these must be diagnosed and corrected to improve tolerance and effectiveness of future treatments [18]. Antibiotic therapy generally uses Amoxicillin with clavulanic acid as the main choice, then Clindamycin as follow up but no study suggests a specific duration. In other etiologies of mandibular osteomyelitis, depending on the course, this may vary from 1 week to several years as in osteochemonecrosis [20]. In refractory cases, hyperbaric oxygen therapy can promote local healing and could be used before or after surgical treatment [21]. Teeth extractions should be approached carefully because carious teeth can be sources of osteomyelitis, but the procedure itself can be a gateway to infection [10]. Surgical treatment should be as conservative as possible, combining curettage, sequestrectomy and minimal bone trimming, associated with covering flaps to protect the periosteal surfaces. Calcium sulfate implants impregnated with vancomycin may be used to reconstruct bone defects [22]. An interrupting mandibulectomy should be reserved for situations of osteomyelitis fracture or for refractory infection situations, and in patients in good general condition. Reconstruction in such cases may require a free flap [23]. Eppley and Coleman's team seemed to offer this technique as a benchmark after succeeding in a patient with osteopetrosis [24]. But the success of this complex procedure

is threatened by persisting osteoclastic dysfunction and immunodeficiency. In infantile forms, a bone marrow or hematopoietic stem cell transplant usually restores both functions [8]. These procedures could potentially be considered in complicated forms of mandibular osteomyelitis in osteopetrosis before free flap surgery to allow a better chance of bone healing.

### 3.3. Dental prevention

No systematic dental prevention is yet proposed in osteopetrosis, although it could probably prevent many cases of osteomyelitis [19]. In our report, as for all mandibular osteomyelitis in ADO patients reported in the literature [12], osteomyelitis is triggered by dental infection. Regarding these data, it is crucial to engage preventive measures and dental protection. No dental action is trivial and capital dental preservation should be performed at all costs, with frequent dental reviews and professional dental cleanings. A fluoride treatment could be provided to prevent caries [25]. When an extraction is necessary it should be performed by referred specialists under optimal conditions of bone protection and under antibiotic prophylaxis [25]. Postoperative scarring should be carefully monitored [19]. Such a policy would most likely decrease the occurrence of osteomyelitis. In patients treated with bisphosphonates, dental prevention reduced the risk of osteomyelitis by four (OCN) [26–28].

## 4. Conclusion

Mandibular osteomyelitis is a frequent complication of osteopetrosis. Despite different management strategies, outcomes often remain unsatisfactory. This case report highlights the importance of maintaining the existing mandibular bone with a management strategy combining antibiotic therapy and minimally invasive surgical debridement. Reconstruction and rehabilitation are extremely limited due to bone pathology and immunodeficiency. A key learning from the reported case is the importance of deploying specific preventive dental care as soon as a diagnosis of osteopetrosis is made. Indeed, such prevention could have avoided the complication reported here.

### Declaration of Competing Interest

Authors declare no conflict of interest.

### Sources of funding

No funding resource is to declare.

### Ethical approval

This case reports is exempt from ethical approval in my institution.

### Consent

No explicit details regarding the identification of the patient is provided in the manuscript including text and images.

### Author contribution

Sarah ALLAL led the writing and the literature review. Sarah ALLAL, Valentin RABUEL, Charline GENGLER, Narcisse ZWETYENGA and François ALLAL participated to the writing of the manuscript. Catherine DOUCHET realized the bone biopsy analysis including microscopic imaging.

### Registration of research studies

Not applicable.

### Guarantor

Sarah Allal is the guarantor and accepts full responsibility for the work and/or the conduct of the study, had access to the data, and controlled the decision to publish.

### Provenance and peer review

Not commissioned, externally peer-reviewed.

### Acknowledgement

The authors wish to thank Dr. David J. McKenzie for having checked the spelling, grammar and syntax of the article.

### Appendix A. Supplementary data

Supplementary material related to this article can be found, in the online version, at <https://doi.org/10.1016/j.ijscr.2021.105813>.

### References

- [1] A.D. Elster, E.G. Theros, L.L. Key, M.Y. Chen, Cranial imaging in autosomal recessive osteopetrosis. Part I. Facial bones and calvarium, *Radiology* 183 (April (1)) (1992) 129–135, <http://dx.doi.org/10.1148/radiology.183.1.1549658>.
- [2] C.P. Barry, C.D. Ryan, L.F.A. Stassen, Osteomyelitis of the maxilla secondary to osteopetrosis: a report of 2 cases in sisters, *J. Oral Maxillofac. Surg.* 65 (January (1)) (2007) 144–147, <http://dx.doi.org/10.1016/j.joms.2005.07.019>.
- [3] R.J. Bakeman, R.A. Abdelsayed, S.H. Sutley, R.F. Newhouse, Osteopetrosis: a review of the literature and report of a case complicated by osteomyelitis of the mandible, *J. Oral Maxillofac. Surg.* 56 (October (10)) (1998) 1209–1213, [http://dx.doi.org/10.1016/s0278-2391\(98\)90774-1](http://dx.doi.org/10.1016/s0278-2391(98)90774-1).
- [4] K.J. Juggins, G.M. Walton, M. Patel, Osteomyelitis complicating osteopetrosis—a case report, *Dent. Update* 28 (December (10)) (2001) 509–511, <http://dx.doi.org/10.12968/denu.2001.28.10.509>.
- [5] M. Steiner, A.R. Gould, W.R. Means, Osteomyelitis of the mandible associated with osteopetrosis, *J. Oral Maxillofac. Surg.* 41 (June (6)) (1983) 395–405, [http://dx.doi.org/10.1016/s0278-2391\(83\)80011-1](http://dx.doi.org/10.1016/s0278-2391(83)80011-1).
- [6] M.A.P. Albuquerque, E.S. Melo, W.A. Jorge, M.G.P. Cavalcanti, Osteomyelitis of the mandible associated with autosomal dominant osteopetrosis: a case report, *Oral Surg. Oral Med. Oral Pathol. Oral Radiol. Endod.* 102 (July (1)) (2006) 94–98, <http://dx.doi.org/10.1016/j.tripleo.2005.08.019>.
- [7] G.E. Chacon, C.M. Ugalde, M.F. Jabero, Genetic disorders and bone affecting the craniofacial skeleton, *Oral Maxillofac. Surg. Clin. North Am.* 19 (November (4)) (2007) 467–474, <http://dx.doi.org/10.1016/j.joms.2007.08.001>.
- [8] C. Sobacchi, A. Schulz, F.P. Coxon, A. Villa, M.H. Helfrich, Osteopetrosis: genetics, treatment and new insights into osteoclast function, *Nat. Rev. Endocrinol.* 9 (September (9)) (2013), <http://dx.doi.org/10.1038/nrendo.2013.137>, Art. no 9.
- [9] L. Barnea Slonim, C. Glasser, Infantile osteopetrosis, *J. Pediatr. Hematol. Oncol.* 40 (3) (2018) 225–226, <http://dx.doi.org/10.1097/MPH.0000000000001108>.
- [10] C.C. Wu, et al., Diagnosis and management of osteopetrosis: consensus guidelines from the osteopetrosis working group, *J. Clin. Endocrinol. Metab.* 102 (9) (2017) 3111–3123, <http://dx.doi.org/10.1210/jc.2017-01127>, 01.
- [11] J. Bollerslev, Autosomal dominant osteopetrosis: bone metabolism and epidemiological, clinical, and hormonal aspects, *Endocr. Rev.* 10 (February (1)) (1989) 45–67, <http://dx.doi.org/10.1210/edrv-10-1-45>.
- [12] P.Hde A. Carvalho, L.B. Moura, M.F. Real Gabrielli, M.A. Cabrini Gabrielli, V. Antonio Pereira Filho, Maxillary osteomyelitis associated with osteopetrosis: systematic review, *J. Cranio-maxillofacial Surg.* 46 (November (11)) (2018) 1905–1910, <http://dx.doi.org/10.1016/j.jcms.2018.09.004>.
- [13] P. Batra, N. Shah, Recalcitrant osteomyelitis following tooth extraction in a case of malignant osteopetrosis, *Int. Dent. J.* 54 (December (6)) (2004) 418–423, <http://dx.doi.org/10.1111/j.1875-595x.2004.tb00298.x>.
- [14] C.M. García, M.A.P. García, R.G. García, F.M. Gil, Osteomyelitis of the mandible in a patient with osteopetrosis. Case report and review of the literature, *J. Maxillofac. Oral Surg.* 12 (1) (2013) 94–99, <http://dx.doi.org/10.1007/s12663-011-0196-y>, mars.
- [15] P. Peponis, C. Keilman, C. Guerry, J.J. Freiburger, Hyperbaric oxygen therapy and osteonecrosis, *Oral Dis.* 23 (2) (2017) 141–151, <http://dx.doi.org/10.1111/odi.12489>.

- [16] T. Celakil, M. Dogan, B.G. Rohlig, G. Evlioglu, H. Keskin, Oral rehabilitation of an osteopetrosis patient with osteomyelitis, *Case Rep. Dent.* 2016 (2016) 6930567, <http://dx.doi.org/10.1155/2016/6930567>.
- [17] R.A. Agha, T. Franchi, C. Sohrabi, G. Mathew, A. Kerwan, SCARE Group, The SCARE 2020 guideline: updating consensus surgical CAse REport (SCARE) guidelines, *Int. J. Surg.* 84 (December) (2020) 226–230, <http://dx.doi.org/10.1016/j.ijvsu.2020.10.034>.
- [18] A. Kulyapina, J. Verdaguer Martin, C. Navarro Cuellar, C. Navarro Vila, Long-term follow-up of bimaxillary osteomyelitis associated with autosomal dominant osteopetrosis: a case report, *J. Maxillofac. Oral Surg.* 15 (1) (2016) 121–126, <http://dx.doi.org/10.1007/s12663-015-0749-6>, mars.
- [19] D.K. Lam, G.K.B. Sándor, H.I. Holmes, R.P. Carmichael, C.M.L. Clokie, Marble bone disease: a review of osteopetrosis and its oral health implications for dentists, *J. Can. Dent. Assoc.* 73 (9) (2007) 5.
- [20] C.-V. Andre, R.-H. Khonsari, D. Ernenwein, P. Goudot, B. Ruhin, Osteomyelitis of the jaws: a retrospective series of 40 patients, *J. Stomatol. Oral Maxillofac. Surg.* 118 (October (5)) (2017) 261–264, <http://dx.doi.org/10.1016/j.jormas.2017.04.007>.
- [21] E.G. Mainous, G.B. Hart, D.J. Soffa, G.A. Graham, Hyperbaric oxygen treatment of mandibular osteomyelitis in osteopetrosis, *J. Oral Surg.* 33 (April (4)) (1975) 288–291.
- [22] H.-J. Sun, L. Xue, C.-B. Wu, Q. Zhou, Use of vancomycin-impregnated calcium sulfate in the treatment of osteomyelitis of the jaw, *J. Oral Maxillofac. Surg.* 75 (January (1)) (2017) 119–128, <http://dx.doi.org/10.1016/j.joms.2016.06.178>.
- [23] H.-J. Sun, L. Xue, C.-B. Wu, Q. Zhou, Clinical characteristics and treatment of osteopetrosis complicated by osteomyelitis of the mandible, *J. Craniofac. Surg.* 27 (November (8)) (2016) e728–e730, <http://dx.doi.org/10.1097/SCS.0000000000003048>.
- [24] B.L. Eppley, J.J. Coleman, Free fibular flap reconstruction in mandibular osteopetrosis, *J. Craniofac. Surg.* 12 (July (4)) (2001) 369–372, <http://dx.doi.org/10.1097/00001665-200107000-00010>.
- [25] V. Detailleur, G. Vansteenkiste, M. Renard, A. Verdonck, Dental care approach in patients with osteopetrosis, *Eur. Arch. Paediatr. Dent.* 17 (December (6)) (2016) 435–443, <http://dx.doi.org/10.1007/s40368-016-0251-y>.
- [26] Société Française de Chirurgie Orale, Prise en charge des foyers infectieux bucco-dentaires, *Med Buccale Chir Buccale* 18 (August (3)) (2012) 251–314, <http://dx.doi.org/10.1051/mbcb/2012027>.
- [27] S. Fedele, N. Kumar, R. Davies, J. Fiske, S. Greening, S. Porter, Dental management of patients at risk of osteonecrosis of the jaws: a critical review, *Oral Dis.* 15 (November (8)) (2009) 527–537, <http://dx.doi.org/10.1111/j.1601-0825.2009.01581.x>.
- [28] R.E. Marx, Y. Sawatari, M. Fortin, V. Broumand, Bisphosphonate-induced exposed bone (osteonecrosis/osteopetrosis) of the jaws: risk factors, recognition, prevention, and treatment, *J. Oral Maxillofac. Surg.* 63 (November (11)) (2005) 1567–1575, <http://dx.doi.org/10.1016/j.joms.2005.07.010>.

#### Open Access

This article is published Open Access at [sciencedirect.com](https://www.sciencedirect.com). It is distributed under the [IJSCR Supplemental terms and conditions](#), which permits unrestricted non commercial use, distribution, and reproduction in any medium, provided the original authors and source are credited.