

Title

Comparison between combined cortical and cancellous bone graft and cancellous bone graft in alveolar cleft: retrospective study of complications during the first six months post-surgery.

Authors

Thomas Vandeputte ¹, Michèle Bigorre MD PHD², Paul Tramini MD PHD^{1,3},

Guillaume Captier Prof MD PHD^{2,3}.

Affiliation

1 Centre de soin dentaire, CHU Montpellier

2 Chirurgie plastique pédiatrique, CHU Montpellier, Université de Montpellier, Montpellier, France

3 Aide à la décision médicale personnalisée, aspect méthodologique, EA2415, Université de Montpellier, Montpellier France.

Corresponding author

Thomas VANDEPUTTE

Summary

Background: In patients with alveolar cleft, alveolar bone graft is usually performed before the permanent maxillary canine or incisor eruption and using cancellous bone harvested from the iliac crest. The authors sought to compare the early complication rate in patients who received cancellous bone graft alone and cortical bone graft in addition to cancellous bone to reconstruct the nasal floor.

Methods: For this observational, retrospective, monocentric study, patients with alveolar cleft who underwent autologous alveolar bone graft and gingivoperiosteoplasty at Montpellier Hospital were divided into two groups: group A, who had cortical and cancellous bone graft; and group B, who had only cancellous bone graft. Both groups were followed for 6 months after surgery, and complications were recorded.

Results: In total, 319 grafts (group A, 163; group, 156) were performed from June 1999 to May 2016. The major complication rates were 8% and 5.8% in group A and B, respectively, and were not significantly different ($p=0.52$). Similarly, the rates of minor complications and of donor site morbidity were not different between groups.

Conclusions: This preliminary study shows that adding a cortical bone graft for the nasal floor reconstruction does not increase the risk of complications in 6 months following the graft. Long-term benefits such as alveolar height and a piriform aperture symmetrisation will have to be analysed to study the contribution of the technique.

Key words: alveolar bone graft, cleft lip and palate, autograft, bone regeneration, post-operative complications

INTRODUCTION

Alveolar cleft associated with cleft lip with or without cleft palate is a typical non-syndromic orofacial cleft phenotype (Mossay et al., 2009). It involves the interruption of the alveolar process of the maxilla and perturbs growth and dentition. Its repair by bone graft and gingivoperiosteoplasty allows restoring the maxillary bone continuity and stabilizing the premaxillary bone in patients with bilateral cleft. This intervention also favors tooth eruption, improves orthodontic treatment outcome, and allows reconstituting the nasal cavity floor (Gillgras et al., 2014, Montoya et al., 2002). Normally, secondary bone graft is performed before the eruption of the permanent maxillary canine (Kaura et al., 2018), and more recently before the eruption of the permanent maxillary incisors (Fahradyan et al., 2018, Dissaux et al., 2016). It is frequently done using cancellous bone harvested from the iliac crest (Zhou et al., 2019), with an overall complication rate between 15% and 40% (Borba et al., 2014) and a failure rate between 1.5% and 6% (Lilja et al., 2000, Witherow et al., 2002, Newlands et al., 2000, Hynes et al., 2003). Graft failure is mainly caused by graft infection or gingivoperiosteal flap dehiscence. The failure risk increases in the presence of fistulae and of bilateral cleft, or when graft is performed after 12 years of age, at the time of permanent canine eruption (Borba et al., 2014). The use of bone substitutes with the aim of decreasing surgery morbidity has not shown its superiority compared with iliac crest grafts (Liang et al., 2018).

The addition of a thin piece of cortical bone at the level of the nasal floor during the alveolar cleft repair allows separating the nasal mucosa from the cancellous bone graft (Precious et al., 2009). It prevents the leak of the cancellous graft in the nasal cavity if the nasal mucosa is not totally sealed. Moreover, it constitutes an additional wall in the cleft to receive the cancellous graft. In the long term, it could provide a better alveolar bone height and symmetrical piriform apertures for the support of the alar wings. However, this technique increases the

time required for bone harvesting, and renders more complex the graft with gingivoperiosteoplasty, particularly due to the less good cortical bone vascularization (Albrektsson et al., 1980). This potentiates the risk of poor cortical bone graft integration and of total graft loss.

This study aimed at assessing whether addition of a cortical bone plate bone underneath the nasal mucosa has an influence on graft failure and comorbidities during a short-term follow-up.

MATERIALS AND METHODS

Patients and procedures

This was an observational, retrospective, monocentric study in patients followed at the pediatric plastic surgery service of Montpellier University Hospital from 1999 to May 2016. This study was approved by the local ethics committee (no. 2019_IRB-MTP_03-25) and followed the recommendations of the Declaration of Helsinki.

Patients were included if they had unilateral or bilateral alveolar cleft associated with cleft lip with or without cleft palate, and underwent secondary alveolar graft with gingivoperiosteoplasty (at any age) performed by one of the three surgeons of the service. They also needed to have a post-surgery follow-up of at least 6 months. Patients were included regardless of the primary surgery procedure and center where it was performed. Patients with non-syndromic and syndromic clefts were not differentiated. Exclusion criteria were history of multiple alveolar grafts, incomplete post-surgery follow-up (less than 6 months), and bone harvesting from a donor site other than the iliac crest.

The included patients were divided into two groups: group A (alveolar graft with cancellous bone and a thin piece of cortical bone), and group B (graft of only cancellous bone). For both groups, bone grafts were from the iliac crest. The addition of cortical bone corresponded to a change in the service practice introduced for the reconstruction of the lower part of the piriform aperture and nasal cavity, as proposed by Precious et al. (Precious et al., 2009). This change of technique was implemented during 2008 concomitantly with the reduction of the age of alveolar bone graft (from before the maxillary canine eruption to before the eruption of the permanent central incisor). The thin cortical bone graft was harvested from the medial face of the iliac crest after cancellous bone collection. Then, the cleft alveolus was prepared by dissecting and turning back two gingival mucoperiosteal advancement flaps, and the

periosteum was elevated (Captier et al., 2003). The cortical bone piece was cut according to the cleft size and was inserted in the alveolar cleft after having lifted the nasal mucosa with its periosteum. It was placed at the level of the nasal floor to reconstruct the lower part of the piriform aperture and the floor of the nasal cavity (Figure 1). In the presence of a fistula, the communication towards the nasal cavity was sutured, if possible. Otherwise, the nasal periosteum was retracted before placing the thin cortical bone graft. The cortical side of this graft was placed against the nasal periosteum. Therefore, the medullary side faced the cancellous bone graft (Precious et al., 2009). This allowed supporting the nasal plane and avoiding the displacement of the cancellous bone graft in the nasal cavity (Figure 2). It also separated the cancellous bone graft from the nasal floor during the time required for the vascularization.

If necessary, the collapsed maxillary arch was treated orthodontically before alveolar grafting to ensure the best outcome. It consisted in palatal expansion by a quadhelix to improve the maxillary arch in the transversal dimension. When the palatal expansion was sufficient (inter-canine length of maxillary arch larger than the inter-canine length of the mandible arch), the graft was performed. The quadhelix was left according to the patient and phonetic tolerance for at least 6 months after the surgery.

Peri-operative prophylaxis with antibiotics was performed in all patients according to the recommendations of the French Society of Anesthesia and Intensive Care Medicine adapted to children. Patients were seen at 1 and 6 months after surgery to detect immediate or secondary complications.

Data were extracted from the patients' electronic health records and from classical paper records for the oldest cases (n=70) without electronic health record. The following data on the graft outcome at 1 and 6 months were collected: gingival healing at 1 month, prescription

of antibiotic treatments, bony sequestrum, need of a second graft, fistula relapse at the 6-month visit, donor site morbidity, and concomitant closure of the palatal fistula. On the basis of these elements and according to the Clavien–Dindo classification, three possible outcomes were defined:

- 1) No complication (simple post-surgery course), corresponding to good healing at 1 month and 6 months post-surgery, without comorbidities or graft loss. It corresponds to a grade I in the Clavien–Dindo classification, and the patient did not require any medication.
- 2) Minor complications in the first month post-surgery without graft loss at 6 months post-surgery. This included wound healing problems by defect (dehiscence) or excess (epulis), or a local infection (discharge, malodorousness, inflammation) that did not lead to bony sequestrum; A curative antibiotherapy has been prescribed to most of these patients because a starting infection was suspected. This is a grade II in the Clavien–Dindo classification.
- 3) Major complication that led to partial or total loss of the bone graft at 6 months post-surgery, ranging from bony sequestrum to complete graft loss that required a new graft. Patient who excelled a bony sequestrum had at least a curative antibiotherapy, which represents a grade II in the Clavien–Dindo classification. A patient who lost the whole graft needed a revision surgery. It corresponds to a grade III in the Clavien–Dindo classification.

The primary outcome was the occurrence of major post-surgery complications (e.g., partial or total graft loss). Secondary outcomes included the occurrence of minor complications, donor site complications, and influence of the palatal or oral-nasal fistula management concomitantly with the alveolar graft on the risk of major complications.

Statistical analysis

Sample size determination

On the basis of a complication rate of 25% in group B (without cortical bone graft), the complication rate in group A should be 40%. With a type 1 error of 5% and a power of 90%, at least 150 grafts per group are needed. This study included 156 grafts in group B and 163 in group A. One grafted side was considered as an event. Therefore, patients with bilateral cleft had two graft events (during a single surgery), whereas patients with unilateral cleft had a single graft event.

Statistical analysis

Categorical variables were presented as percentages, and analyzed using the chi-square test in bivariate analysis to compare the outcome rates (no complication/minor complications/major complications) and the potential influencing factors in the two groups. A stepwise multiple ordinal logistic regression analysis was used in a multilevel mixed model to analyze the relationships between surgery outcome (no complication/minor complications/major complications) and independent variables, particularly the presence of cortical bone graft. The random effect was the subject level. The results of the logistic analysis were presented with adjusted odds ratio (aOR) and 95% confidence interval (CI) estimated for the variables included in the final model. All analyses were performed with the Stata 15.1 software, and the significance level was set at 0.05.

RESULTS

During the period from 1999 to 2016, a total of 381 alveolar bone grafts with gingivoperiosteoplasty were performed in the service. However, 62 graft events were

excluded because of absence of post-surgery follow-up, multiple grafts, or missing data.

Among the remaining 319 grafts, 163 were performed in 121 children from group A (cortical and cancellous bone graft), and 156 were performed in 129 children from group B (only cancellous bone graft) (Table 1). Comparison of the two groups showed that children in group A were significantly younger than in group B (13.12 ± 7.4 years and 20.01 ± 5.35 years, respectively; $p=0.0001$). Moreover, the number of clefts of lip and palate was significantly higher in group A than in group B (147 and 123; $p=0.01$). Conversely, sex distribution and number of unilateral and bilateral clefts were comparable between groups.

Major complications leading to graft loss were recorded for 13 graft events (8%) in group A and 9 events (5.8%) in group B (Table 2). Minor complications were observed for 34 events (20.8%) in group A and for 27 (17.3%) in group B. No significant difference between groups was detected for both major and minor complications ($p=0.52$, Chi-square test).

Complications at the donor site were reported for 12 grafts (6.94%) in group A and in 6 grafts (4.14%) in group B (not significant, $p=0.26$).

As age was significantly different between groups (Table 1), we checked whether the younger age of patients in group A could mask a possible higher morbidity of cortical-cancellous grafts, thus leading to the absence of between-group differences in complication rates. However, comparison of the complication rates in the different age groups for all patients did not highlight any difference (Figure 3).

Fistula treatment concomitantly with the alveolar bone graft and gingivoperiosteoplasty was performed in 61 patients without any significant difference between the groups ($n=40$ in group A and $n=21$ in group B; $p=0.28$).

Comparison of the complication rate in patients with unilateral and bilateral cleft in the entire sample showed that their number was significantly higher in the patients with bilateral cleft ($p=0.03$) (Figure 4).

Finally, analysis of the association of between surgical complications and independent variables (sex, age, cleft side, and cortical bone graft) using a multilevel mixed-effect ordinal logistic model did not find any significant association (Table 3).

DISCUSSION

The use of a thin piece of cortical bone to reconstruct the floor of the nasal cavity during alveolar bone graft in unilateral and bilateral clefts is a safe technique. It does not increase, but also does not reduce, the rate of major and minor complications compared with the classical technique in which only cancellous bone from the iliac crest is grafted. Moreover, the separation of the cancellous bone graft and of the nasal mucosa by the cortical bone graft does not improve graft retention.

The global complication rate of about 29% (8% for major complications) for concomitant cortical and cancellous bone graft in our study is comparable to that of cancellous bone graft alone, which ranges between 15% and 40%, according to Borba et al. in 2013 (Borba et al., 2013, Borba et al., 2014, Hynes et al., 2003, Liang et al., 2018, Cho-Lee et al., 2013). Although first described by Precious et al. in 2009 and then by Mathew et al. in 2017 (Mathew et al., 2017), no work has assessed yet the morbidity of this surgery technique. Indeed, previous studies on concomitant cortical-cancellous bone graft evaluated only the residual bone volume (Zhou et al., 2019). Other studies have evaluated the possibility of using other donor sites for bone grafting. For instance, cortical mandibular bone has been used with a success rate close to 85% (Mikoya et al, 2010). However, it seems that this donor

site does not allow obtaining enough cancellous bone. Cranial bone also has been used (Hudak et al., 2014), but again the amount of available cancellous bone was limited. Although the complication rate was comparable to that of the graft from the iliac crest bone, the potential severity of complications makes this method not very suitable. The current trend is to develop allograft techniques in order to decrease the surgery morbidity. For the validation of these techniques, several criteria must be met. The procedure does not have to be associated with more complications. This has been shown in the study by Hammoudeh et al., in 2017 with bone morphogenetic protein 2 (Hammoudeh et al., 2017). Moreover, the graft results in terms of bone reconstruction must be at least equivalent to those of the reference technique. A longer follow-up is needed to determine the allograft outcome after several years.

The complication rate at the level of the donor site was 6.9% in group A and 4.1% in group B, in agreement with literature data (Vura et al., 2013, Wheeler et al., 2016). Post-surgery pain in the hip was the most frequently described complication. Continuous local infiltration of ropivacaine (Ouaki et al., 2009) gives very good results, and sometimes allows avoiding treatment with oral pain killers.

The minor and major complication rates were higher in patients with bilateral cleft compared with patients with unilateral cleft. This result was expected because bilateral clefts are considered a risk factor for graft failure (Borba et al., 2014). On the other hand, the concomitant treatment of oral-nasal fistulae (n=40 in group A and n=21 in group B; p=0.28) did not increase the graft complication rate and did not have any negative impact. Therefore, the association of this surgical approach should not be considered as a risk factor for complications that could lead to graft failure.

Older age at the time of the graft has been frequently considered as a risk factor for complications (Pessoa et al., 2017, Kaura et al., 2018). In the literature, most studies have

shown that better results are obtained when the graft is performed earlier (Dissaux et al., 2016). On the basis of these data and the study by Precious et al. (Precious et al., 2009), since 2009 patients in our service have no longer undergone grafting before the eruption of the maxillary canine, but much earlier than the eruption of the central incisor (i.e., at 5-6 years of age). This explains why the mean age was significantly different between groups (13.12 years in group A and 20.1 years in group B). However, the complication rate was not different between groups.

These rather positive results of alveolar grafts with gingivoperiosteoplasty can be partly explained by the learning curve of the surgery team, who, over the years, has learned how to adapt and anticipate possible difficulties (Borba et al., 2014). Moreover, patients concomitantly received orthodontic treatment. Literature data have shown that the outcomes of secondary alveolar grafts are better when there is an orthodontic support (Shirani et al., 2012). In our service, the graft is usually performed after several months of maxillary expansion using a quad-helix appliance that is left in place after surgery.

This study has some limitations. First, this is a retrospective work, which could explain, in part, the number of missing data and the loss of power compared with a prospective study. Second, we were not concerned about the dental maturity at the graft and the existence of agenesis. The presence or absence of teeth on the operative site could influence the healing. We did not take into account the increasing expertise of the surgeons who practiced throughout the period of the study and gained time and precision.

CONCLUSION

This was a preliminary study, which found that in the short term, using a cancellous bone graft from the iliac bone and a thin piece of cortical bone is not less safe for patients than the graft of only cancellous bone. It seems to be a promising surgical technique. In the

future, after several years of follow-up, outcomes such as alveolar height and the symmetrization of the piriform aperture could be evaluated. They could also be compared with the results obtained by alveolar graft performed with cancellous bone only, to verify whether the hypothetical benefits exist. The bone volume at the end of growth could allow the placement of a dental implant without a new bone augmentation, in the event of agenesis.

Conflict of interest

The authors declare that they do not have any conflict of interest.

REFERENCES

Albrektsson T. Repair of bone grafts. A vital microscopic and histological investigation in the rabbit. *Scand J Plast Reconstr Surg.* 1980;14(1):1–12.

Borba AM, Borges AH, da Silva CSV, Brozoski MA, Naclério-Homem M da G, Miloro M. Predictors of complication for alveolar cleft bone graft. *Br J Oral Maxillofac Surg.* 2014 Feb;52(2):174–8.

Captier G, Bigorre M, Mattei L, Delestan C, Montoya P. [The secondary bone grafting in cleft lip and palate: technical notes and indications about 62 cases]. *Ann Chir Plast Esthet.* 2003 Feb;48(1):20–30.

Cho-Lee G-Y, García-Díez E-M, Nunes R-A, Martí-Pagès C, Sieira-Gil R, Rivera-Baró A. Review of secondary alveolar cleft repair. *Ann Maxillofac Surg.* 2013 Jan;3(1):46–50

Dissaux C, Bodin F, Grollemund B, Bridonneau T, Kauffmann I, Mattern J-F, et al. Evaluation of success of alveolar cleft bone graft performed at 5 years versus 10 years of age. *J Cranio-Maxillofac Surg.* 2016 Jan;44(1):21–6.

Fahradyan A, Tsuha M, Wolfswinkel EM, Mitchell K-AS, Hammoudeh JA, Magee W. Optimal timing of secondary alveolar bone grafting: a literature review. *J Oral Maxillofac Surg.* 2018 Nov 26.

Gillras et al., The impact of alveolar bone grafting on cleft lip and palate: a literature review. *South Eur J Orthod Dentofac Res.* 2014 Sep 22;1(1):19–22.

Hammoudeh JA, Fahradyan A, Gould DJ, Liang F, Imahiyerobo T, Urbinelli L, et al. A comparative analysis of recombinant human bone morphogenetic protein-2 with a demineralized bone matrix versus iliac crest bone graft for secondary alveolar bone grafts in patients with cleft lip and palate: review of 501 cases. *Plast Reconstr Surg.* 2017

Aug;140(2):318e–25e.

Hudak KA, Hettinger P, Denny AD. Cranial bone grafting for alveolar clefts: a 25-year review of outcomes. *Plast Reconstr Surg*. 2014 May;133(5):662e–8e.

Hynes PJ, Earley MJ. Assessment of secondary alveolar bone grafting using a modification of the Bergland grading system. *Br J Plast Surg*. 2003 Oct;56(7):630–6.

Kaura AS, Srinivasa DR, Kasten SJ. Optimal timing of alveolar cleft bone grafting for maxillary clefts in the cleft palate population. *J Craniofac Surg*. 2018 Sep;29(6):1551–7.

Liang F, Leland H, Jedrzejewski B, Auslander A, Maniskas S, Swanson J, et al. Alternatives to autologous bone graft in alveolar cleft reconstruction: the state of alveolar tissue engineering. *J Craniofac Surg*. 2018 May;29(3):584–93.

Lilja J, Kalaaji A, Friede H, Elander A. Combined bone grafting and delayed closure of the hard palate in patients with unilateral cleft lip and palate: facilitation of lateral incisor eruption and evaluation of indicators for timing of the procedure. *Cleft Palate-Craniofac J*. 2000 Jan;37(1):98–105.

Mathew P, Varun Menon P. Cortical bone graft and gtr membrane as “ceiling effect” in alveolar bone grafting. *J Maxillofac Oral Surg*. 2018 Jun;17(2):260–3.

Mikoya T, Inoue N, Matsuzawa Y, Totsuka Y, Kajii TS, Hirosawa T. Monocortical mandibular bone grafting for reconstruction of alveolar cleft. *Cleft Palate-Craniofacial J* 2010 Sep;47(5):454–68.

Montoya P, Bigorre M, Captier G, Baylon H, Pietrera J, Delestan C, et al. Prise en charge des fentes labio-maxillo-palatines au centre hospitalier universitaire de Montpellier. *Ann Chir Plast Esthét*. 2002 Apr;47(2):143–9.

Mossey PA, Little J, Munger RG, Dixon MJ, Shaw WC. Cleft lip and palate. *Lancet Lond*

Engl. 2009 Nov 21;374(9703):1773–85.

Newlands LC. Secondary alveolar bone grafting in cleft lip and palate patients. *Br J Oral Maxillofac Surg.* 2000 Oct;38(5):488–91.

Ouaki J, Dadure C, Bringuier S, Raux O, Rochette A, Captier G, et al. Continuous infusion of ropivacaine: an optimal postoperative analgesia regimen for iliac crest bone graft in children. *Paediatr Anaesth.* 2009 Sep;19(9):887–91.

Pessoa EAM, Braune A, Casado PL, Tannure PN. Alveolar bone graft: clinical profile and risk factors for complications in oral cleft patients. *Cleft Palate-Craniofac J.* 2017;54(5):530–4.

Precious DS. A new reliable method for alveolar bone grafting at about 6 years of age. *J Oral Maxillofac Surg.* 2009 Oct;67(10):2045–53.

Shirani G, Abbasi AJ, Mohebbi SZ. Need for revision surgery after alveolar cleft repair. *J Craniofac Surg.* 2012 Mar;23(2):378–81.

Vura N, Reddy K R, R S, G R, Kaluvala VR. Donor site evaluation: anterior iliac crest following secondary alveolar bone grafting. *J Clin Diagn Res.* 2013 Nov;7(11):2627–30.

Wheeler J, Sanders M, Loo S, Moaveni Z, Bartlett G, Keall H, et al. Iliac crest donor site for children with cleft lip and palate undergoing alveolar bone grafting: a long-term assessment. *J Craniofac Surg.* 2016 May;27(3):598–601.

Witherow H, Cox S, Jones E, Carr R, Waterhouse N. A new scale to assess radiographic success of secondary alveolar bone grafts. *Cleft Palate-Craniofac J.* 2002 May;39(3):255–60

Zhou W-N, Pan Y-C, Tang Y-C, Hou W, Wu D-M, Yuan H, et al. Comparative outcomes of block and cancellous iliac bone grafting in older unilateral alveolar cleft patients. *Cleft Palate-Craniofac J.* 2019 Jan 8;1055665618822410.

Table 1. Comparison of the clinical and demographic data in groups A and B

	AGE	SEX		DIAGNOSIS		TYPE OF CLEFT	
	at graft	Boys	Girls	Alveolar cleft	Cleft lip and palate	Unilateral	Bilateral
GROUP A	13.12 ± 7.34 years	104	59	16	147	99	64
GROUP B	20.1 ± 5.35 years	100	56	33	123	102	54
	P=0.0001 (Mann Whitney test)	P=0.65		P=0.01 (Chi2 test)		P=0.65	

Table 2. Surgery outcome in the two groups

	GROUP A (n=163)	GROUP B (n=156)	P value
No complication, n (%)	116 (71%)	120 (77%)	P=0.52
Minor complications, n (%)	34 (21%)	27 (17%)	
Major complications, n (%)	13 (8%)	9 (6%)	

Table 3. Results of the multilevel mixed-effect ordinal logistic regression analysis

	aOR	95% CI	<i>p</i>
Sex			
Female	0.56	0.13-2.36	0.43
Male	1.00		
Age			
>16 years	4.11	0.33-51.44	0.20
14 to 16 years	0.96	0.11-8.18	0.96
10 to 13 years	1.04	0.12-8.93	0.97
7 to 9 years	1.39	0.23-8.35	0.71
<7 years	1.00		
Cortical bone graft			
Yes	1.64	0.39-6.89	0.50
No	1.00		
Side			
Left	0.80	0.29-2.18	0.66
Right	1.00		

aOR, adjusted odds ratio; CI, confidence interval.

Figure 1. Photograph showing the cortical graft set up at nasal floor level. (Photograph courtesy of G. Captier.)

Figure 2. Photograph showing the cancellous bone packed in the cleft under the cortical graft. (Photograph courtesy of G. Captier.)

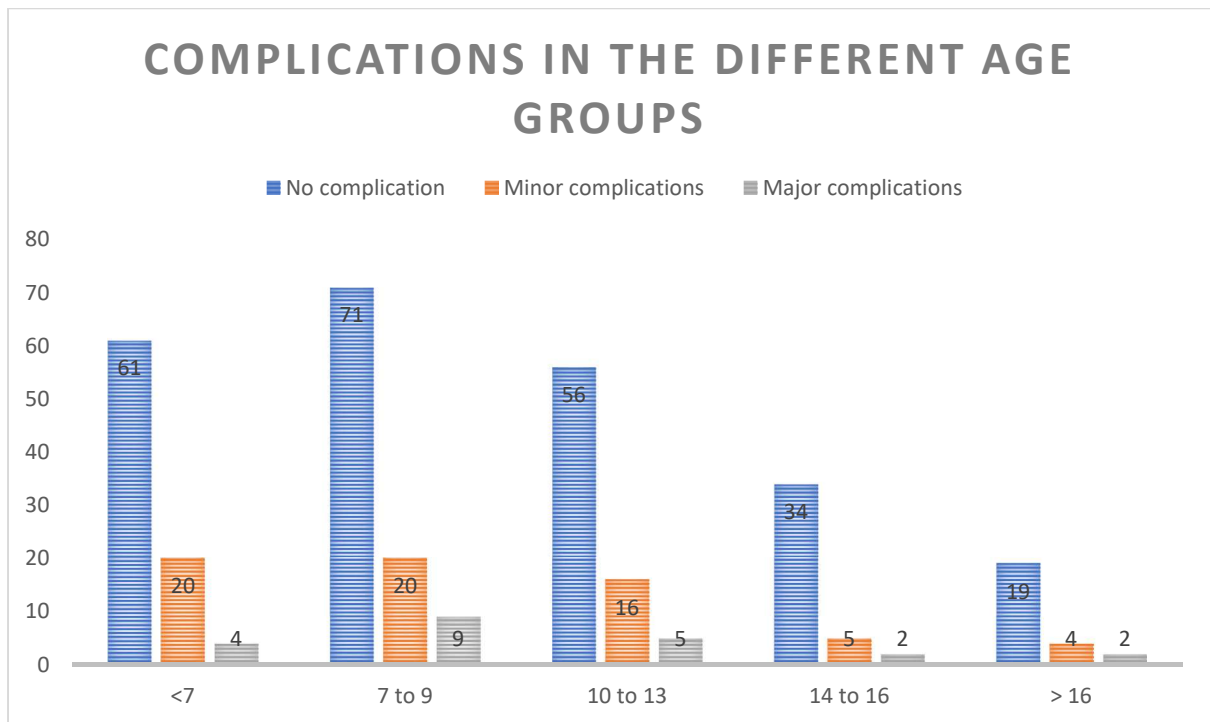


Figure 3. Histogram showing the distribution of complications in the different age groups.

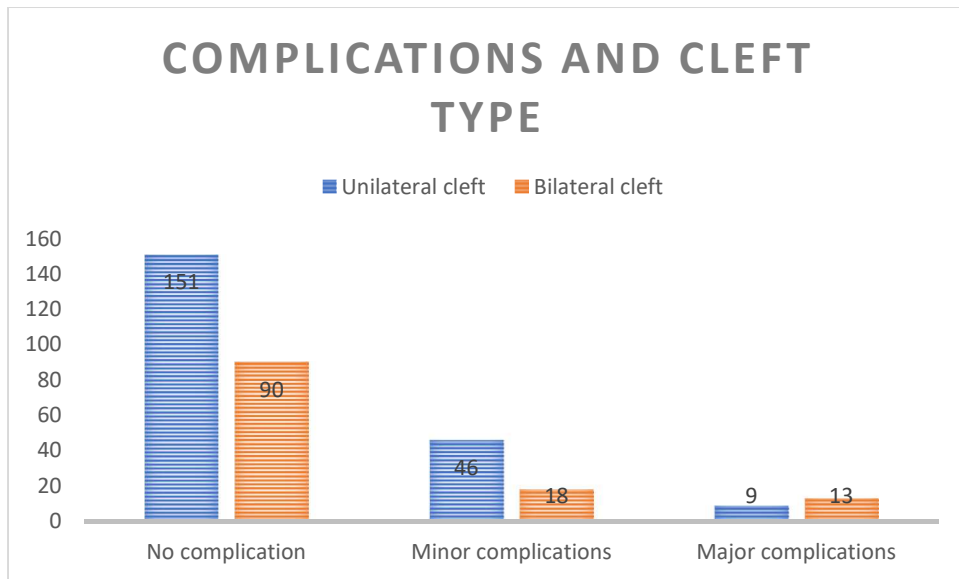


Figure 4. Histogram showing the number of complications in function of the cleft type (unilateral or bilateral).

Figures

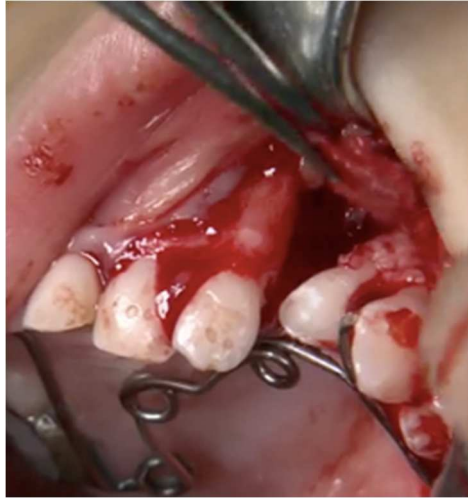

Figure 1: Picture showing the cortical graft set up at nasal floor level. Photo courtesy of G. Captier

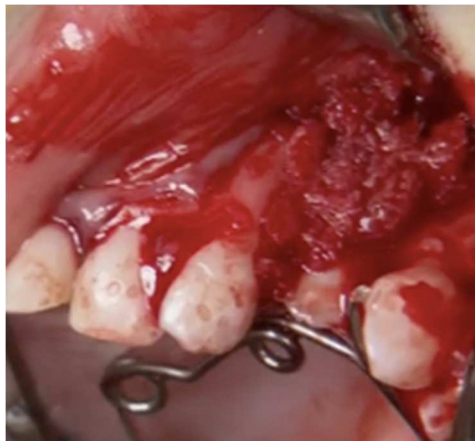

Figure 2: Picture showing the cancellous bone packed in the cleft under the cortical graft. Photo courtesy of G. Captier

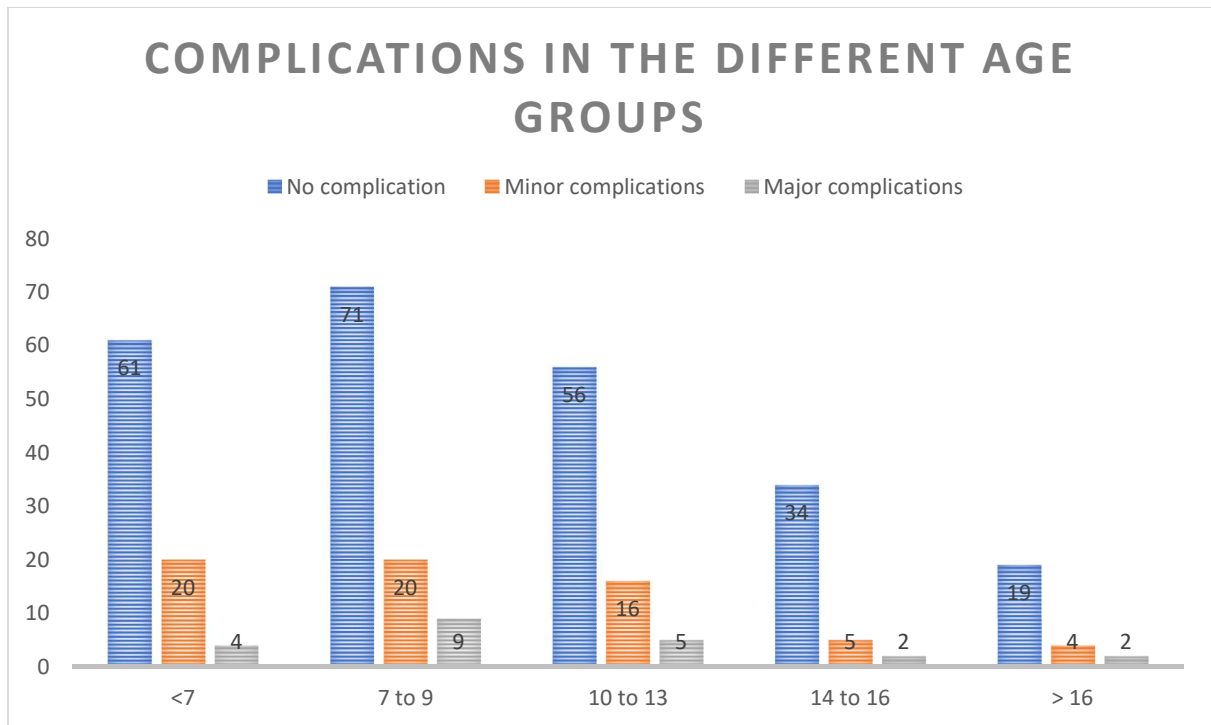


Figure 3: Histogram showing the distribution of complications in the different age groups