



HAL
open science

Imaging strategies for patients with suspicion of uncomplicated colic pain: diagnostic accuracy and management assessment

Claire Faget, Ingrid Millet, Mustapha Sebbane, Rodolphe Thuret, Cécile Verheyden, Fernanda Curros-Doyon, Nicolas Molinari, Patrice Taourel

► To cite this version:

Claire Faget, Ingrid Millet, Mustapha Sebbane, Rodolphe Thuret, Cécile Verheyden, et al.. Imaging strategies for patients with suspicion of uncomplicated colic pain: diagnostic accuracy and management assessment. *European Radiology*, 2021, 31 (5), pp.2983-2993. 10.1007/s00330-020-07264-z . hal-03342819

HAL Id: hal-03342819

<https://hal.umontpellier.fr/hal-03342819>

Submitted on 22 Jun 2023

HAL is a multi-disciplinary open access archive for the deposit and dissemination of scientific research documents, whether they are published or not. The documents may come from teaching and research institutions in France or abroad, or from public or private research centers.

L'archive ouverte pluridisciplinaire **HAL**, est destinée au dépôt et à la diffusion de documents scientifiques de niveau recherche, publiés ou non, émanant des établissements d'enseignement et de recherche français ou étrangers, des laboratoires publics ou privés.

Imaging strategies for patients with suspicion of uncomplicated colic pain: diagnostic accuracy and management assessment

Claire Faget¹ & Ingrid Millet¹ & Mustapha Sebbane² & Rodolphe Thuret³ & Cécile Verheyden¹ & Fernanda Curros-Doyon¹ & Nicolas Molinari⁴ & Patrice Taourel¹

* Patrice Taourel p-taourel@chu-montpellier.fr

1 Department of Medical Imaging, Montpellier University Hospital, Lapeyronie Hospital, 191, Avenue du Doyen Gaston Giraud, 34295 Montpellier Cedex 5, France

2 Department of Emergency, Montpellier University Hospital, Lapeyronie Hospital, Montpellier, France

3 Department of Urology and Renal Transplantation, Montpellier University Hospital, Lapeyronie Hospital, Montpellier, France

4 Department of Biostatistics and Medical Information, Montpellier University Hospital, Lapeyronie Hospital, Montpellier, France

Abbreviations

AD Alternative diagnosis; APF Abdominal plain film; Se Sensitivity; Spe Specificity; URCU Uncomplicated renal colic due to urolithiasis

Key Points

- For diagnosis, the use of APF + US as first-line imaging, with CT restricted to patients with both a normal APF + US and a STONE score ≥ 10 , provides both a sensitivity and specificity superior or equal to 95% and reduces the number of CT scans necessary by fourfold.
- For management, the use of APF + US as first-line imaging, with CT restricted to patients with both a normal APF + US and a STONE score ≥ 10 , maintains a 84% stone identification rate in urology-treated patients.

Keywords

Renal colic . Diagnostic imaging . Ultrasonography

Abstract

Objective

Compare different imaging scenarios in the diagnosis of uncomplicated renal colic due to urolithiasis (URCU).

Materials and methods

A total of 206 prospectively included patients had been admitted with suspected URCU and had undergone abdominal plain film (APF), US and unenhanced CT after clinical STONE score evaluation. CT was the reference standard. We assessed sensitivity (Se), specificity (Spe) and Youden index for colic pain diagnosis, percentage of patients managed by urologic treatment with stone identified, percentage of alternative diagnoses (AD) and exposure to radiation, according to single imaging approaches, strategies driven by patient characteristics and conditional imaging strategies after APF and US.

Results

One hundred (48.5%) patients had a final diagnosis of URCU and 19 underwent urologic treatment. The conditional strategy, i.e. CT in patients who had no stone identified at US, had a perfect sensitivity and specificity. This enabled diagnosis of all stones requiring urology management while decreasing the number of CT exams by 22%. The strategy whereby CT was used when there was neither direct or indirect APF + US finding of colic pain nor alternative diagnoses in patients with a STONE score ≥ 10 had a sensitivity of 0.95 and a specificity of 0.99, identified 84% of stones managed by urologic treatment and decreased the number of CT examinations by 76%.

Conclusion

In patients with clinical findings consistent with URCU, the use of ultrasound as first-line imaging modality, with CT restricted to patients with negative US and a STONE score ≥ 10 , led to a sensitivity and specificity of above 95%, identified 84% of stones requiring urological management and reduced the number of CT scans needed by fourfold.

--

Introduction

Suspicion of renal colic pain accounts for about 1% of hospital emergency department visits [1]. Since the landmark article by Smith et al [2], non-contrast-enhanced CT has emerged as an accurate and widely used imaging test for patients presenting with renal colic pain, while the American College of Radiology [3] also recommends this modality for imaging acute flank pain or suspected kidney stone disease. CT imaging in urolithiasis patients was more than tripled between 1992 and 2009 in the USA [1] yet without a concomitant increase in kidney stone diagnoses, substantial alternative diagnoses or hospitalisation of kidney stone patients [4]. Moreover, abdominal CT is associated with increased emergency department

length of stay, as well as a high rate of incidental findings that could lead to inappropriate referral and treatment [5, 6], while also boosting annual acute nephrolithiasis care costs. Lastly, as abdominal CT entails radiation exposure, there is an associated cancer risk, which could be mitigated by substantially reducing the radiation dose through the use of low-dose CT protocol as first-line imaging tool. Indeed it has been shown that the latter protocol could replace normal-dose CT for screening patients with suspected renal colic and a BMI < 30 [7]. CT has a much higher sensitivity (Se) than US [8, 9], particularly when imaging patients with a high body mass index, but US is preferred for patients at risk of complications from ionising radiation (pregnant or paediatric patients). Moreover, in a multicentre randomised trial comparing US performed by an emergency physician, US performed by a radiologist and abdominal CT in patients with suspected nephrolithiasis, there were no significant differences in missed serious diagnoses or adverse events. The authors concluded that US should be used for initial diagnostic imaging, while leaving the physician to then decide on whether further imaging studies would be warranted based on the clinical findings [10]. The STONE score is a simple reproducible marker that theoretically helps reliably predict the presence of ureteral stones (see Table 1) [11]. However, the STONE score cannot be used alone to definitively rule on the presence or absence of stones or exclude clinically important diagnoses, so its role for imaging decisions remains inconclusive [12, 13]. Furthermore, from a management perspective, the real clinical concern is not only to determine whether ureteral stones are present or absent but more importantly to identify the stone size, location and composition in order to assess whether these patients would require urological care beyond pain management [14].

In 2017, the European Urological guidelines recommended US as the primary diagnostic imaging tool while considering APF helpful for differentiating radiolucent and radiopaque stones [15]. By contrast, in 2016, the American College of Radiology recommended low-dose non-contrast CT as a first-line imaging modality but considered that APF combined with ultrasonography could provide an acceptable alternative to the latter modality for some patients [16]. Urological and radiological guidelines are not dependent on the STONE score assessment tool.

The aim of our study was to evaluate the accuracy of various imaging strategies based on the STONE score and biometric data in patients suspected of URCU.

Methods

Study design and setting

The study was approved by the Institutional Review Board, i.e. the Comité de Protection des personnes Sud méditerranée V (Registry Identifier: ID-RCB 2015-A01981-48, reference 16.013), and was registered on clinicaltrials.gov before enrolment (NCT NCT02878148). Written informed consent for the protocol was obtained from all patients before imaging, and health insurance portability and accountability act authorisation was provided. This prospective, monocentric interventional study was performed at an urban academic tertiary care centre with about 70,000 yearly adult emergency department visits for non-neurological symptoms.

Table 1 Renal colic diagnosis—the STONE score [11]

Factor	Points
Sex	
Female	0
Male	1
Duration of pain	
> 24 h	0
6–24 h	1
< 6 h	3
Race	
Black	0
Non-black	3
Nausea and vomiting	
None	0
Nausea alone	1
Vomiting alone	2
Haematuria (on urine dipstick)	
Absent	0
Present	3
Total	0–13
STONE score	
Low	0–5
Moderate	6–9
High	10–13

Patients

Adult patients (over 18 years old) with acute renal colic pain suspected by the emergency department physician were eligible. Patients were included in the study 7 days a week. Patients were excluded if they had a history or evidence of fever, leukocytes in the urine or known renal disease (creatinine > 1.5 mg/dL, renal transplant, single functional kidney, known active renal disease) since CT has been recommended if a complicated case is suspected (signs of infection, anuria) or in special situations (single kidney, transplanted kidney, known uropathy or renal failure) [17]. Pregnant patients and patients with a history of renal stone disease were also excluded because ultrasound must be used as the first-line modality in pregnant women [18], and CT should be overruled in patients with prior kidney stones [19]. Eligible patients were risk stratified for likelihood of ureteral stones using the STONE score [11, 18], while BMI was recorded for every patient to differentiate obese patients (BMI \geq 30 kg/m²) from non-obese patients (BMI < 30 kg/m²).

Examinations and image analysis

All patients underwent US, APF and CT. Imaging exams were performed within a 1-h timeframe.

Five senior radiologists with 5–15 years of abdominal ultrasound experience conducted the US exams with an Aplio 500 scanner (Canon Medical System) using a 3.5- or 6-MHz convex probe. They looked for direct and indirect findings of ureteral stones. A direct finding was the identification of a stone in B mode in the ureter from the renal pelvis to the ureterovesical junction. Indirect findings included hydronephrosis and fat infiltration around the kidney. Doppler findings such as asymmetry or absence of ureteric jet, an increased resistive index or a colour Doppler twinkling artefact were not considered in the US interpretation. US and abdominal plain film (APF) were jointly interpreted. The diagnosis of URCU was based on direct visualisation of proximal or distal ureteral calculi by APF and/ or US, as well as on the detection of indirect findings by US (hydronephrosis and/or fat infiltration around the kidney) provided that the indirect or direct findings were located on the side where the patient was presenting pain.

Non-contrast-enhanced CT scans were performed on a 64- section CT scanner (Light speed; GE Healthcare) with automated tube current. CT images were acquired from the top of the diaphragm to the mid part of the symphysis pubis. A reduced-dose renal protocol was performed in patients with a BMI < 30, with the tube current set at 50–100mA and with a tube voltage of 80 kV from the diaphragm to the iliac crest and 100 kV from the iliac crest to the symphysis pubis, in accordance with the previously published threshold for reduced- or low-dose CT [19, 20]. The noise index was 35. A 60% iterative reconstruction algorithm blended with filtered back projection was selected on a 10–100% strength scale (adaptive statistical iterative reconstruction, GE Healthcare). Axial images of 1.25- and 3-mm section thickness and coronal and sagittal images of 3-mm thickness were reconstructed. The high-BMI protocol was used between 50 and 150 mA, with a tube voltage of 100 kV from the diaphragm through the pelvis. CT scans were interpreted by one of the five senior radiologists involved in the study, with diagnosis based on indirect findings of renal colic pain only when hydronephrosis or asymmetric fat stranding around the kidney was detected, whereas diagnosis was based on direct findings when a stone was identified within the ureter. The presence of a calyceal stone was not considered indicative of URCU.

The combined APF/US and the CT scans were prospectively read by a different radiologist among the radiologists involved in the study, in real time, without disclosure of any results from the other investigations, and readers were also unaware of any clinical information, including the STONE score.

Outcome measures

The results of the prospective interpretation of CT (which was performed upon the presence of direct and/or indirect findings) were considered as the reference standard in the diagnosis of URCU. Moreover, decisions to perform urological treatment, including lithotripsy, ureteral stenting or surgical stone removal, were made on an individual basis according to the clinical symptoms, progress under medical treatment and the CT-revealed stone location, size and density.

All included patients were contacted for a 90-day phone follow-up survey to determine whether they had undergone a urological intervention following the CT examinations and to know if they had experienced a recurrence of colic pain in the prior 3 months.

A consensus diagnostic assessment of an eventual alternative diagnosis was performed by one emergency physician and one radiologist at the end of the 90-day follow-up period based on the phone-collected data and on the review of the patients' medical records, including the imaging test results. An alternative diagnosis was considered when a non-stone cause could explain the symptoms [20]; the conditions which required patient admission were differentiated from conditions which did not. An acute alternative diagnosis was defined as a condition requiring patient admission and treatment within 24 h.

Diagnostic strategies

The following strategies were assessed by comparison with a reference strategy whereby CT was performed in all patients:

(1) strategy, as summarised in the Table 2. An imaging test was considered negative when there were no direct or indirect findings of colic pain due to urolithiasis, nor an alternative diagnosis.

Single imaging strategy:

(2) APF and US in all patients.

Imaging strategies based on patient characteristics:

(3) STONE score assessment, CT performed in patients with STONE score < 10 and no imaging if STONE score ≥ 10 , assuming that patients have renal colic diagnosis [11].

(4) STONE score assessment, with CT performed in patients with STONE score < 10 and APF and US if score ≥ 10 .

(5) BMI score assessment, with CT performed in patients with BMI ≥ 30 and APF and US if BMI < 30 .

Imaging strategies based on systematic use of APF and US with conditional use of CT according to the APF + US results:

(6) APF and US in all patients and CT performed in patients with negative APF and US.

(7) APF and US in all patients and CT performed in patients without identification of a stone or an alternative diagnosis.

Imaging strategies based on systematic use of APF and US, with conditional use of CT according to the APF and US results and to the patient characteristics, in keeping with the recommendations in the NEJM article [9]:

(8) APF and US in all patients and CT performed in patients with negative APF and US and STONE score ≥ 10 .

(9) APF and US in all patients and CT performed in patients with negative APF and US and BMI ≥ 30 .

Finally, as a mixed scenario driven by both the STONE score and BMI:

(10) CT performed in patients with BMI ≥ 30 and APF and US performed if BMI < 30 and in that event CT performed in patients with negative APF and US and STONE score ≥ 10 .

Table 2 Summary of the assessed strategies

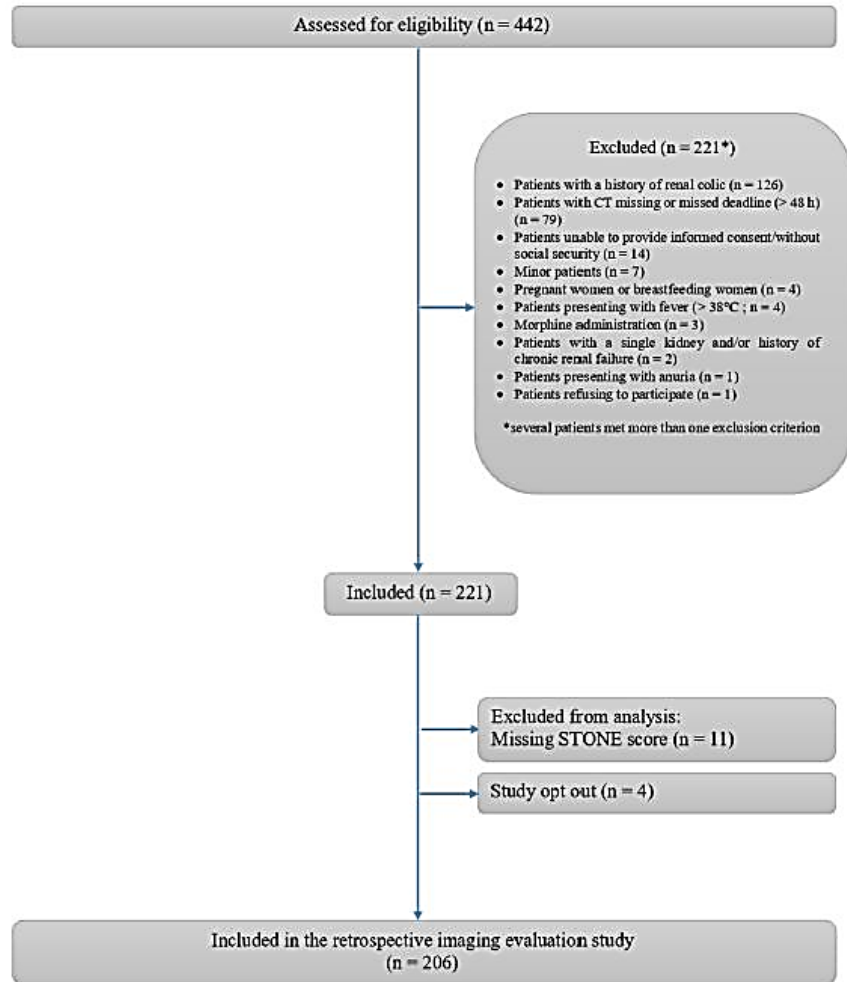
	APF and US	CT	No imaging
Strategy 1	0	All patients	0
Strategy 2	All patients	0	0
Strategy 3	0	STONE score < 10	STONE \geq 10
Strategy 4	STONE score \geq 10	STONE score < 10	0
Strategy 5	BMI < 30	BMI \geq 30	0
Strategy 6	All patients	APF and US negative	0
Strategy 7	All patients	No APF or US identification of urolithiasis and no alternative diagnosis	0
Strategy 8	All patients	APF and US negative And STONE score \geq 10	0
Strategy 9	All patients	APF and US negative And BMI > 30	0
Strategy 10	BMI \leq 30	BMI > 30 or BMI \leq 30 and APF + US negative and STONE score \geq 10	0

Data analysis

The sensitivity and specificity (Spe) (and their 95% confidence intervals) in diagnosing URCU (direct or indirect findings) were calculated for each of the 9 diagnostic strategies (strategies 2–10) by comparing the results of each strategy with the reference diagnosis (strategy 1). The percentage of patients who had undergone US and the percentage who had been exposed to CT-related ionising radiation were calculated for each strategy, as well as the number of alternative diagnoses requiring hospitalisation or not for each strategy. Finally, the number of cases in which a stone was accurately identified in patients who required urological treatment was calculated for each strategy. The stability of the strategies was investigated by computing the sensitivity and specificity on 1000 bootstrapped samples and the diagnostic specificities of all strategies were plotted in a receiver operating characteristic (ROC) space.

The CT radiation doses were estimated using the mean normalised values of the effective dose per dose length product (DLP) for the abdomen. The mean DLP value was calculated from the DLP values indicated on each examination. CT effective doses were calculated by multiplying the DLP of each examination by a conversion factor of 0.0153 mSv mGy⁻¹ cm⁻¹ designed for 120 kV abdominal acquisitions [24]. Similarly, plain film effective doses were derived from the DAP of each examination, using conversion factors of 0.17 mSv Gy⁻¹ cm⁻² and 0.22 mSv Gy⁻¹ cm⁻² for APF acquired at 70 kV and 90 kV, respectively [25].

Fig. 1 Flow chart of patients in a study in which different imaging strategies were assessed for colic pain diagnosis



Results

Population

A total of 442 patients were admitted to the emergency department for suspicion of colic pain between October 2016 and January 2018. Two hundred twenty-one met the inclusion criteria and were prospectively enrolled, but 15 of them were subsequently excluded. The study population thus consisted of 206 patients (Fig. 1).

The mean patient age was 40 ± 16 (range 18–84) years; 43% (n = 88) were female, while 57% (n = 118) were male.

The STONE score was under 10 in 104 patients and higher or equal to 10 in 102 patients. The negative predictive value of a STONE score of less than 10 was 74%, while the positive predictive value of a STONE score higher or equal to 10 was 72%. Figure 2 shows the STONE score distribution within our population and the likelihood of URCU according to the STONE score.

The mean BMI was 24.6 kg/m² (\pm 4.3) and 26 patients (13%) had a BMI higher than or equal to 30.

The mean estimated effective doses for CT were 5.1 \pm 2.4 mSv for CT and 0.35 \pm 0.38 for APF.

Reference standard and management

The CT scans revealed a ureteral stone in 88 patients (43%), indirect findings without stone identification in 12 patients (6%) and no findings of colic pain in 106 patients (51%). The mean stone size measured by CT was 3.7 \pm 1.6 mm in its maximal transverse diameter. The stone was located in the renal pelvis in 3 patients, in the upper ureter in 12 patients, in the mid-ureter in 8 patients, in the lower ureter in 18 patients and at the ureterovesical junction in 47 patients.

Nineteen patients (9%) had undergone urological treatment, including ureteroscopy-guided stone extraction in 5 patients, extracorporeal shock wave lithotripsy (ESWL) in 11 patients and a combination of ureteroscopy-guided stone extraction and ESWL in 3 patients. CT revealed a stone in all of these patients. The mean CT-measured size of stones managed by urological treatment was 5 \pm 1.9 mm. The stone was located in the renal pelvis in 1 patient, in the upper ureter in 8 patients, in the mid-ureter in 3 patients, in the pelvic ureter in 4 patients and at the ureterovesical junction in 3 patients. Patients were treated after a mean time of 4 \pm 8 days (0.3–30 days) from imaging.

In the 106 patients without diagnosis of URCU, an alternative diagnosis was reported in 6 patients, including pleural effusion (1), cystitis (1), ovarian cyst (2), epiploic appendagitis torsion (1) and diverticulitis (1). In this group, no patients were hospitalised and none had a recurrence of abdominal pain within 3 months.

Diagnostic performance of the different strategies

Table 3 shows the accuracy results for each strategy and Fig. 3 shows these results plotted in a ROC space. The strategy based on a single US imaging strategy for all patients (strategy 2) had the lowest sensitivity (0.74). This strategy revealed a direct finding in 44 of the 88 patients (50%). There was no false positive identification of a stone when the APF + US and CT data were correlated. Binary strategies with either APF + US or CT according to the STONE score or to the BMI index had under 0.8 sensitivity (strategies 4 and 5). Strategy 3 revealed renal colic pain and had a specificity of under 0.8.

Among the strategies with both a sensitivity and specificity \geq 0.95 (strategies 1, 6, 7, 8 and 10), those with US performed first in all patients and CT performed when APF and US were negative had the best sensitivity and specificity, with the highest Youden index (strategies 6 and 7). However, these strategies decreased the number of CT exams carried out by 38% and 23%, respectively. By introducing the STONE score to select patients eligible for CT after a negative APF + US (strategy 8), the sensitivity and Youden index were decreased by 0.05, while leading to a 76% decrease in the number of CT examinations. Modifying this strategy (strategy 10) by prior CT performance in obese patients did not change the sensitivity, specificity and Youden index, but led to the identification of one supplementary stone—this

additional patient with an identified ureteric stone did not require urologic treatment. Otherwise, using a BMI index to select patients eligible for CT after a negative APF + US (strategy 9) decreased the sensitivity and Youden index to below 0.8.

For both strategies with a Youden index of 0.941 (8 and 10), the bootstrapped sensitivity and specificity estimations were 0.949 (0.903 to 0.979) and 0.990 (0.969 to 1), respectively.

Performances of the different strategies for identifying urology-treated stones

The only strategy (strategy 7) that revealed all urology-treated stones involved performing CT in all patients for whom a direct finding was not identified at APF + US. This led to a 22% decrease in the number of CT exams. Other strategies (strategies 8 and 10) with high sensitivity and specificity directly showed a stone in 16 cases (84%) among the 19 patients under urological care, with direct and/or indirect findings of colic pain in 18 of these patients (95%).

Discussion

In the diagnosis of patients with renal colic pain, we documented that first-line use of APF and US and conditional use of CT, performed only when APF and US were negative and the STONE score was ≥ 10 , had a sensitivity and specificity of 95% and 99%, respectively, with a Youden index of over 0.9. This strategy reduced the number of CT scans necessary by fourfold. These are very promising results since evidence is needed to guide CT imaging in patients with acute flank pain, which—as pointed out by a panel of experts—is a very high priority clinical issue to be considered when drawing up decision rules [21]. It is essential to be able to identify patients who would benefit from CT imaging and those who would not [22], particularly for such a common disease affecting young population.

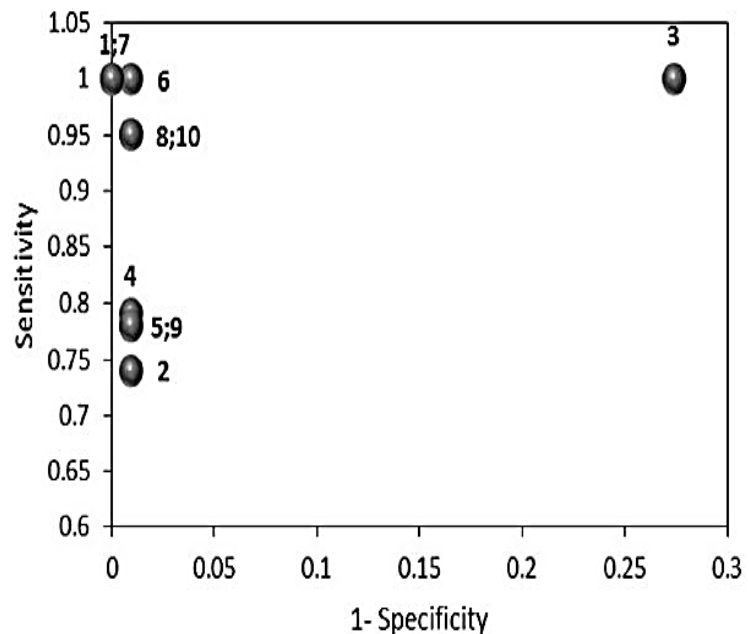
Our results confirmed the findings of an NEJM study [23] which concluded that US should be used as the initial diagnostic imaging test for a first renal colic episode, with CT only performed if the clinical physician feels it would be warranted. In our strategy, the STONE score supplants the physician's individual clinical judgement. We did not use the score as outlined in the original STONE score publication [24], where it was suggested that patients with a high STONE score should be considered as having a ureteral stone and managed accordingly without further CT scan assessment, since other studies focused on external validation of the STONE score found that a high STONE score did not have a sufficiently high specificity to defer CT scan without imaging [25]. In line with the latter findings, we obtained a 72% positive predictive value for a STONE score ≥ 10 for the diagnosis of URCU, which was lower than the 89% obtained in the original study [26]. The strategy whereby CT is conducted in patients with a STONE score < 10 with colic pain diagnosed if the STONE score ≥ 10 would lead to a specificity of 0.726 and thus only reduce the number of CT exams conducted by twofold, with a stone directly identified only in 6 of the 19 cases requiring urologic treatment.

Table 3 Diagnostic performances calculated according to the tested conditional strategies. Se, sensitivity; Sp, specificity; AD, alternative diagnosis

N°	Imaging strategies	Se	Spe	Youden index	Urteral stone identified	AD	Patients with urological care	Se* Patients with urological care	US use	CT use
1	CT scan (gold standard)	1 [0.956 to 1]	1 [0.956 to 1]	1	88 (100%)	6 (100%)	19 (100%)	1 [0.954 to 1]	0	206
2	Abdominal X-ray/US	0.740 [0.641 to 820]	0.991 [0.941 to 0.999]	0.731	44 (50%)	2 (39%)	13 (68%)	0.789 [0.539 to 0.930]	206	0
3	STONE score < 10 → CT scan (STONE scores ≥ 10 are considered with colic pain)	1 [0.954 to 1]	0.726 [0.630 to 0.806]	0.726	21 (24%)	6 (100%)	6 (32%)	1 [0.954 to 1]	0	104
4	STONE score < 10 → CT scan	0.790 [0.695 to 0.862]	0.991 [0.941 to 0.999]	0.781	54 (61%)	6 (100%)	14 (74%)	0.842 [0.595 to 0.958]	102	104
5	STONE score ≥ 10 → Abdominal X-ray/US	0.780 [0.681 to 0.854]	0.991 [0.941 to 0.999]	0.771	48 (55%)	3 (50%)	13 (68%)	0.789 [0.539 to 0.930]	180	26
6	Abdominal X-ray and US IF negative results (no urteral stone, no indirect signs of urolithiasis no AD)	1 [0.954 to 1]	0.991 [0.954 to 0.999]	0.991	60 (68%)	6 (100%)	14 (74%)	1 [0.954 to 1]	206	127
7	Abdominal X-ray and US IF results negative (no urteral stone, no AD)	1 [0.954 to 1]	1 [0.956 to 1]	1	88 (100%)	6 (100%)	19 (100%)	1 [0.954 to 1]	206	158
8	Abdominal X-ray/US IF negative results and STONE score ≥ 10	0.950 [0.882 to 0.981]	0.991 [0.941 to 0.999]	0.941	61 (69%)	2 (33%)	16 (84%)	0.947 [0.710 to 0.997]	206	49
9	Abdominal X-ray/US IF negative results and BMI ≥ 30	0.780 [0.684 to 0.854]	0.991 [0.941 to 0.999]	0.771	47 (53%)	3 (50%)	13 (68%)	0.789 [0.539 to 0.930]	206	15
10	BMI ≥ 30 → CT scan	0.95 [0.882 to 0.981]	0.991 [0.941 to 0.999]	0.941	62 (70%)	3 (50%)	16 (84%)	0.947 [0.710 to 0.997]	180	66
	BMI < 30 → Abdominal X-ray/US IF negative results and STONE score ≥ 10 → CT scan									

*Sensitivity in the group of patients treated by urology

Fig. 3 Diagnostic performance of all imaging strategies presented in a receiver operating characteristic (ROC) space. Numbers correspond to strategies



In patients with suspicion of colic pain, being able to identify the stone size, location and composition is clinically essential in order to assess whether they would require urologic care beyond pain management and to predict the spontaneous passage rate, which mainly depends on the ureteral stone width and location [27]. Our analysis of colic pain management revealed two different reliable strategies. First, the strategy whereby CT is performed when no stone has been detected jointly by APF and US enables the operator to visualise all stones, notably those which would require urological treatment. However, this only decreases the number of CTs by 22%. By contrast, the strategy whereby CT is only conducted in patients with a negative US and a STONE score ≥ 10 led to a 76% decrease in the number of CTs, while renal colic pain was diagnosed in 95% of patients who had undergone urological treatment, with a stone identified in 16/19 patients (84%). Although the theoretical risk of this strategy is renal function loss due to long-standing obstruction, it has been shown that non-obstructing asymptomatic ureteral stones seldom lead to silent hydronephrosis and rarely require intervention [28, 29]. Yet transient renal impairment in patients with unilateral ureteric stone is very rare in the absence of preexisting kidney disease and hydronephrosis [30]. We therefore consider that this strategy could be the first step in colic pain diagnosis and management. This strategy could be supported and supplemented by delayed CT within a week after symptom onset if the clinical signs persist, along with systematic follow-up US in patients presenting with indirect findings of renal colic in the first US assessment to screen for clinically asymptomatic hydronephrosis. Further studies are necessary to assess the accuracy, number of imaging exams and related cost-effectiveness required by this time-lag strategy.

The rationale for assessing different imaging strategies is to decrease X-ray exposure by comparison to a systematic CT strategy. Our mean effective dose with systematic CT was 5.1 mSv. Although this was considerably lower than the mean radiation dose of 11.2 mSv reported in a large-scale survey assessing the radiation dose index of the renal colic CT protocol in the USA [22], it was higher than the effective dose of 3 mSv or less considered as the threshold for low-dose CT. One explanation is likely not to have limited the scan coverage area from the upper pole of the kidneys to the base of the urinary bladder. Furthermore, lower CT radiation doses may be obtained by the ultra-low-dose protocols that have emerged as the

result of recent technical advances [31], but our CT unit was not equipped to implement such protocols. However, according to the linear no-threshold model of carcinogenic risk from radiation and in the light of the stochastic nature of radiation carcinogenesis, a very small radiation dose could theoretically produce DNA damage and result in oncogenic mutation [32]. Although this model is still controversial, the exact risk from low-dose CT is still quite uncertain and elimination of unnecessary CT examinations is the first step towards managing risk [33]. APF + US enabled us to identify 50% of the stones that had been identified via CT, and 68% of the stones treated by urological procedures. This is in line with the average reported in the literature, which shows a broad range of sensitivity, i.e. 24–96%, depending on the stone size and location and the reference examination used. Point-of-care US is focused on the presence of hydronephrosis [21] but fails to identify stones. We therefore think complete US is a preferable option as it decreases patient radiation exposure while generating good results in the management of patients with suspicion of renal colic pain. We included only 26 patients (13%) with a BMI \geq 30 and this low rate reflects the fact that the prevalence of obesity in our country is less than half the rate in the USA (www.oecd.org/health/obesity-update.htm). The accuracy of the scenario involving the systematic inclusion of CT in obese patients was not any better than that obtained without a specific strategy for these patients—this point is in contradiction with the lower US stone detection value when imaging obese patients, as previously reported [34]. However, the low number of obese patients in our population did not allow us to reliably assess the values of our different strategies in obese patients.

Our population was very representative of patients seen in an emergency department with suspicion of a first episode of uncomplicated renal colic pain, which suggests that our results could be broadly applied. Our colic pain– positive CT scan rate was 48.5%, which is in line with the 49.5% and 55.8% positive CT scan rates reported in the original STONE score study [12] in the derivation and validation cohorts, respectively. Interestingly, we found only 6 alternative diagnoses (3%) that explained symptoms in patients without renal colic pain, but none of these cases required treatment within 24 h. The largest prospective multicentric trial with patients randomised with regard to CT or US reported a very low high-risk alternative diagnosis rate (0.4%) [11]. Moreover, no dangerous alternative diagnoses were obtained in a study conducted in young patients (mean age 37 years) presenting with suspected uncomplicated renal colic [35], as in our study. So nonspecific abdominal pain would by far be the most likely diagnosis in patients with negative APF and US and a STONE score of under 10. We obtained a 9% urological intervention diagnosis rate, which perfectly matched the 9.8% rate reported in a large-scale national retrospective cohort that included more than 300,000 patients [36].

Our study had several limitations. As reference scenario, we opted for systematic use of CT and considered the CT results as the gold standard for renal colic pain diagnosis and stone identification. We consider that adopting a stringent stone diagnosis reference standard such as patient observation of a stone passage may lead to inaccurate assessment sensitivity and specificity since it is recognised that numerous stones spontaneously pass without the patient noticing. We did not use codified criteria for urological intervention and our urologists decided on urological intervention procedures and dates on an individual basis according to their clinical experience. Finally, our approach allowed comparison of imaging strategies but no direct evaluation of the effects of these strategies on patient management and outcome. In this study, management after completion of the diagnostic protocol was always based on the CT scan results, and these scans were performed in all patients.

In conclusion, the results of our study support the use of ultrasound as a first-line imaging modality in patients suspected of presenting with non-complicated renal colic pain. CT should be restricted to patients with both a normal US and a STONE score ≥ 10 . This strategy, which should now be prospectively validated in another group of patients, had a sensitivity and specificity of above 95%, while identifying 85% of stones requiring urological management and reducing the number of CT scans needed by fourfold. However, further studies are needed to determine if additional time-lag imaging could further decrease the risk linked to undiagnosed stones.

Funding

This study has received funding by Montpellier University Hospital Centre.

Compliance with ethical standards

Guarantor

The scientific guarantor of this publication is Pr. Patrice TAOUREL.

Conflict of interest

The authors of this manuscript declare no relationships with any companies whose products or services may be related to the subject matter of the article.

Statistics and biometry

One of the authors has significant statistical expertise.

Informed consent

Written informed consent was obtained from all subjects (patients) in this study.

Ethical approval

Institutional Review Board approval was obtained by the Institutional Review Board named "Comité de Protection des personnes Sud méditerranée V" (Registry Identifier: ID-RCB 2015- A01981-48, reference 16.013).

Methodology

- prospective
- diagnostic or prognostic study
- performed at one institution

References

1. Fwu CW, Eggers PW, Kimmel PL, Kusek JW, Kirkali Z (2013) Emergency department visits, use of imaging, and drugs for urolithiasis have increased in the United States. *Kidney Int* 83:479–486
2. Smith RC, Verga M, McCarthy S, Rosenfield AT (1996) Diagnosis of acute flank pain: value of unenhanced helical CT. *AJR Am J Roentgenol* 166:97–101
3. Coursey CA, Casalino DD, Remer EM et al (2012) ACR appropriateness criteria (R) acute onset flank pain—suspicion of stone disease. *Ultrasound Q* 28:227–233
4. Westphalen AC, Hsia RY, Maselli JH, Wang R, Gonzales R (2011) Radiological imaging of patients with suspected urinary tract stones: national trends, diagnoses, and predictors. *Acad Emerg Med* 18:699–707
5. Lumberras B, Donat L, Hernandez-Aguado I (2010) Incidental findings in imaging diagnostic tests: a systematic review. *Br J Radiol* 83:276–289
6. Chi T, Miller J, Stoller ML (2012) Randall plaque versus renal stone? *Transl Androl Urol* 1:66–70
7. Poletti PA, Platon A, Rutschmann OT, Schmidlin FR, Iselin CE, Becker CD (2007) Low-dose versus standard-dose CT protocol in patients with clinically suspected renal colic. *AJR Am J Roentgenol* 188:927–933
8. Fowler KA, Locken JA, Duchesne JH, Williamson MR (2002) US for detecting renal calculi with nonenhanced CT as a reference standard. *Radiology* 222:109–113
9. Catalano O, Nunziata A, Altei F, Siani A (2002) Suspected ureteral colic: primary helical CT versus selective helical CT after unenhanced radiography and sonography. *AJR Am J Roentgenol* 178:379–387
10. Smith-Bindman R, Aubin C, Bailitz J et al (2014) Ultrasonography versus computed tomography for suspected nephrolithiasis. *N Engl J Med* 371:1100–1110
11. Moore CL, Bomann S, Daniels B et al (2014) Derivation and validation of a clinical prediction rule for uncomplicated ureteral stone—the STONE score: retrospective and prospective observational cohort studies. *BMJ* 348:g2191
12. Wang RC, Rodriguez RM, Moghadassi M et al (2016) External validation of the STONE score, a clinical prediction rule for ureteral stone: an observational multi-institutional study. *Ann Emerg Med* 67:423–432.e422
13. Wang RC (2016) Managing Urolithiasis. *Ann Emerg Med* 67(4): 449–454
14. Green SM, Schriger DL (2016) The sinking STONE: what a failed validation can teach us about clinical decision rules. *Ann Emerg Med* 67:433–436

15. Turk C, Petrik A, Sarica K et al (2016) EAU guidelines on diagnosis and conservative management of urolithiasis. *Eur Urol* 69:468–474
16. Bredemeyer M (2016) ACR appropriateness criteria for acute onset of flank pain with suspicion of stone disease. *Am Fam Physician* 94:575–576
17. Daniels B, Gross CP, Molinaro A et al (2016) STONE PLUS: evaluation of emergency department patients with suspected renal colic, using a clinical prediction tool combined with point-of-care limited ultrasonography. *Ann Emerg Med* 67:439–448
18. Lukasiewicz A, Bhargavan-Chatfield M, Coombs L et al (2014) Radiation dose index of renal colic protocol CT studies in the United States: a report from the American College of Radiology National Radiology Data Registry. *Radiology* 271: 445–451
19. Finnerty NM, Rodriguez RM, Carpenter CR et al (2015) Clinical decision rules for diagnostic imaging in the emergency department: a research agenda. *Acad Emerg Med* 22:1406–1416
20. Jendeborg J, Geijer H, Alshamari M, Cierzniak B, Liden M (2017) Size matters: the width and location of a ureteral stone accurately predict the chance of spontaneous passage. *Eur Radiol* 27:4775–4785
21. Dropkin BM, Moses RA, Sharma D, Pais VMJr (2015) The natural history of nonobstructing asymptomatic renal stones managed with active surveillance. *J Urol* 193:1265–1269
22. Kim HY, Choe HS, Lee DS, Yoo JM, Lee SJ (2017) Transient renal impairment in the absence of pre-existing chronic kidney disease in patients with unilateral ureteric stone impaction. *Urolithiasis* 45: 249–254
23. den Harder AM, Willemink MJ, van Doormaal PJ et al (2018) Radiation dose reduction for CT assessment of urolithiasis using iterative reconstruction: a prospective intra-individual study. *Eur Radiol* 28:143–150
24. Albert JM (2013) Radiation risk from CT: implications for cancer screening. *AJR Am J Roentgenol* 201:W81–W87
25. Ferrero A, Takahashi N, Vrtiska TJ, Krambeck AE, Lieske JC, McCollough CH (2019) Understanding, justifying, and optimizing radiation exposure for CT imaging in nephrourology. *Nat Rev Urol* 16(4):231–244. <https://doi.org/10.1038/s41585-019-0148-8>
26. Nery DR, Costa YB, Mussi TC, Baroni RH (2018) Epidemiological and imaging features that can affect the detection of ureterolithiasis on ultrasound. *Radiol Bras* 51:287–292
27. Schoenfeld EM, Poronsky KE, Elia TR, Budhram GR, Garb JL, Mader TJ (2015) Young patients with suspected uncomplicated renal colic are unlikely to have dangerous alternative diagnoses or need emergent intervention. *West J Emerg Med* 16:269–275

28. Gervaise A, Gervaise-Henry C, Pernin M, Naulet P, Junca-Laplace C, Lapiere-Combes M (2016) How to perform low-dose computed tomography for renal colic in clinical practice. *Diagn Interv Imaging* 97(4):393–400
29. Masselli G, Derme M, Bernieri MG et al (2014) Stone disease in pregnancy: imaging-guided therapy. *Insights Imaging* 5:691–696
30. Moore CL, Carpenter CR, Heilbrun ML et al (2019) Imaging in suspected renal colic: systematic review of the literature and multispecialty consensus. *J Urol* 202(3):475–483
31. European Commission. European guidelines on quality criteria for computed tomography. Report EUR 16262. Brussels, Belgium: European Commission, 1999
32. (2007) The 2007 Recommendations of the International Commission on Radiological Protection. ICRP publication 103. *Ann ICRP* 37:1–332
33. Schoenfeld EM, Pekow PS, Shieh MS, Scales CD Jr, Lagu T, Lindenauer PK (2017) The diagnosis and management of patients with renal colic across a sample of US hospitals: high CT utilization despite low rates of admission and inpatient urologic intervention. *PLoS One* 12:e0169160
34. Thompson RJ, Wojcik SM, Grant WD, Ko PY (2011) Incidental findings on CT scans in the Emergency Department. *Emerg Med Int* 2011:1–4
35. Schoenfeld E, Poronsky K, Elia T, Budhram G, Garb J, Mader T (2015) Young patients with suspected uncomplicated renal colic are unlikely to have dangerous alternative diagnoses or need emergent intervention. *West J Emerg Med* 16(2):269–275
36. Schoenfeld EM, Pekow PS, Shieh MS, Scales CD, Lagu T, Lindenauer PK (2017) The Diagnosis and Management of Patients with Renal Colic across a Sample of US Hospitals: High CT Utilization Despite Low Rates of Admission and Inpatient Urologic Intervention. *PLoS One* 12 (1):e0169160