



**HAL**  
open science

## Fingertip nail bed injuries in children: Comparison of suture repair versus glue (2-octylcyanoacrylate) with 1-year follow-up

L. Chiche, C. Jeandel, C. Lyys, P. Joly-Monrival, F. Alkar, D. Louahem  
M'Sabah, J. Cottalorda, M. Delpont

### ► To cite this version:

L. Chiche, C. Jeandel, C. Lyys, P. Joly-Monrival, F. Alkar, et al.. Fingertip nail bed injuries in children: Comparison of suture repair versus glue (2-octylcyanoacrylate) with 1-year follow-up. *Hand Surgery and Rehabilitation*, 2020, 39 (6), pp.550-555. 10.1016/j.hansur.2020.09.001 . hal-03339390

**HAL Id: hal-03339390**

<https://hal.umontpellier.fr/hal-03339390v1>

Submitted on 7 Nov 2022

**HAL** is a multi-disciplinary open access archive for the deposit and dissemination of scientific research documents, whether they are published or not. The documents may come from teaching and research institutions in France or abroad, or from public or private research centers.

L'archive ouverte pluridisciplinaire **HAL**, est destinée au dépôt et à la diffusion de documents scientifiques de niveau recherche, publiés ou non, émanant des établissements d'enseignement et de recherche français ou étrangers, des laboratoires publics ou privés.



Distributed under a Creative Commons Attribution - NonCommercial 4.0 International License

**Fingertip nail bed injuries in children: comparison of suture repair versus glue (2-octylcyanoacrylate) with 1-year follow-up**

**Traumatismes du lit de l'ongle chez les enfants : étude comparative entre suture conventionnelle et colle (2-octylcyanoacrylate) à un an de recul**

L. Chiche<sup>1</sup>, C. Jeandel<sup>1</sup>, C. Lyps<sup>2</sup>, P. Joly-Monrigal<sup>1</sup>, F. Alkar<sup>1</sup>, D.J.M. Sabah<sup>1</sup>, J. Cottalorda<sup>1</sup>,  
M. Delpont<sup>1</sup>

1 : Service de chirurgie orthopédique infantile, Hôpital Lapeyronie, CHU Montpellier,  
Université de Montpellier, 191, avenue du Doyen Gaston Giraud, 34925 Montpellier cedex 5,  
France

2 : Service des urgences pédiatriques, Hôpital Lapeyronie, CHU Montpellier, Université de  
Montpellier, 191, avenue du Doyen Gaston Giraud, 34925 Montpellier cedex 5, France

Corresponding author:

Marion DELPONT

Mail: [m-delpont@chu-montpellier](mailto:m-delpont@chu-montpellier)

Phone number: 0033 467339581

ORCID: 0000-0002-6387-2119

Other authors :

Leo CHICHE

Clément JEANDEL

Claudine LYPS

Pauline JOLY-MONRIGAL

Fanny ALKAR

Djamel LOUAHEM M SABAH

Jérôme COTTALORDA

**Conflict of interest and source of funding:**

None declared.

## **Fingertip nail bed injuries in children: comparison of suture repair versus glue (2-octylcyanoacrylate) with 1-year follow-up**

### **Traumatismes du lit de l'ongle chez les enfants : étude comparative entre suture conventionnelle et colle (2-octylcyanoacrylate) à un an de recul**

#### **Abstract**

The main objective of this study was to compare the medium-term results of nail bed repair in children using glue (2-octylcyanoacrylate) versus absorbable sutures. The secondary objective was to compare the results of treatment in the emergency room versus the operating room. This retrospective review of 74 fingertip nail bed lacerations (68 children) evaluated the appearance and pain at the last follow-up visit (minimum of 1 year), and the operating time. Mean age was 3.3 years at time of injury (range 10 months–13 years), with a mean follow-up of 2.6 (1–7) years. Thirty-six nail beds were repaired with glue; 38 were sutured. The clinical outcomes in the two groups were similar. The rate of nail dystrophy was 14% (5% major) regardless of the technique. Nail bed repair time was significantly shorter in the glue group (10.2 vs. 20.3 min,  $p < 0.001$ ). Forty-five repairs were performed in the operating room and 29 in the emergency room. The complication rate (early infections) was significantly higher in patients treated in the emergency room. Tissue adhesive (2-octylcyanoacrylate glue) is a reliable option for repairing nail bed lacerations, both in terms of outcomes and speed of repair. Treatment in the operating room is preferable.

#### **Résumé**

L'objectif principal était de comparer les résultats à moyen terme des enfants ayant eu une suture du lit de l'ongle par de la colle (2-octylcyanoacrylate) versus une suture conventionnelle. L'objectif secondaire était de comparer les résultats de la prise en

charge aux urgences versus au bloc opératoire. Cette étude rétrospective de 74 sutures (68 enfants) pris en charge pour une réparation de lit de l'ongle avec un recul minimum d'un an a évalué l'aspect esthétique et la douleur au dernier recul, et le temps opératoire. L'âge moyen était de 3,3 ans au moment du traumatisme (extrêmes : 10 mois-13 ans), et le recul moyen de 2,6 ans (extrêmes : 1-7 ans). Trente-six lits de l'ongle ont été réparés avec de la colle ; 38 ont été suturés. Les résultats cliniques des deux groupes étaient similaires. Le taux de dystrophie était de 14% (5% majeures) quelle que soit la technique. Le temps opératoire était significativement plus court dans le groupe colle (10,2 contre 20,3 min,  $p < 0,001$ ). Quarante-cinq sutures ont été réalisées au bloc opératoire, 29 aux urgences. Le taux de complications (infections précoces) était significativement supérieur chez les patients traités aux urgences. La colle à base de 2-octylcyanoacrylate est une option fiable pour suturer le lit de l'ongle, avec un raccourcissement du temps opératoire. La prise en charge au bloc opératoire doit être privilégiée.

*Keywords:* Nail dystrophy; Nail bed injuries; Fingertip injuries; 2-octylcyanoacrylate; Children; Suture

*Mots-clés :* Dystrophie unguéale ; Traumatisme unguéal ; Lit de l'ongle ; 2-octylcyanoacrylate ; Enfants ; Suture

## 1. Introduction

Injuries to the upper limb make up one-third of all domestic accidents in children.

Injuries to the fingertips are very common with the primary mechanism being a crush injury [1]. This mechanism can result in a wide range of presentations, from simple nail avulsion to finger amputation, with possible nail bed injuries and open fractures [2]. Nail dystrophy can occur after wounds to the nail bed, with potential functional and cosmetic deficiencies [3-4]. Preventing these dystrophies requires careful and standardized management of nail bed wounds, including removal of the nail plate, assessment of the nail bed (or even the matrix) laceration with, as needed, suture repair and repositioning of the nail plate, or potentially addition of a nail implant [5-6]. This strategy can be simplified by using a skin adhesive made with 2-octylcyanoacrylate (OCA). Use of this type of glue for closing wounds has been validated, and some authors have described using it to repair nail bed lacerations [7-11]. However, these case studies were either done in adults or in children with a short follow-up.

The primary aim of this study was to compare the medium-term results of children who had their nail bed injuries treated by OCA glue versus those treated by standard suture repair. The secondary aim was to compare the results of children who were treated in the emergency room (ER) versus those treated in the operating room (OR).

## 2. Methods

We carried out a retrospective single-center study of children under 15 years of age who were operated on an emergency basis between 2012 and 2018 because of a nail bed injury and who had a minimum follow-up of 1 year. The patients included had a distal finger injury associated with partial or complete avulsion of the nail plate and a nail bed lesion in zone 2 of the Rosenthal classification [12]. Patients were excluded if

they had a fracture of the base and/or body of the distal phalanx that needed fixation, a defect in the nail bed, amputation, more than 3 days had elapsed between the injury event and the surgical treatment, an infection was already present at the time of treatment, or simply required nail plate repositioning without closure of the nail bed. Distal phalanx fracture was not a reason for exclusion.

All the authors certify that their healthcare facility has approved the study protocol. This work was done in accordance with the requirements of the 1964 Declaration of Helsinki and its subsequent amendments. All patients and their legal representatives provided written informed consent for participation.

### 2.1. Surgical technique

The lacerations were first evaluated in the ER. Depending on the surgeon's preference, the procedure was either done in the ER with local anesthesia of the involved finger and light sedation (nitrous oxide) or in the OR under general anesthesia. A tourniquet was placed at the base of the involved finger or limb. In the ER, the procedure was done most of the time by a junior surgeon, while it was done by a senior surgeon in the OR. Antimicrobial prophylaxis consisted of a single dose of amoxicillin/clavulanic acid. No matter which technique was used, the first step was to remove the nail plate. Next, the wound was cleaned by draining the hematoma, which allowed a more extensive examination of the nail bed (Fig. 1). If a skin wound was also present, especially in the paronychium, it was closed with interrupted sutures using fast-absorbing 4-0 suture.

The nail bed laceration was then closed. The choice of methods was left up to the surgeon and was not related to the wound's severity. With standard suture repair, the nail bed was closed with interrupted slow absorbing 6-0 monofilament sutures. The nail plate was cleaned, and a window made (except if the nail was very small). It was repositioned under the eponychium and held in place by a cross stitch with absorbable suture.

In the patients treated with OCA glue, the nail bed laceration was reduced after suturing the paronychia. The proximal part of the nail plate was pre-positioned under the eponychium. A drop of glue was applied on the nail bed to close the wound; this also served to reposition the nail plate, which was immediately reduced and held until the glue dried. Hemostatic forceps were used to lift the tip of the nail before applying the glue, then to lower the nail immediately after having applied a drop of glue under it. This made it possible to apply the nail on the nail bed properly and helped to reduce the margins of the nail bed. The tourniquet time was recorded for each procedure.

A dressing resembling a boxing glove was placed over the entire hand; it was redone regularly until healing was complete. The repaired nail spontaneously lifts after 2-4 weeks, when the glue or suture used to hold it in place resorbed itself.

## 2.2. Clinical assessment

The clinical examination at a minimum follow-up of 1 year looked for nail dystrophy and pain (spontaneous upon palpation, to heat or cold, or dysesthesia). The dystrophies were classified based on the criteria set out by Dumontier et al. [13], as “major dystrophy” (hook-nail deformity, bifid nail, onycholysis, longitudinal striations, non-adherent nail plate, or hypertrophic hyponychium) or “minor dystrophy” (curved nail, irregular nail, harder or thicker nail plate, anterior or lateral ingrowth). The final appearance was graded by the parents on a scale of 0 to 10.

## 2.3. Statistical analysis

The alpha type I risk was set at 5% for all analyses, which were done with R software version 3.1 (R Development Core Team, 2008; R Foundation for Statistical Computing, Vienna, Austria). The groups were compared using the Wilcoxon test. The qualitative variables were compared with a Fisher’s exact test. A  $p$  value  $< 0.05$  was considered statistically significant.



### 3. Results

Of the 87 cases meeting the above criteria, 74 fingers were evaluated in 68 patients (13 lost to follow-up). The mean age at the time of injury was 3.3 years (min 10 months, max 13 years, SD 2.7). The patients were treated by 7 different senior surgeons and 13 different junior surgeons. The mean follow-up was 2.6 years (min 1 year, max 7 years, SD 1.4). The most frequently injured fingers were the middle finger (35%) and the ring finger (28%). A distal phalanx fracture was also present in 58% of cases (43 fingers). Thirty-five patients (36 fingers) were treated with glue (OCA group) and 33 patients (38 fingers) were treated by standard suture repair (suture group). There were no significant differences between groups in terms of age or follow-up. Forty-three patients were treated in the OR (45 fingers) while 25 were treated in the ER (29 fingers). Two patients in the suture group lost their original nail plate, requiring application of an artificial nail plate to protect the nail bed.

#### 3.1. Clinical outcomes (Table 1)

There were no significant differences in the clinical outcomes between the OCA and suture groups. The mean final appearance grade given by the parents was 8.7 (min 6, max 10, SD 1.2), with no significant difference between groups ( $p = 0.415$ ) (Fig. 2).

The overall dystrophy rate was 14%, all fingers pooled; 5% of fingers had major dystrophy. In the OCA group, three fingers in two patients had major dystrophy (hyponychium hypertrophy). One of these patients had undergone surgery on two fingers; he had chronic onychophagia of the fingers with the same type of nail dystrophy found on the other fingers. In the suture group, two fingers had major dystrophy (longitudinal striations, irregular nail with onycholysis) (Fig. 3). In all, there were nine cases of minor dystrophy (Fig. 4): curved nail in three cases, harder nail in three cases, two slightly irregular nail and one lateral ingrowth.

There was no significant difference in the occurrence of dystrophy between fingers treated in the ER and those treated in the OR. However, the patients treated in the ER had a significantly higher number of complications ( $p = 0.024$ ), especially emergency surgical revisions ( $p = 0.012$ ). Five of the fingers treated initially in the ER required revision, all for early infections; three of these cases progressed to nail dystrophy. Among these five cases of secondary infection, four fingers were in the suture group and one was in the OCA group. None of the fingers treated in the OR required revision.

### 3.2. Nail bed repair time

The time required for nail bed laceration repair was 10.2 minutes (min 4, max 16, SD 1.5) in the OCA group and 20.3 minutes (min 15, max 41, SD 2.1) in the suture group ( $p < 0.001$ ).

## 4. Discussion

Our study suggests that OCA glue is a reliable alternative to standard suture repair for treating nail bed lacerations in children. The clinical and cosmetic outcomes are similar after a minimum follow-up of 1 year, while the time required to repair the laceration was significantly shorter with OCA. Use of cyanoacrylate type skin adhesive has already been validated for skin sutures. Some authors have shown it to be effective in other domains such as meniscal suture, selective embolization of aneurysmal bone cysts and treatment of chronic venous insufficiency [14-18]. The use of glue to treat nail injuries was first described by Stanislas and Waldram in 1997 [19]. After having repaired the nail bed with standard sutures, they replaced the nail plate and held it in place with glue (max. 1 ml). This same technique was used by Hallock and Lutz in 2000 [7]. These two studies have demonstrated the effectiveness of OCA glue for repositioning the nail plate, but they did not use it to close the nail bed laceration.

The surgical technique used in our study has the advantage that it only used OCA glue to repair the nail bed, with a dose that was sufficient both to close the nail bed and to hold the nail plate. The finger must be perfectly clean and dry to achieve good reduction of the nail bed wound and good positioning of the nail plate. To simultaneously repair the nail bed and reposition the nail plate, we must first reinsert the proximal part of the nail plate under the eponychial fold before applying a drop of glue, as it binds within a few seconds. This technical aspect is one of the reasons why we do not recommend repairing the nail bed laceration with glue in the ER, as it is crucial that the child stay completely still at the time of glue application. The advantages of the glue are its simplicity of use, which reduces the repair time and the tourniquet time. On average, a tube of glue costs between 15 and 20 Euros, while absorbable suture costs between 7 and 9 Euros. One minute of operating time costs an average of 10 Euros [20]. The reduction in operating time (10 minutes on average) helps to offset the higher cost of the glue. However, a true health economics study would be needed to determine the exact cost difference between these two techniques.

Our results are comparable to those in the literature, although most authors only report the results of short-term case series. In a prospective study of 30 children followed for 3 months, Langlois et al. observed no dystrophy or nail pain after repairing nail bed lacerations with OCA glue [10]; however, this study had no comparator. Strauss et al. did a prospective study comparing 40 adults treated by standard suture repair or glue with 5 months' follow-up [8]. There was no difference between groups in terms of nail appearance or function. The only notable difference was the operating time (9.5 min for the glue versus 27.8 minutes for standard suture repair). A review of literature by Edwards and Parkinson in 2016 found no difference between OCA glue and suture repair [21]. This review looked at 6 articles and 118 patients, although only one study was comparative (Strauss et al. [8]). To our knowledge, no comparative study on nail bed repair has been done in children up to now. Another important aspect

of our study was its long follow-up. After 12 months, two cycles of nail growth have occurred. The minimum follow-up of 1 year means that the results can be considered final.

Using glue does not eliminate the risk of nail dystrophy, with an overall 14% rate independent of the technique. Patients must be informed of this potential progression. Nevertheless, the rate of major dystrophy was low (5%) with few patients having this problem. None of our patients needed surgical revision later on for this mostly cosmetic concern.

Because of the substantial complication rate (mainly secondary infections) in patients treated in the ER, we prefer closing nail bed lacerations in the OR (either with glue or standard suture repair). In the ER, rigorous asepsis is often difficult to achieve. Meticulous cleaning of the wound before closing it is also difficult to accomplish in the ER. The glue's antibacterial properties have been demonstrated experimentally [18] although it is technically difficult in an emergency context to be certain that the child will stay completely still when the glue is applied. Also, using the glue provides a water-tight seal of the nail bed, where even the smallest amount of oozing would tend to collect. For this reason, very few patients are treated with glue in the ER, especially that up to now, this technique has only been described in children treated in the OR. Of the four fingers treated with glue in the ER, one required revision due to early secondary infection. In a large comparative study, Weinand et al. [22] found a higher number of nail dystrophies and infections when an artificial nail was used instead of the original nail. We cannot address this risk since few of our patients received an artificial nail.

Other potential complications can occur such as chronic infections, granulomas due to a foreign body reaction, necrosis of the nail bed, and tattooing of tissues [23], although we have not observed this in our patients. It was also difficult to determine whether bone diffusion of the glue occurred as we excluded patients who had a defect in the

nail bed. The nail bed margins were reduced side-to-side. We did not find any negative bone effects in our patients, although we cannot ensure that no diffusion occurred in the underlying bone.

Since the first description in 1967 by Ashbell et al. [6], suturing the nail bed is the standard treatment for nail bed lacerations. In some instances, it is possible to achieve satisfactory drainage of the subungual hematoma and reposition the nail plate [24]. We prefer restoring the nail bed, because if nail dystrophy develops, surgical treatment can be difficult [25].

Our study has several limitations. This was a retrospective non-randomized study involving multiple surgeons. Some surgeons preferred doing standard suture repair while others preferred using glue. Some patients were treated in the ER while others were treated in the OR. In the ER, the patients were more likely to be treated by a junior surgeon. In the OR, the procedure was supervised by a senior surgeon. This also impacts the interpretation of our findings. In theory, we would need to do a prospective randomized study between patients treated by standard suture repair or glue, and between those treated in the ER versus the OR. Our primary objective was to inventory the results of our patients treated for this common lesion as there are few clear recommendations. Nevertheless, this study revealed that treating fingertip wounds in the ER significantly increases the risk of early infections. The dystrophy rate was similar between fingers treated in the ER and the OR, while in a non-randomized study, the most severe crush injuries were likely treated urgently in the OR.

How we assessed the outcomes could be open to criticism. It is difficult to precisely determine the results in young children. Evaluation of nail dystrophy by the surgeon is subjective. For this reason, we supplemented our assessment with a grade provided by the parents, as was done in the benchmark pediatric study on this topic [8]. The assessment of surgical repair time is based on the tourniquet time. A specific assessment of the time required to repair the nail bed laceration would be the best way

to compare the operating time between the two techniques, although this information was not available in this retrospective study. Another key piece of information that is not collected routinely in surgical reports is the type of initial lesion in the nail bed; this information would help us understand why certain patients develop nail dystrophy, regardless of which technique is used. These criteria could be part of a prospective randomized study, which would make it possible to validate use of OCA glue to close nail bed wounds with a higher level of evidence.

## **5. Conclusion**

OCA glue is a viable alternative for repairing nail bed lacerations in young children as it provides similar clinical and cosmetic results to standard suture repair in the medium term while significantly reducing the operating time. Doing the nail bed repair in the ER in children increases the risk of complications (especially surgical revision due to secondary infection) no matter which technique is used.

### **Conflict of interest:**

The authors have no conflicts of interest to declare.

## References

- [1] Algaze I, Snyder AJ, Hodges NL, Smith GA. Children treated in United States emergency departments for door-related injuries, 1999-2008. *Clin Pediatr* 2012;51:226–32.
- [2] Fitoussi F. [Hand injuries in children]. *Chir Main* 2013;32 Suppl 1:S2-6.
- [3] Zook EG, Guy RJ, Russell RC. A study of nail bed injuries: Causes, treatment, and prognosis. *J Hand Surg Am* 1984;9:247–52.
- [4] Pannier S, Dana C, Journé A, Péjin Z, Glorion C. [Fingertip injuries in children]. *Chir Main* 2013;32 Suppl 1:S39-45.
- [5] Patel L. Management of simple nail bed lacerations and subungual hematomas in the emergency department. *Pediatr Emerg Care* 2014;30:742–45; quiz 746–48.
- [6] Ashbell TS, Kleinert HE, Putcha SM, Kutz JE. The deformed finger nail, a frequent result of failure to repair nail bed injuries. *J Trauma* 1967;7:177–90.
- [7] Hallock GG, Lutz DA. Octyl-2-Cyanoacrylate adhesive for rapid nail plate restoration. *J Hand Surg Am* 2000;25:979–81.
- [8] Strauss EJ, Weil WM, Jordan C, Paksima N. A prospective, randomized, controlled trial of 2-octylcyanoacrylate versus suture repair for nail bed injuries. *J Hand Surg Am* 2008;33:250–53.
- [9] Yam A, Tan SH, Tan ABH. A novel method of rapid nail bed repair using 2-octyl cyanoacrylate (Dermabond). *Plast Reconstr Surg* 2008;121:148e–49e.
- [10] Langlois J, Thevenin-Lemoine C, Rogier A, Elkaim M, Abelin-Genevois K, Vialle R. The use of 2-octylcyanoacrylate (Dermabond®) for the treatment of nail bed injuries in children: results of a prospective series of 30 patients. *J Child Orthop* 2010;4:61–5.
- [11] Matter-Parrat V, Severac F, Xavier F, Facca S, Hidalgo Diaz JJ, Liverneaux P. Fixation of the nail plate by tension band suture versus 2-octyl-cyanoacrylate gluing for traumatic nail bed injuries reduced without suture: A retrospective study of 27 cases. *Hand Surg Rehabil* 2018;37:180–5.

- [12] Rosenthal EA. Treatment of fingertip and nail bed injuries. *Orthop Clin North Am* 1983;14:675–97.
- [13] Poirier P, Ardouin T. Les lésions traumatiques de l'appareil unguéal chez l'enfant. In: Dumontier C (éd.) *L'ongle*, vol. 27. Paris: Elsevier SAS; 2000, p. 142–6.
- [14] Koonce SL, Eck DL, Shaddix KK, Perdakis G. A prospective randomized controlled trial comparing N-butyl-2 Cyanoacrylate (Histoacryl), Octyl Cyanoacrylate (Dermabond), and subcuticular suture for closure of surgical incisions. *Ann Plast Surg* 2015;74:107–10.
- [15] Ayan I, Colak M, Comelekoglu U, Milcan A, Ogenler O, et al. Histoacryl glue in meniscal repairs (a biomechanical study). *Int Orthop* 2007;31:241–6.
- [16] Rossi G, Mavrogenis AF, Facchini G, Bartalena T, Rimondi E, et al. How effective is embolization with N-2-butyl-cyanoacrylate for aneurysmal bone cysts? *Int Orthop* 2017;41:1685–92.
- [17] Bozkurt AK, Yilmaz MF. A prospective comparison of a new cyanoacrylate glue and laser ablation for the treatment of venous insufficiency. *Phlebology* 2016;31:106–13.
- [18] Quinn J, Maw J, Ramotar K, Wenckebach G, Wells G. Octylcyanoacrylate tissue adhesive versus suture wound repair in a contaminated wound model. *Surgery* 1997;122:69–72.
- [19] Stanislas JMC, Waldram MA. Keep the nail plate on with Histoacryl®. *Injury* 1997;28:507–8.
- [20] Raft J, Millet F, Meistelman C. Example of cost calculations for an operating room and a post-anaesthesia care unit. *Anaesth Crit Care Pain Med* 2015;34:211-5.
- [21] Edwards S, Parkinson L. Is fixing pediatric nail bed injuries with medical adhesives as effective as suturing?: A review of the literature. *Pediatr Emerg Care* 2016;35:75-7.



- [22] Weinand C, Demir E, Lefering R, Juon B, Voegelin E. A comparison of complications in 400 patients after native nail versus silicone nail splints for fingernail splinting after injuries. *World J Surg* 2014;38:2574–79.
- [23] Venkatesh A, Khajuria A, Greig A. Management of pediatric distal fingertip injuries: a systematic literature review. *Plast Reconstr Surg Glob Open* 2020;20:8:e2595.
- [24] Gellman H. Fingertip-nail bed injuries in children: current concepts and controversies of treatment. *J Craniofac Surg* 2009;20:1033–35.
- [25] Zook E. Reconstruction of a functional and aesthetic nail. *Hand Clin* 2002;18:577-94.

**Figure legends**

Fig. 1. Closing of the nail bed lesion with 2-octylcyanoacrylate (OCA) glue. Removal of nail and cleaning of wound (a). Evaluation of nail bed laceration (b). Suture of paronychium by interrupted absorbable suture (c). Final appearance (d).

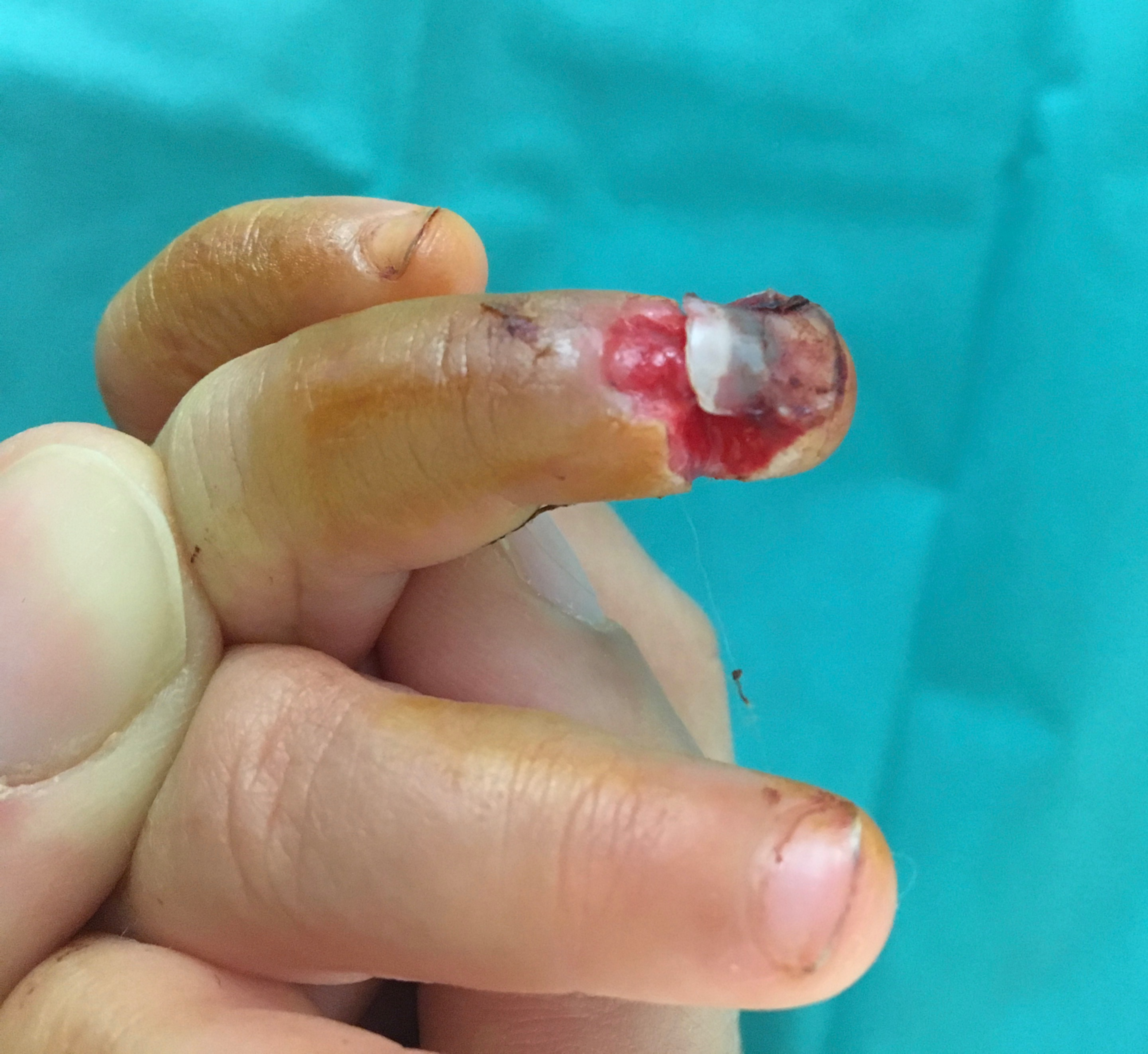Fig. 2. Result of the patient in Figure 1 at 12 months postoperative after using 2-octylcyanoacrylate glue to close a nail bed laceration in the ring finger.

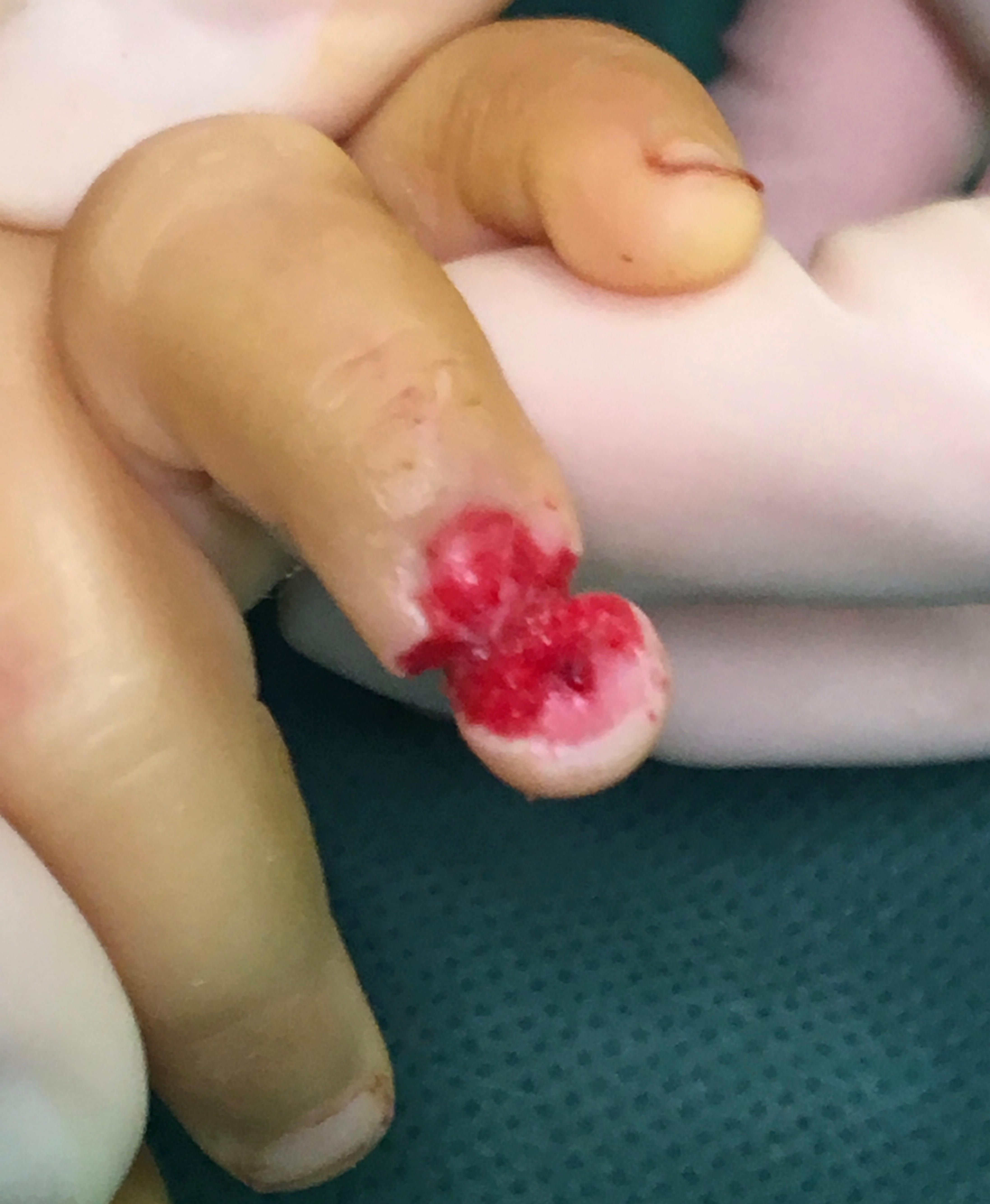Fig. 3. Major dystrophy in the ring finger of the right hand with splitting of the nail plate.

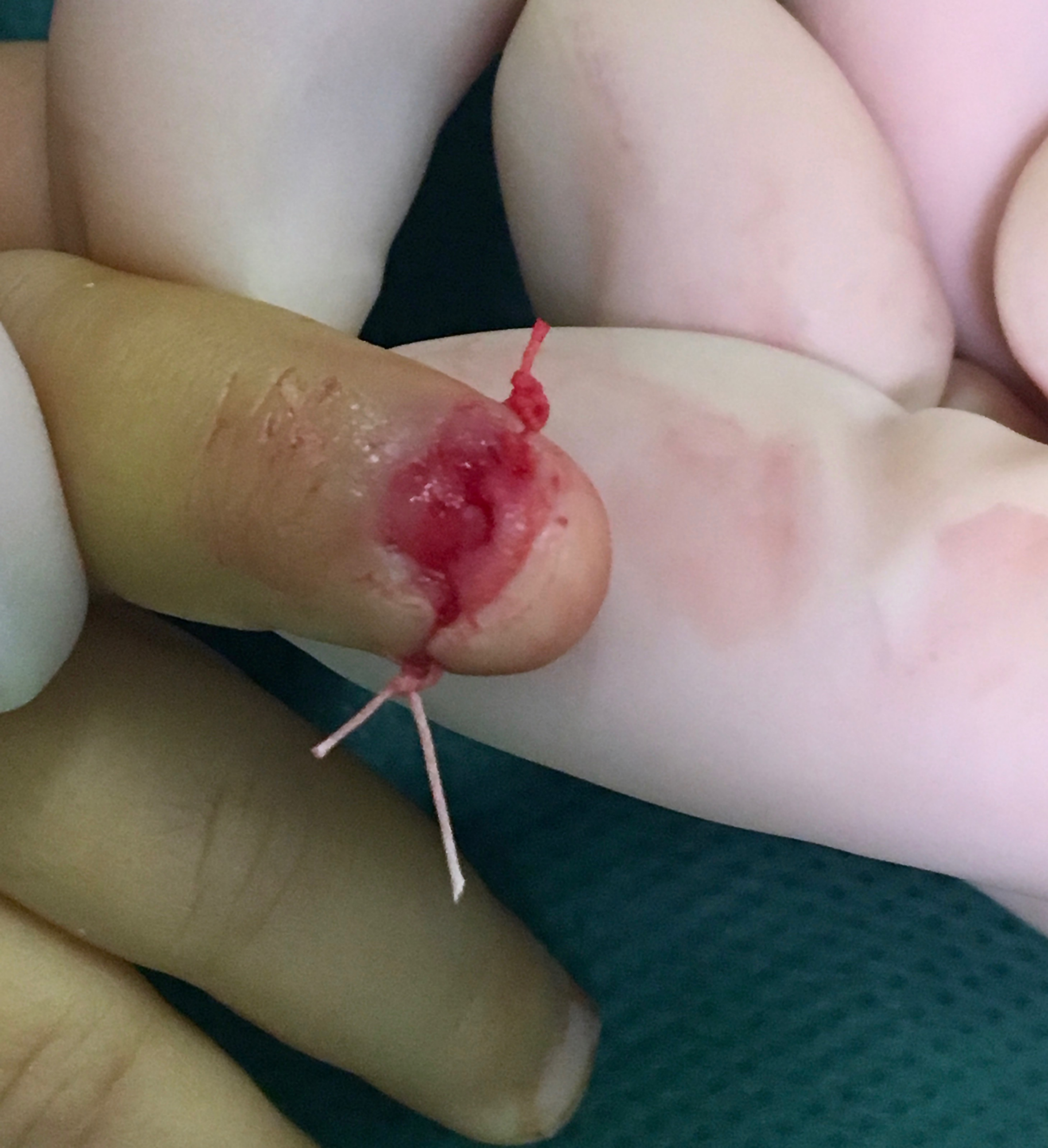
Fig. 4. Minor dystrophy in the ring finger of the right hand with slight irregularity of the hyponychium.

**Table titles**

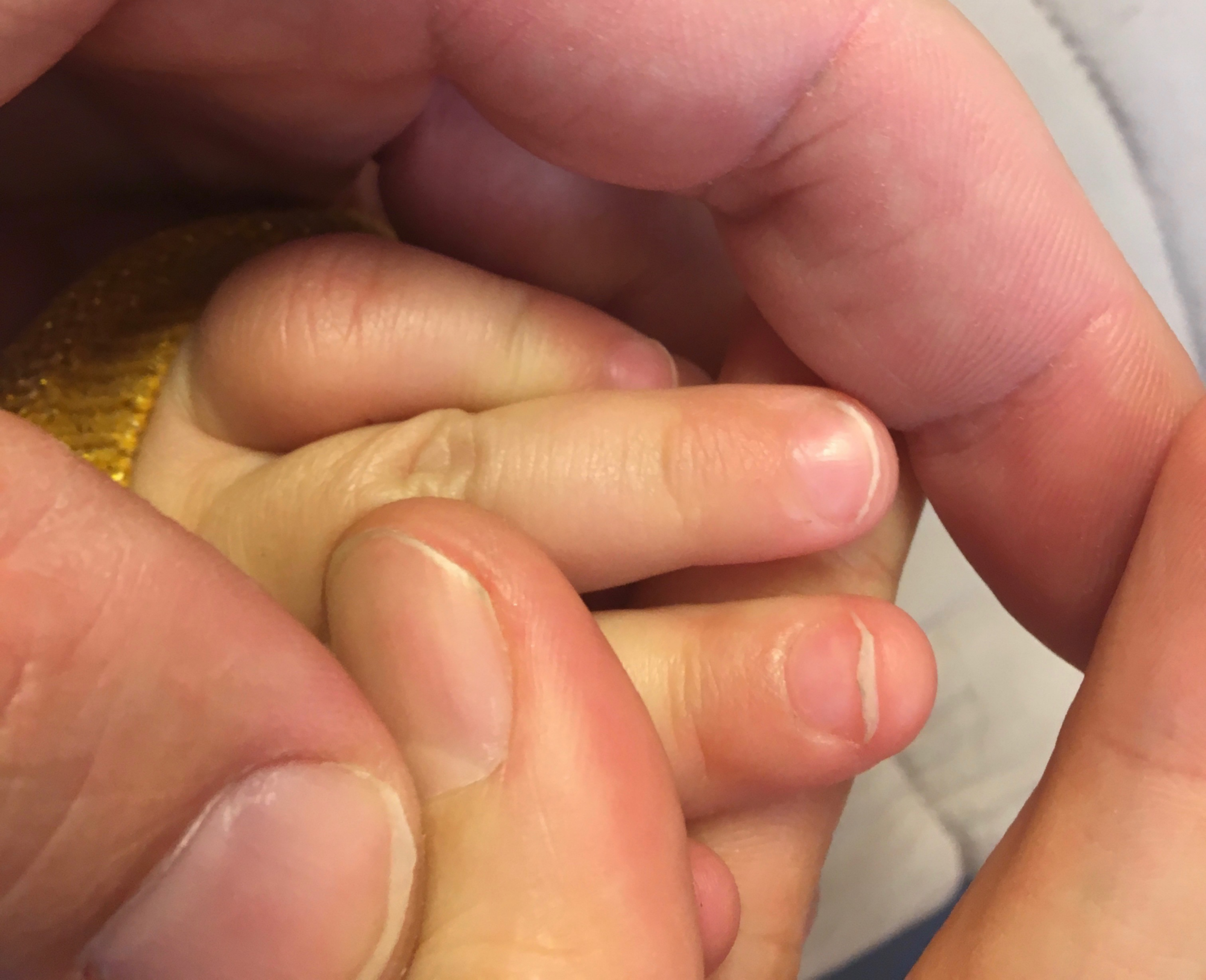Table 1. Clinical outcomes and results of statistical analysis (OCA: 2-octylcyanoacrylate; OR: operating room; ER: emergency room)







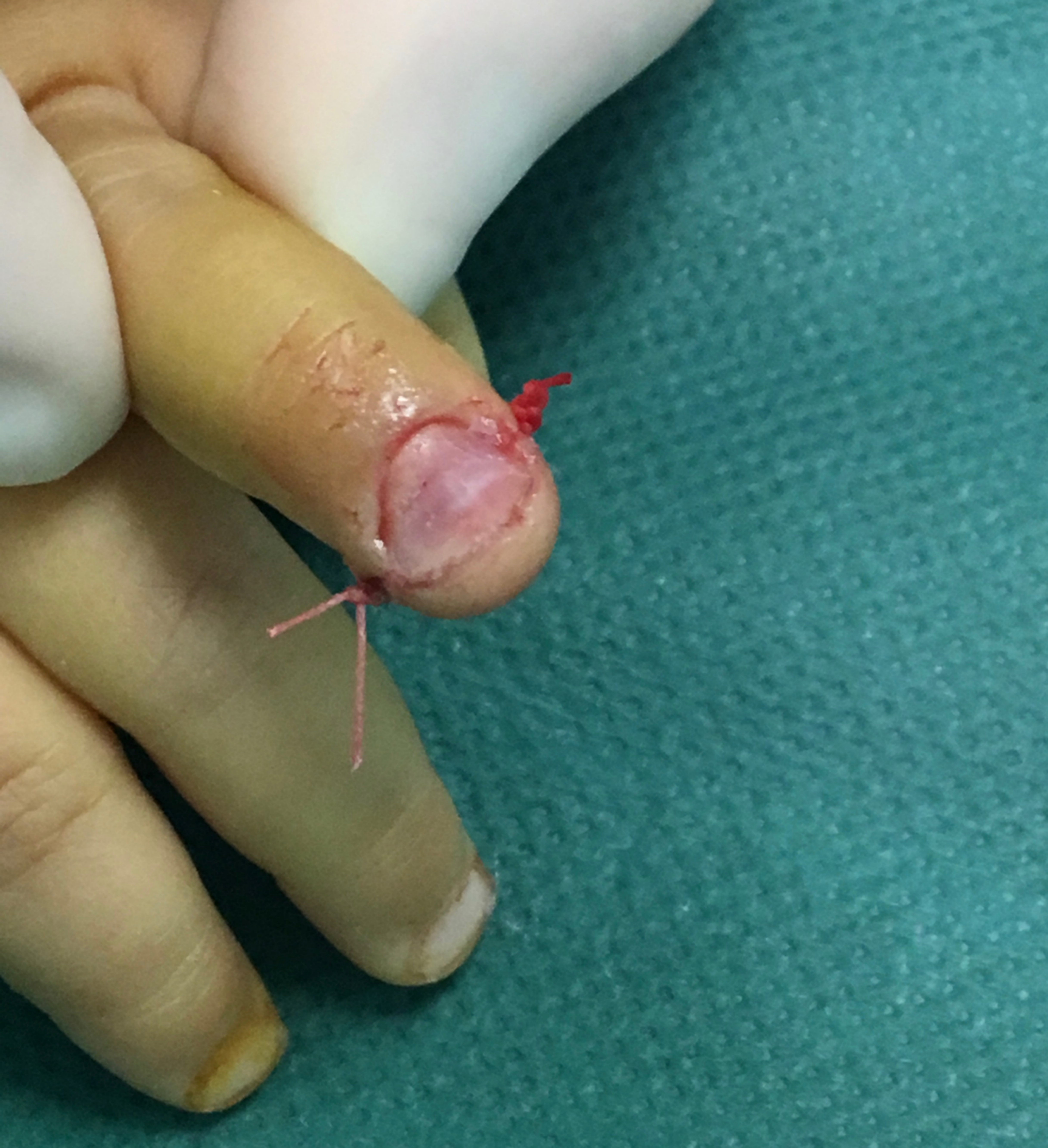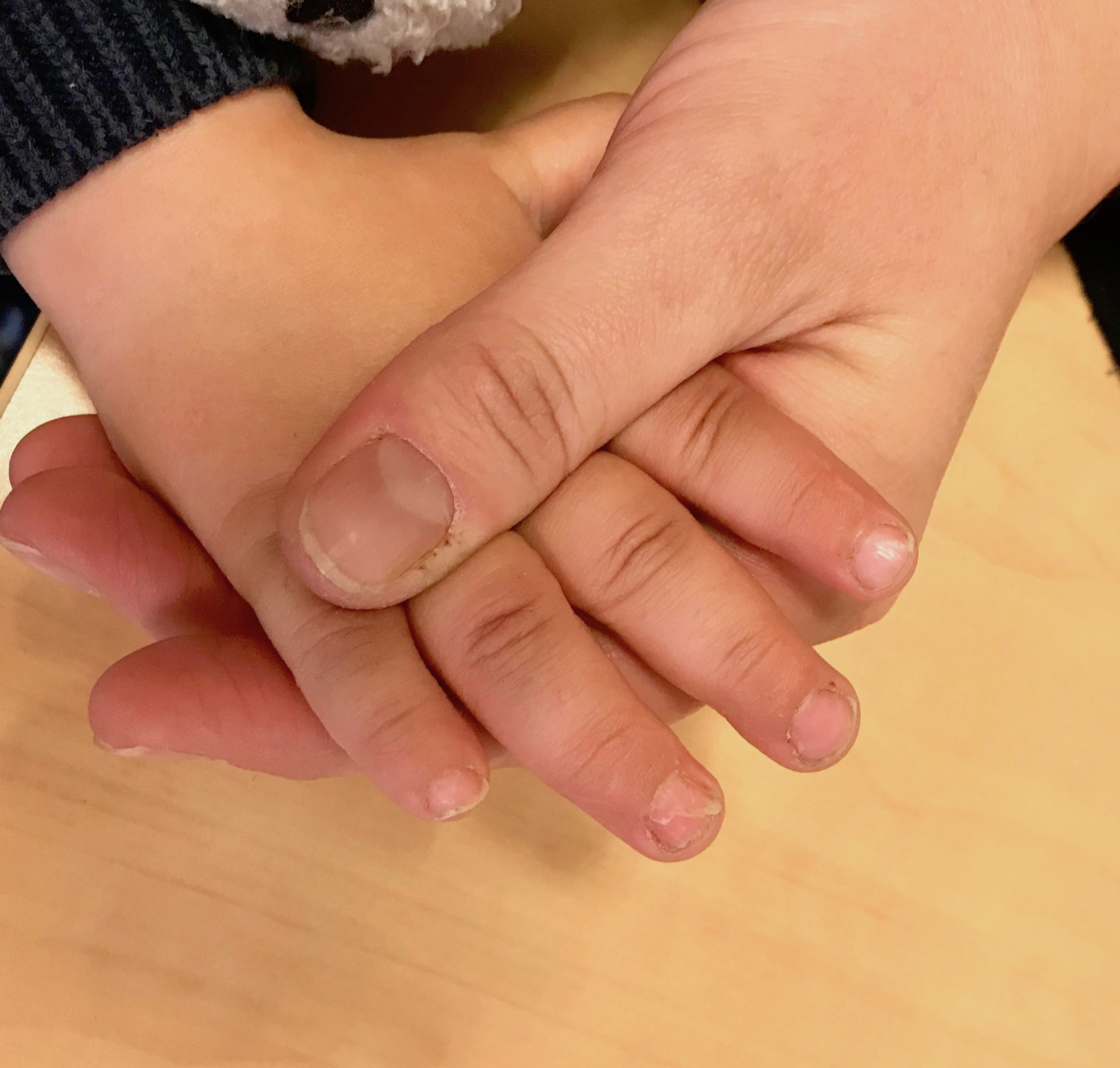








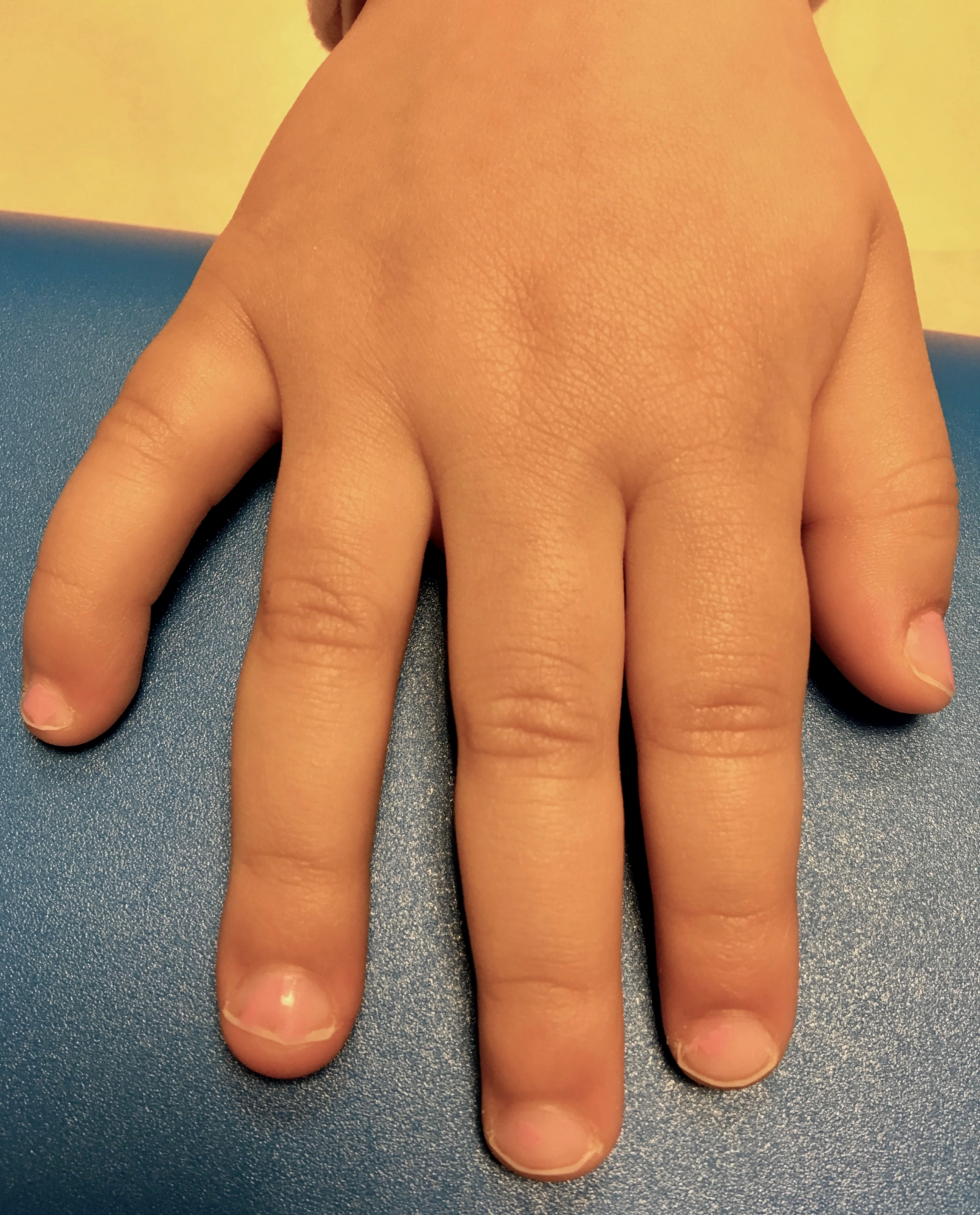

Table 1. Clinical outcomes and results of statistical analysis (*OCA*: 2-octylcyanoacrylate; *OR*: operating room; *ER*: emergency room)

	OCA glue			Suture repair			<i>p</i>
	Total	OR	ER	Total	OR	ER	
Number of fingers	36	32	4	38	13	25	
Major dystrophy	3	3	0	2	0	2	0.67
Minor dystrophy	3	2	1	6	1	5	0.48
Pain	4	3	1	3	0	3	0.659
Emergency revision (infection)	1	0	1	4	0	4	0.358
Delayed revision	0			0			
Operating time (min)	10.2			20.3			<0.001
Satisfaction (/10)	8.6			8.8			0.415