



**HAL**  
open science

## Immediate flare-up–like reaction of skin tests to betalactams with lymphangitis during drug provocation test

Maria de Filippo, Omar Ali Al Ali, Jean Luc Bourrain, Pascal Demoly, Anca Mirela Chiriac

► **To cite this version:**

Maria de Filippo, Omar Ali Al Ali, Jean Luc Bourrain, Pascal Demoly, Anca Mirela Chiriac. Immediate flare-up–like reaction of skin tests to betalactams with lymphangitis during drug provocation test. *Journal of Allergy and Clinical Immunology: In Practice*, 2021, 9 (2), pp.1021-1023.e1. 10.1016/j.jaip.2020.09.016 . hal-03338248

**HAL Id: hal-03338248**

**<https://hal.umontpellier.fr/hal-03338248>**

Submitted on 13 Feb 2023

**HAL** is a multi-disciplinary open access archive for the deposit and dissemination of scientific research documents, whether they are published or not. The documents may come from teaching and research institutions in France or abroad, or from public or private research centers.

L'archive ouverte pluridisciplinaire **HAL**, est destinée au dépôt et à la diffusion de documents scientifiques de niveau recherche, publiés ou non, émanant des établissements d'enseignement et de recherche français ou étrangers, des laboratoires publics ou privés.



Distributed under a Creative Commons Attribution - NonCommercial 4.0 International License

1 **Immediate flare-up-like reaction of skin tests to betalactams with lymphangitis during drug**  
2 **provocation test**

3  
4  
5 **DE FILIPPO Maria<sup>1,2\*</sup>M.D, AL ALI Omar<sup>1\*</sup> M.D, BOURRAIN Jean Luc<sup>1</sup> M.D, DEMOLY**  
6 **Pascal<sup>1,3</sup> MD-PhD, CHIRIAC Anca Mirela<sup>1,3</sup> MD-PhD**

7  
8  
9 <sup>1</sup> Department of Pulmonology, Division of Allergy, Hôpital Arnaud de Villeneuve, University  
10 Hospital of Montpellier, Montpellier, France;

11 <sup>2</sup> Department of Pediatrics, Policlinico San Matteo Pavia, Istituto di Ricovero e Cura a Carattere  
12 Scientifico, Italy;

13 <sup>3</sup> Equipe EPAR - IPLESP, UMR 1136 INSERM - Sorbonne Université, Paris, France  
14

15 \* The authors contributed ex aequo.

16  
17 Words: 1242

18  
19  
20 \* *Post publication corresponding author:*

21 Dr Anca Mirela CHIRIAC, a-chiriatic@chu-montpellier.fr

22 Allergy Unit, Arnaud de Villeneuve Hospital, University Hospital of Montpellier

23 Address: 371, Avenue du Doyen Gaston Giraud, 34295 Montpellier Cedex 5, Montpellier, France

24 Phone: +33 467336107

25  
26  
27 Conflict of interest: none

41 Beta-lactam (BL) antibiotics are the most common cause of drug-induced hypersensitivity reactions  
42 (DHR).

43 Clinical Implications:

44 We present two clinical cases of patients with suspected immediate BL DHR who underwent drug  
45 allergy work-up according to standardized diagnostic procedures, including skin tests (ST: prick,  
46 SPT and intradermal tests, IDT) and drug provocation tests (DPT)<sup>1</sup>. ST became positive after the  
47 first DPT dose. The patients gave their consent to the diagnostic allergy work-up and use of their  
48 de-identified data for research purposes.

49

50 A 68-year-old man placed on the liver transplantation waitlist for cirrhosis due to hepatitis C viral  
51 infection in August 2017 was admitted to the hospital for cholangitis. The patient was empirically  
52 treated with piperacilline/tazobactam (piperacillin 4g/t.i.d) intravenously. He had previously  
53 tolerated this drug. About 45 minutes after the first dose, he developed pruritus and urticaria on the  
54 neck and trunk without other associated symptoms. He rapidly recovered with cetirizine (10 mg) by  
55 oral route. In December 2018 the patient reported a similar episode, treated with intravenous  
56 dexchlorpheniramine. In June 2019, the patient underwent ST with several penicillin and  
57 cephalosporin reagents. Histamine was used as a positive control. As SPT and IDT at the highest  
58 recommended concentrations were negative when read after 15 minutes and 20 minutes respectively  
59 (according to current recommendations), we proceeded to DPT (the first dose was given 60 minutes  
60 after the IDT reading). Single-blind challenge with intravenous piperacilline/tazobactam was  
61 performed, with 30 minutes increments, starting with 5%<sup>2</sup> (200 mg) of the therapeutic dose (4000  
62 mg) that elicited his initial reaction. A few minutes before the administration of the second dose the  
63 patient reported itching on the arms and scalp, in the absence of objective clinical signs. Therefore,  
64 we decided to interrupt the test and monitor the patient for 15 minutes. A few minutes later the  
65 patient presented a localized itchy erythema at the site of the ST corresponding to pure IDT to  
66 piperacillin/ tazobactam and piperacillin, with ascending lymphangitic infiltration (Figure 1). No  
67 wheal was observed. The ST was nonetheless considered positive, the DPT was interrupted and  
68 cetirizine (10 mg) was administered.  
69 Two hours after the administration of the first dose of the drug, the patient presented localized  
70 urticaria on the arms and the abdomen, with resolution in 90 minutes (see Figure E1 in the Online  
71 Repository).

72

73

74

75 A 62-year-old male patient, mentioned an episode of potential DHR in October 2012, with  
76 generalized urticaria, preceded by pruritus of palms and soles. This reaction started five minutes  
77 after the ingestion of 1000 mg amoxicillin for sinusitis, and during a meal containing shrimps. The  
78 allergy work-up was performed six weeks after the initial reaction. Skin tests (read at 20 min for  
79 IDT) were negative at the maximum recommended concentrations. As the patient had a history of  
80 immediate reaction, DPT with amoxicillin was started immediately after reading the skin tests. The  
81 began with 1 mg of amoxicillin (this was the first dose of the empirical DPT protocols that have  
82 been used in our unit till 2016). Thirty minutes after the first dose of amoxicillin, the patient  
83 presented a positive ST (> 3mm increase in the diameter compared to the injected wheal,  
84 surrounded by erythema) in IDT only at the site of amoxicillin injection, with a linear shape form  
85 and ascending lymphangitis 7.5 cm upward from the injection site (Figure 2). All the other ST  
86 were negative. The DPT was stopped immediately, he was treated with cetirizine (10 mg) and  
87 monitored for 90 minutes. No other symptoms appeared.

88  
89 When negative immediate-reading ST occur in patients with a clinical history compatible with an  
90 immediate reaction (i.e., potentially IgE-mediated), a DPT is usually performed, in absence of  
91 contra-indications<sup>1</sup>. In the two cases we present, the first dose of the oral DPT was followed by ST  
92 positivity, associated in Case 1 with a systemic reaction (dose administered, 5% of initial eliciting  
93 dose). The peculiarity of the second case is that the patient developed a positive ST at 60 minutes,  
94 as opposed to 20 minutes following their performance and 30 minutes after the start of DPT without  
95 systemic symptoms (dose administered 0.1% of the initial eliciting dose). The absence of any  
96 systemic reaction in Case 2 may be due to the low initial dose.

97 ST reversal in these patients is likely due to a flare-up phenomenon. Flare-up reactions refer to the  
98 reactivation of previous positive ST or the switch from negative to positive ST, usually after a  
99 systemic challenge. This phenomenon is classically described in delayed-type allergy<sup>3</sup>. To the best  
100 of our knowledge, such rapid flare-up reactions have not been described for BL (published cases  
101 include delayed reactions)<sup>3,4</sup>, but case reports suggestive of a flare-up-like reactivity suggesting  
102 IgE-mediated allergy have been described for other drugs (e.g., ibuprofen<sup>5</sup>, paracetamol<sup>6</sup>).

103 In the two cases we present we observed localized superficial inflammation processes that  
104 induced linear in superficial lymphangitis from the site of the IDT of piperacillin and  
105 piperacillin/tazobactam (Case 1) and amoxicillin (Case 2), extending toward the arm. Lymphangitis  
106 is an inflammation of one or more lymphatic channels mostly induced by infections (mostly  
107 bacterial infections) occurring at the distal site of vessels. Many other causes could induce linear  
108 supralymphatic eruptions with superficial lymphangitis and some of these are viral and fungal

109 infections, insect or spider bites, and iatrogenic etiologies like vaccinations, purified protein  
110 derivative placement<sup>7</sup>. In a case series reported by Kano et al, three different cases which focus on  
111 the theme of superficial lymphangitis were discussed and the idea of the effect of contact allergens  
112 as a co-factor in this pathology was put forward. In their report, ST were negative for the alleged  
113 contact allergens and this is why they were merely considered as co-factors<sup>8</sup>. In our cases, the drugs  
114 are not contact allergens in the clinical history but injecting them by IDT may render them similar  
115 to a contact allergen. Most described cases of allergic lymphangitis concern delayed  
116 hypersensitivity reactions. Because dendritic cells are known to migrate from the sites of allergen  
117 exposure to draining lymph nodes during the inflammatory response, this hypothesis could explain  
118 why the linear lesions begin within the sites of IDTs and extend proximally to the draining lymph  
119 nodes, in delayed DHR. The two cases we presented revealed acute superficial lymphangitis, which  
120 raises the hypothesis of a local immunologic reaction to an allergen along lymphatic vessels,  
121 establishing a linear lesion overlying the skin. The promptness in onset and resolution of the lesions  
122 supports the assumption of this local reaction being elicited by mast cell mediator release, as  
123 connective tissue mast cells are located by nerve endings and alongside the blood and lymphatic  
124 vasculature<sup>9</sup>. Late-phase IgE-associated inflammatory responses to allergens cannot be excluded,  
125 considering that the reaction occurred later than classically observed in ST for immediate type  
126 reactions.

127 Although in Case 1, the reactive IDTs did not match the recommended positivity criteria (no wheal  
128 was detected, only surrounding erythema), in Case 2, the IDT became positive according to  
129 recommended reading criteria. In our experience, in more than 4000 patients tested for a suspicion  
130 of DHR to BL, these are the only two cases of their kind.

131 As clinicians working in the drug allergy field and operating with iatrogenic procedures (especially  
132 with BL antibiotics), we should be aware of rare cases. In these examples, monitoring the site of a  
133 negative ST (despite clinical histories of immediate reactions) even after reading the ST result  
134 within recommended lapses of time and when starting DPT prevented us from exposing our patients  
135 to higher doses of allergens and potentially a more severe reaction.

136  
137 Funding: none

138  
139  
140  
141  
142  
143

144 **BIBLIOGRAPHY**

- 145
- 146 1. Romano A, Atanaskovic-Markovic M, Barbaud A, Bircher AJ, Brockow K, Caubet JC et al.  
147 Towards a more precise diagnosis of hypersensitivity to beta-lactams - an EAACI position  
148 paper [published online ahead of print, 2019 Nov 21]. *Allergy*. 2019;10.1111/all.14122.  
149 doi:10.1111/all.14122
- 150 2. Chiriac AM, Rerkpattanapipat T, Bousquet PJ, Molinari N, Demoly P. Optimal step doses for  
151 drug provocation tests to prove beta-lactam hypersensitivity. *Allergy*. 2017;72(4):552-561.
- 152 3. Tramontana M, Hansel K, Bianchi L, Agostinelli D, Stingeni L. Flare-up of previously negative  
153 patch test and intradermal test with amoxicillin after oral provocation. *Contact Dermatitis*.  
154 2018;79(4):250–251.
- 155 4. Reig Rincón de Arellano I, Villalón García AL, Cimarra Alvarez-Lovell M, Robledo Echarren  
156 T, Martínez-Cócerca MC. Flare up to betalactams. *Allergol Immunopathol (Madr)*.  
157 2005;33(5):282–284. doi:10.1157/13080932
- 158 5. González de Olano D, González Mancebo E, Gandolfo Cano M, Menéndez Baltanás A, Trujillo  
159 Trujillo MJ. Flare-up-Like phenomenon in a skin prick test after oral challenge with  
160 ibuprofen. *J Investig Allergol Clin Immunol*. 2007;17(6):414–415.
- 161 6. Rodríguez-Fernández A, Sánchez-Domínguez M, Noguerado-Mellado B, Rojas-Pérez-Ezquerria  
162 P. Flare-Up Phenomenon of Intradermal Test with Anaphylactic Reaction to Paracetamol  
163 (Acetaminophen). *Recent Pat Inflamm Allergy Drug Discov*. 2019;13(1):69–72.
- 164 7. Cohen BE, Nagler AR, Pomeranz MK. Nonbacterial Causes of Lymphangitis with Streaking. *J*  
165 *Am Board Fam Med*. 2016;29(6):808-812.
- 166 8. Kano Y, Inaoka M, Shiohara T. Superficial lymphangitis with interface dermatitis occurring  
167 shortly after a minor injury: possible involvement of a bacterial infection and contact allergens.  
168 *Dermatology*. 2001;203(3):217-20.
- 169 9. Pal S, Nath S, Meininger CJ, Gashev AA. Emerging Roles of Mast Cells in the Regulation  
170 of Lymphatic Immuno-Physiology. *Front Immunol*. 2020;11:1234.

171

172

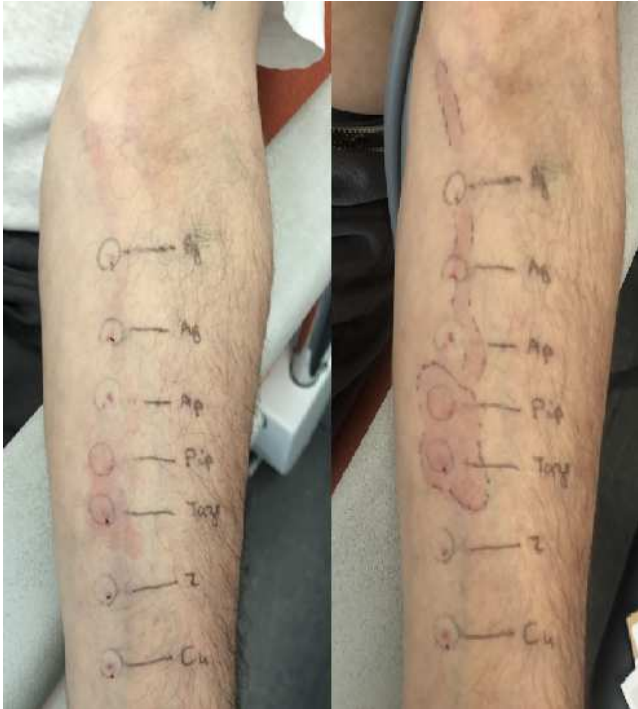
173 **Figure Legends**

174 **FIGURE 1:** The following reagents were tested at the maximal non-irritant concentrations  
175 (“pure”): penicillin G (10 000 UI/ml, PG), amoxicillin/clavulanic acid (20 mg/ml for amoxicillin,  
176 Ag), ampicillin (20 mg/ml, Ap), piperacillin (20 mg/ml), piperacillin/tazobactam (20 mg/ml for  
177 piperacillin), cefuroxime (20 mg/ml, Z), ceftriaxone (20 mg/ml, C4).

178 **FIGURE 2:** Positive skin test to amoxicillin (20 mg/ml); the injected wheal is circled at the time of  
179 the performance of IDT; the increased wheal, erythema and lymphangitis occurred after 1 mg  
180 amoxicillin by oral route.

181

**FIGURE 1**



**FIGURE 2**

