



HAL
open science

Modification of matched distal ulnar resection for distal radio-ulnar joint arthropathy: Analysis of distal instability and radio-ulnar convergence

Hugo Barret, Cyril Lazerges, Pierre-Emmanuel Chammas, Benjamin Degeorge, Bertrand Coulet, Michel Chammas

► To cite this version:

Hugo Barret, Cyril Lazerges, Pierre-Emmanuel Chammas, Benjamin Degeorge, Bertrand Coulet, et al.. Modification of matched distal ulnar resection for distal radio-ulnar joint arthropathy: Analysis of distal instability and radio-ulnar convergence. *Orthopaedics & Traumatology: Surgery & Research*, 2020, 106 (8), pp.1597-1603. 10.1016/j.otsr.2020.07.008 . hal-03231772

HAL Id: hal-03231772

<https://hal.umontpellier.fr/hal-03231772v1>

Submitted on 15 Dec 2022

HAL is a multi-disciplinary open access archive for the deposit and dissemination of scientific research documents, whether they are published or not. The documents may come from teaching and research institutions in France or abroad, or from public or private research centers.

L'archive ouverte pluridisciplinaire **HAL**, est destinée au dépôt et à la diffusion de documents scientifiques de niveau recherche, publiés ou non, émanant des établissements d'enseignement et de recherche français ou étrangers, des laboratoires publics ou privés.



Distributed under a Creative Commons Attribution - NonCommercial 4.0 International License

Original article

Modification of Matched Distal Ulnar Resection for Distal Radio-Ulnar Joint

Arthropathy: Analysis of Distal Instability and Radio-Ulnar Convergence

Hugo **BARRET**¹, Cyril **LAZERGES**¹, Pierre-Emmanuel **CHAMMAS**¹, Benjamin **DEGEORGE**¹, Bertrand **COULET**¹, Michel **CHAMMAS**¹

1 Service de Chirurgie de la Main et du Membre Supérieur, Chirurgie des Nerfs Périphériques
SOS Main, Montpellier, France

Corresponding author: H. BARRET

Service de Chirurgie de la Main et du Membre Supérieur, Chirurgie des Nerfs Périphériques
SOS Main, Hôpital Lapeyronie, CHU Montpellier
371, avenue du Doyen Gaston Giraud
34295 Montpellier cedex 5
France

hugobarret89@gmail.com

ABSTRACT

Background: In palliative surgery on the distal radio-ulnar joint (DRUJ), ulnar head resection and the Sauvé-Kapandji procedure are often followed by instability and radio-ulnar convergence. The objective of this study was to evaluate the stability of the DRUJ after modified matched distal ulnar resection performed alone or with partial or complete wrist arthrodesis.

Hypothesis: A modification of matched distal ulnar resection, consisting in reconstruction of the sixth compartment and dorsalisation of the extensor carpi ulnaris, minimises these complications, regardless of the cause and associated procedures.

Patients and Methods: A single-centre retrospective study was conducted in 46 patients (50 wrists) who underwent modified matched distal ulnar resection. The 50 wrists fell into three groups: total wrist arthrodesis according to Millender, n=21 (TWA group); radius to proximal row arthrodesis, n=17 (RPRA group); and isolated matched distal ulnar resection, n=12 (IMDUR group). Seventy per cent of patients had rheumatoid arthritis. Each patient underwent a clinical and radiographic assessment, with an analysis of radio-ulnar convergence, DRUJ stability, and ulno-carpal impingement, as well as of ulnar translation of the carpus in the IMDUR group.

Results: After the mean follow-up of 8.2 ± 5.4 years, 62% of patients were pain-free, with a mean VAS pain score of 1.3 ± 2.1 , and 90% of patients said they would have the procedure again. Clinical and radiographic instability due to excessively proximal resection was noted in 2 (4%) wrists, of which 1 required repeat surgery. Ulno-carpal impingement due to excessively distal resection occurred in 2 (4%) wrists. No significant ulnar translation of the carpus was noted in the IMDUR group (DiBenedetto: 0.011 ± 1.9). Range of motion was

similar in the three groups (mean pronation = $77^{\circ}\pm 17^{\circ}$; and mean supination = $79^{\circ}\pm 8^{\circ}$) ($p>0.05$). Mean grip strength was $85\pm 35\%$ compared to the other side.

Discussion: Our modification of matched distal ulnar resection minimises the complications specific of other ulnar head resection techniques or of the Sauvé-Kapandji procedure, namely, radio-ulnar convergence and DRUJ instability.

Level of proof: IV; retrospective comparative study

Key words: Distal radioulnar joint, matched ulnar head resection, instability, convergence, rheumatoid arthritis

INTRODUCTION

Distal radio-ulnar joint (DRUJ) arthropathy with or without instability, whether due to trauma, inflammatory joint disease, or primary osteoarthritis, is the most common cause of pain on the ulnar side of the wrist.¹ When medical treatment fails and conservative surgery of the DRUJ is contraindicated, there is no consensus regarding the best type of palliative surgery. Darrach's procedure,²⁻⁴ consisting in total resection of the distal ulna starting just proximal to the sigmoid notch is classically recommended for patients with limited physical demands.⁵ However, this procedure may be followed by a number of complications responsible for pain, loss of strength, ulnar stump instability, impingement due to ulno-carpal convergence, and ulnar translation of the carpus. The hemiresection-interposition procedure described by Bowers⁶⁻⁸ requires an intact or reconstructed triangular fibrocartilage complex (TFCC), which is rarely the case in patients with post-traumatic sequelae or inflammatory joint disease. The Sauvé-Kapandji technique⁹⁻¹¹ also carries a risk of instability and of radio-ulnar convergence of the proximal stump (proximal resection of the ulna for intentional non-union). Implant arthroplasty techniques have been evaluated in only small numbers of patients with limited follow-up and complication rates in excess of 10%.^{5, 12-16}

Matched distal ulnar resection as described by Watson^{17,18} consists in resecting the distal ulna along an oblique curve starting just under the upper rim of the sigmoid notch. The remaining ulnar bone is sufficiently long to facilitate DRUJ stabilisation. We have modified the initial technique in two ways. To further stabilise the DRUJ, we reconstruct the sixth compartment via dorsalisation of the extensor carpi ulnaris (ECU) using the extensor retinaculum. We also minimise the risk of radio-ulnar convergence by performing an oblique cut parallel to the distal radius.

The objective of this study was to evaluate the stability of the DRUJ after modified matched distal ulnar resection performed alone or with partial or complete wrist arthrodesis. The working hypothesis was that the post-operative outcomes would be satisfactory and stable over time, without radio-ulnar convergence or instability, regardless of the cause and of the other procedures performed at the wrist.

PATIENTS AND METHODS

This single-centre retrospective study was approved by the appropriate ethics committee. Between January 2003 and January 2017, 77 wrists in 71 patients were managed for DRUJ arthropathy. These wrists met the study inclusion criteria: symptomatic radio-clinical DRUJ arthropathy managed by modified matched distal ulnar resection and followed-up clinically and radiologically for at least 2 years. Of the 71 patients, 8 had died, 9 were lost to follow-up, and 8 were contacted by telephone and said their outcome was satisfactory but they were not willing to come in for a follow-up visit (Figure 1). This left 46 patients with 50 wrists for the study (Table 1). We divided the 50 wrists into three groups (Figure 2) depending on the procedure performed: total wrist arthrodesis according to Millender¹⁹ (bilateral in 2 patients), n=21 (TWA group); radius-to-proximal row (lunate bone with or without the scaphoid bone) arthrodesis (bilateral in 1 patient), n=17 (RPRA group); and isolated matched distal ulnar resection (bilateral in 1 patient), n=12 (IMDUR group).

Overall mean age was 58.9±12 years, and 52% of patients were still in work. The dominant limb was affected in 70% of cases (Table 1). There was a predominance of females except in the RPRA group. The cause was rheumatoid arthritis in 81% of patients in the TWA group and 83% in the IMDUR group. In the RPRA group, 76% of patients had post-traumatic sequelae.

Operative technique

All patients had surgery performed by three experienced surgeons. The patients were supine with an axillary pad and the arm on a table extension. A dorsal longitudinal paramedian incision was performed over the radio-ulnar joint line, or in the middle of the wrist in patients with arthrodesis. The dorsal branch of the ulnar nerve was identified and protected. The extensor retinaculum was opened at the level of the sixth compartment and lifted to the fifth compartment in the RPRA and IMDUR groups and to the second compartment in the TWA group. The DRUJ arthrotomy incision was vertical, and the joint capsule was preserved. The long oblique resection of the ulnar head was performed using an oscillating saw. The cut started at the lateral edge of the ulna, proximal to the sigmoid notch, and ended distally at the medial edge of the ulna opposite the lower portion of the sigmoid notch. A gouge forceps was used to shape the edges of the cut while preserving the distal stabilising structures. The height of the ulnar resection was then checked by fluoroscopy. The dorsal DRUJ capsule was closed by three U-shaped Vicryl 2.0 stitches. A square-tipped awl was used to lower the ulna. In addition to the procedure as described by Watson,^{17,18} we reconstructed the floor of the sixth compartment by suturing the extensor retinaculum to its ulnar boundary. A slip of extensor retinaculum was kept to stabilise and dorsalise the extensor carpi ulnaris. Care was taken to check that the tendon could slide freely in the neo-tunnel (Figure 3). Total wrist arthrodesis or radius-to-proximal row arthrodesis was performed during the same operation. Several other procedures were performed concomitantly as needed during the same operation (Table 1).

Evaluation

All patients were re-evaluated by an independent observer who followed a standardised clinical and radiological procedure.

Stability of the DRUJ was assessed clinically using three methods. First, the patient evaluated DRUJ stability using a 10-point scale (0, stable; 10, very unstable) and reported any snapping sensations during activities. Second, the anterior-posterior drawer test was used to objectively assess stability comparatively to the unaffected wrist. Third, the patient was asked to carry a weight of 2 kg, and any pain during this manoeuvre was recorded.²⁰

DRUJ convergence was evaluated on an anterior-posterior radiograph taken with the hand in a clenched fist. DRUJ subluxation with malalignment of the joint on the lateral view was evaluated by comparison with the unaffected side. The lateral view was considered properly taken if the head of the capitate bone projected between the two horns of the lunate bone centred under the radius.²¹

The following subjective clinical parameters were assessed: the Subjective Wrist Value (SWV),²² pain on a 10-point scale, satisfaction on a 100-point scale, and whether the patient would be willing to undergo the same procedure again. We recorded whether the patient had returned to work or resumed former manual activities. Range of motion was measured, as well as palmar grasp strength (Jamar[®] dynamometer). The Mayo Wrist Score (MWS)²³ was determined. Ulnar translation of the carpus, a classical complication of Darrach-type ulnar head resections, was assessed in the IMDUR group by determining the change in the DiBenedetto index^{20,24} between the immediate post-operative period and last follow-up.

Statistical analysis

Continuous variables were described by their means \pm SD. Mann-Whitney's U test was applied to compare two groups of patients. Values of *p* below 0.05 were taken to indicate

significant differences. Contingency tables were analysed using Pearson's chi-square test ($n > 5$) or Fisher's exact test ($n < 5$).

RESULTS

After the mean follow-up of 8.2 ± 5.4 years (RPRA, 12.4 ± 5.8 years; TWA, 6.6 ± 3.2 years; and IMDUR, 6 ± 4 years), two wrists showed clinical and radiographic instability (Tables 2 and 3; 1 in the IMDUR group and 1 in the TWA group) due to an excessively proximal ulnar cut (Figure 4), while pre-operatively the DRUJ was subluxated in 50% of cases. The symptoms in these two wrists consisted in an occasional snapping sensation, a feeling of instability, and pain upon lifting a 2-kg weight. These symptoms were not present in any of the other wrists.

The clenched-fist radiographs showed ulnar convergence in only 2 (4%) wrists (Table 3). These were the two above-mentioned wrists with instability and subluxation.

Ulnocarpal impingement occurred in 2 wrists (1 in the TWA group and 1 in the RPRA group (Figure 5) due to an excessively distal ulnar cut. Both patients reported pain. The distal end of the ulna was below the lower edge of the sigmoid notch.

A single patient requested further surgery to correct instability (revision rate, 2%). Despite the revision, he continued to experience moderate pain and a slight feeling of instability. The radiographs showed that ulnar carpal translocation was not significant in the IMDUR group ($p > 0.05$).

The clinical outcomes were similar in the three groups (Table 2). At last follow-up, 72% of patients had no pain from the DRUJ, as shown by the low VAS pain scores (TWA group, 1.5 ± 2.4 ; RPRA group, 1.1 ± 2.4 ; and IMDUR group, 1.4 ± 2.3). Ninety per cent of patients would be willing to have the same procedure again, and the overall satisfaction rate was

77%±20%. A sensation of weakness when grasping objects was reported by 36% of patients, half of whom were in the IMDUR group.

Mean pronation was 77°±17° and mean supination was 79°±8° (Table 4). The ranges of supination and pronation compared to the unaffected side (in percentages) showed no differences across the three groups.

Compared to the unaffected side, mean grasp strength was 85°±35% (Table 4). The MWS showed no significant differences across the three groups.

DISCUSSION

No consensus exists regarding which palliative procedure is best to treat symptomatic DRUJ arthropathy with or without instability and/or ulno-carpal impingement.⁵ After arthroplasty involving partial or total ulnar head resection, as well as after the Sauvé-Kapandji procedure, common complications include radio-ulnar instability and radio-ulnar convergence.⁵ Less common complications are ulnar carpal translocation after ulnar head resection and re-ossification or radio-ulnar pseudo-arthrodesis after the Sauvé-Kapandji procedure.^{10,11}

Zimmerman et al.⁵ reported that ulnar convergence occurred after high ulnar head resection in 74% of cases with the Sauvé Kapandji²⁵ or Darrach²⁶ procedure. In a study of the various palliative techniques available for the DRUJ, Minami et al.²⁷ found ulnar instability in 60%, 50%, and 20% of cases after the Darrach procedure, Sauvé-Kapandji, procedure, and Bowers procedure, respectively. Mansat et al.⁴ conducted a case-series in patients with post-traumatic DRUJ arthropathy managed using the Darrach procedure and reported no cases of instability or convergence. However, they did not test the stability of the DRUJ comparatively

to the unaffected side or while lifting a weight, and the radiographic workup included neither a stress view nor an analysis of DRUJ subluxation on the lateral view.

Techniques for stabilising the distal⁴ or proximal¹¹ stump have been described. However, they complicate the operation and carry their own complications (e.g., fractures). In addition, they neither consistently stabilise the ulnar stump nor always eliminate the pain.¹¹

The complication rate in our study was extremely low. Thus, clinical instability, even during the weight-lifting test, occurred in only 4% of wrists. The radiographs showed subluxation with convergence in only 4% of cases, whereas the rate of subluxation was 50% pre-operatively. The revision rate was only 2% (1 patient).

Stability of the DRUJ is due not only to the TFCC but also to other stabilisers: the lower part of the interosseous membrane, the sheath of the extensor carpi ulnaris with the floor of the sixth compartment, the anterior ulno-carpal ligaments, and the pronator quadratus muscle.²⁸ During the Darrach procedure and the Sauvé-Kapandji procedure, the proximal resection of the ulna starts high up on the bone, at or above the upper edge of the sigmoid notch of the radius. The only parts of the proximal ulna that are preserved are the insertions of the lower portion of the interosseous membrane and of the proximal part of the pronator quadratus muscle. The partial distal resection described by Bowers⁶⁻⁸ requires that the TFCC be intact or amenable to reconstruction, which is rarely the case in patients with post-traumatic arthropathy or inflammatory joint disease. In matched distal ulnar resection,^{17,18} the proximal resection of the ulna down to the lower edge of the sigmoid notch allows the use of nearly the entire extensor retinaculum. The retinaculum serves to cover and stabilise the distal ulnar stump, to reconstruct the floor of the sixth compartment, to dorsalise the extensor carpi ulnaris, and to complete the suture of the DRUJ capsule. With the Darrach and Sauvé-Kapandji procedures, the proximal ulnar stump is covered only very incompletely or not at all

by the extensor retinaculum, which projects opposite the ulnar head and triquetral bone and therefore cannot be used satisfactorily.

Technical errors involving the level of ulnar resection caused the 2 cases of instability, which were due to excessively proximal ulnar resection. Similarly, the 2 cases of ulno-carpal impingement involving the distal ulna and the triquetral bone were due to insufficient ulnar resection.

The clinical outcomes in our population are consistent with those produced by other techniques in terms of pain, range of motion, and functional scores.²³ The pronation-supination arc was more than 90° of that on the unaffected side. Palmar grasp strength was more than 80° of that on the other side. Given the complexity of the wrist lesions (rheumatoid arthritis, post-traumatic sequelae), the functional scores were satisfactory (MWS >60). The subjective outcomes were excellent, with over 90% of patients being willing to have the procedure again and a satisfaction rate of 77%±20%. Complex regional pain syndrome occurred in a single patient. Furthermore, 52% of patients were still in work at last follow-up. Among the retired patients, 69% engaged in manual activities.

No significant ulnar translocation occurred in our patients, among whom over half had rheumatoid arthritis. Ulnar translocation is a classic complication after ulnar head resection in patients with rheumatoid arthritis.

One of the limitations of our study is that the three groups were not comparable in terms of aetiologies, sex, concomitant surgical procedures, and follow-up duration. Furthermore, we used a retrospective single-centre design with no comparison to another surgical technique. The proportion of patients who were lost to follow-up or were not re-evaluated was 32%. Nevertheless, our finding that stability was comparable among the three groups, regardless of the aetiology, demonstrates the usefulness of our technique in a variety of settings. Furthermore, we had a large number of patients with long follow-ups.

In most (76%) patients, partial or total wrist arthrodesis was performed during the same operation. Arthrodesis may improve the stability of the DRUJ. Nevertheless, DRUJ instability can persist after surgery on the rheumatoid wrist and can be responsible for tendon ruptures.²⁹

In conclusion, matched distal ulnar resection that starts below the upper edge of the sigmoid notch,^{17,18} modified by the addition of sixth compartment floor reconstruction and extensor carpi ulnaris dorsalisation, minimises the complications specific of other ulnar head resection techniques and of the Sauvé-Kapandji procedure, namely radio-ulnar convergence and DRUJ instability.

Conflicts of interest

None of the authors has any conflicts of interest to declare.

Funding

No funding was received for this work.

Contributions of each author

All authors contributed to collect and analyse the data, draft the manuscript, and revise the manuscript for important intellectual content. All authors read and approved the final version of the manuscript.

References

1. Faucher GK¹, Zimmerman RM, Zimmerman NB. Instability and Arthritis of the Distal Radioulnar Joint: A Critical Analysis Review. *JBJS Rev.* 2016 Dec 20;4(12). doi: 10.2106/JBJS.RVW.16.00005.
2. Darrach W. Partial excision of lower shaft of ulna for deformity following Colles's fracture. 1913. *Clin Orthop Relat Res.* 1992 Feb
3. Grawe B¹, Heincelman C, Stern P. Functional results of the Darrach procedure: a long-term outcome study. *J Hand Surg Am.* 2012 Dec;37(12):2475-80.e1-2. doi: 10.1016/j.jhsa.2012.08.044.
4. Mansat P, Ayel JE, Bonneville N, Rongièrès M, Mansat M, Bonneville P. Long-term outcome of distal ulna resection-stabilisation procedures in post-traumatic radio-ulnar joint disorders. *Orthop Traumatol Surg Res.* 2010 May;96 doi: 10.1016/j.otsr.2009.12.009.
5. Zimmerman RM, Kim JM, Jupiter JB. Arthritis of the distal radioulnar joint: from Darrach to total joint arthroplasty. *J Am Acad Orthop Surg.* 2012 Oct;20(10):623-32. doi: 10.5435/JAAOS-20-10-623.
6. Bowers WH. Distal radioulnar joint arthroplasty: the hemiresection-interposition technique. *J Hand Surg Am.* 1985 Mar;10(2):169-78.

7. Ahmed SK¹, Cheung JP, Fung BK, Ip WY. Long term results of matched hemiresection interposition arthroplasty for DRUJ arthritis in rheumatoid patients. *Hand Surg.* 2011;16(2):119-25. DOI: 10.1142/S0218810411005217
8. Glowacki KA . Hemiresection arthroplasty of the distal radioulnar joint. *Hand Clin.* 2005 Nov;21(4):591-601. DOI: 10.1016/j.hcl.2005.08.002
9. Kapandji IA. The Kapandji-Sauvé operation. Its techniques and indications in non rheumatoid diseases. *Ann Chir Main.* 1986;5(3):181-93. English, French.
10. Lluch A The sauvé-kapandji procedure. *J Wrist Surg.* 2013 Feb;2(1):33-40. doi: 10.1055/s-0032-1333465.
11. Tomori Y, Sawaizumi T, Nanno M, Takai S. Functional outcomes after the Sauvé-Kapandji procedure for distal radio-ulnar post-traumatic instability: a case-control comparison of three different operative methods of stabilization of the ulnar stump. *Int Orthop.* 2018 Sep;42(9):2173-2179. doi: 10.1007/s00264-018-4042-4.
12. Moulton LS, Giddins GEB. Distal radio-ulnar implant arthroplasty: a systematic review. *J Hand Surg Eur Vol.* 2017 Oct;42(8):827-838. doi: 10.1177/1753193417692506.

13. Kakar S, Swann RP, Perry KI, Wood-Wentz CM, Shin AY, Moran SL. Functional and radiographic outcomes following distal ulna implant arthroplasty. *J Hand Surg Am.* 2012 Jul;37(7):1364-71. doi: 10.1016/j.jhsa.2012.03.026.
14. Rampazzo A, Gharb BB, Brock G, Scheker LR. Functional Outcomes of the Aptis-Scheker Distal Radioulnar Joint Replacement in Patients Under 40 Years Old. *J Hand Surg Am.* 2015 Jul;40(7):1397-1403.e3. doi: 10.1016/j.jhsa.2015.04.028.
15. Scheker LR, Martineau DW. Distal radioulnar joint constrained arthroplasty. *Hand Clin.* 2013 Feb;29(1):113-21. doi: 10.1016/j.hcl.2012.08.023.
16. van Schoonhoven J, Mühldorfer-Fodor M, Fernandez DL, Herbert TJ Salvage of failed resection arthroplasties of the distal radioulnar joint using an ulnar head prosthesis: long-term results. *J Hand Surg Am.* 2012 Jul;37(7):1372-80. doi: 10.1016/j.jhsa.2012.04.028.
17. Watson HK, Ryu JY, Burgess RC. Matched distal ulnar resection. *J Hand Surg Am.* 1986 Nov;11(6):812-7.
18. Watson HK, Gabuzda GM. Matched distal ulna resection for posttraumatic disorders of the distal radioulnar joint. *J Hand Surg Am.* 1992 Jul;17(4):724-30.
19. Millender LH, Nalebuff EA. Arthrodesis of the rheumatoid wrist. An evaluation of sixty patients and a description of a different surgical technique. *J Bone Joint Surg Am.* 1973 Jul;55(5):1026-34.

20. McKee MD, Richards RR. Dynamic radio-ulnar convergence after the Darrach procedure. *J Bone Joint Surg Br.* 1996 May;78(3):413-8.
21. Meyrueis JP, Cameli M, Jan P. Instabilités du carpe. Diagnostic et formes cliniques. *Ann Chir* 1978;32:555-60.
22. Herzberg G, Burnier M, Nakamura T. A New Wrist Clinical Evaluation Score. *J Wrist Surg.* 2018 Apr;7(2):109-114. doi: 10.1055/s-0037-1607328
23. Amadio PC, Berquist TH, Smith DK, Ilstrup DM, Cooney WP 3rd, Linscheid RL. Scaphoid malunion. *J Hand Surg [Am].* 1989 Jul;14(4):679-87
24. DiBenedetto MR, Lubbers LM, Coleman CR. A standardized measurement of ulnar carpal translocation. *J Hand Surg Am.* 1990 Nov;15(6):1009-10. DOI: 10.1016/0363-5023(90)90035-p
25. Zimmermann R, Gschwentner M, Arora R, Harpf C, Gabl M, Pechlaner S. Treatment of distal radioulnar joint disorders with a modified Sauvé-Kapandji procedure: long-term outcome with special attention to the DASH Questionnaire. *Arch Orthop Trauma Surg.* 2003 Jul;123(6):293-8. DOI: 10.1007/s00402-003-0529-5
26. Greenberg JA. Reconstruction of the distal ulna: instability, impaction, impingement, and arthrosis. *J Hand Surg Am.* 2009 Feb;34(2):351-6. doi: 10.1016/j.jhsa.2008.11.016.

27. Minami A, Iwasaki N, Ishikawa J, Suenaga N, Yasuda K, Kato H. Treatments of osteoarthritis of the distal radioulnar joint: long-term results of three procedures. *Hand Surg.* 2005 ; DOI: 10.1142/S0218810405002942
28. Haugstvedt JR, Berglund LJ, Neale PG, Berger RA. A dynamic simulator to evaluate distal radio-ulnar joint kinematics. *J Biomech.* 2001 DOI: 10.1016/s0021-9290(00)00198-6
29. Benoit O¹, Limousin M, Chantelot C, Cordonnier D, Fontaine C, Polveche G. Extensor tendon rupture after dorsal surgery of the rheumatoid wrist: analysis of nine reviewed cases. *Chir Main*, 2003. DOI: 10.1016/s1297-3203(02)00009-4

TABLE TITLES

Table 1: Demographic characteristics, causes, and concomitant procedures

Table 2: Post-operative clinical outcomes

Table 3: Radiographic outcomes

Table 4: Range of motion and functional scores after surgery

Figure legends

Figure 1: Patient flow diagram

Figure 2: Long-term outcomes of partial DRUJ resection

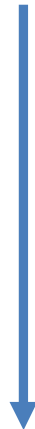Figure 3: Projection of the extensor retinaculum at the wrist. Dorsal view of the wrist. The extensor tendons are in light grey, the extensor retinaculum in dark grey, and the cut through the ulna parallel to the radius according to the original matched distal ulnar resection technique is in red.

Figure 4: Technical error: the partial ulnar resection is too short (instability of the proximal stump)

Figure 5: Technical error: partial resection with an excessively long distal ulnar stump (ulnocarpal impingement)

77 wrists (71 patients) with modified Watson included

(January 2003- January 2017)



8 patients died

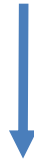



9 patients lost to follow-up



8 patients unwilling to return

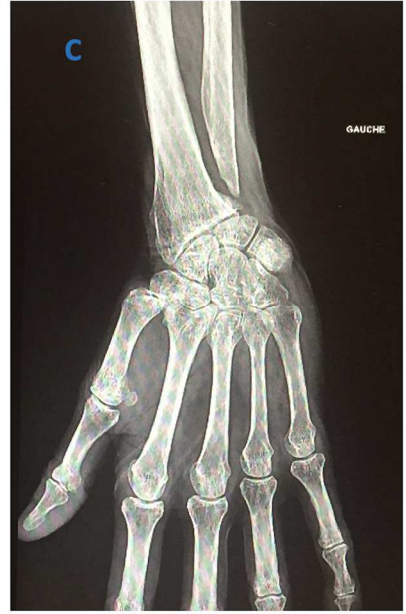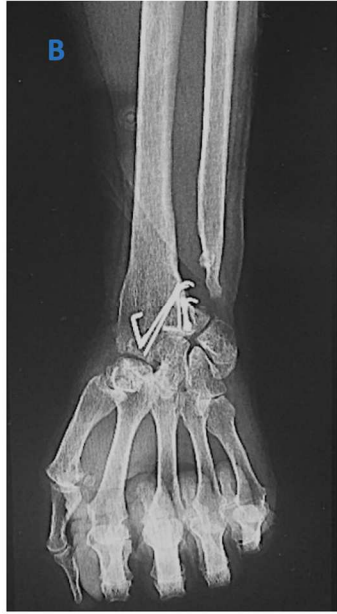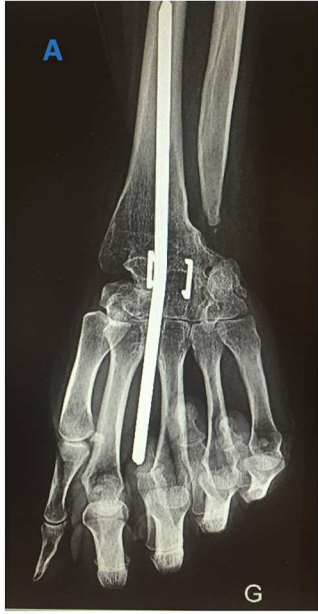50 wrists (46 patients) with modified Watson re-assessed

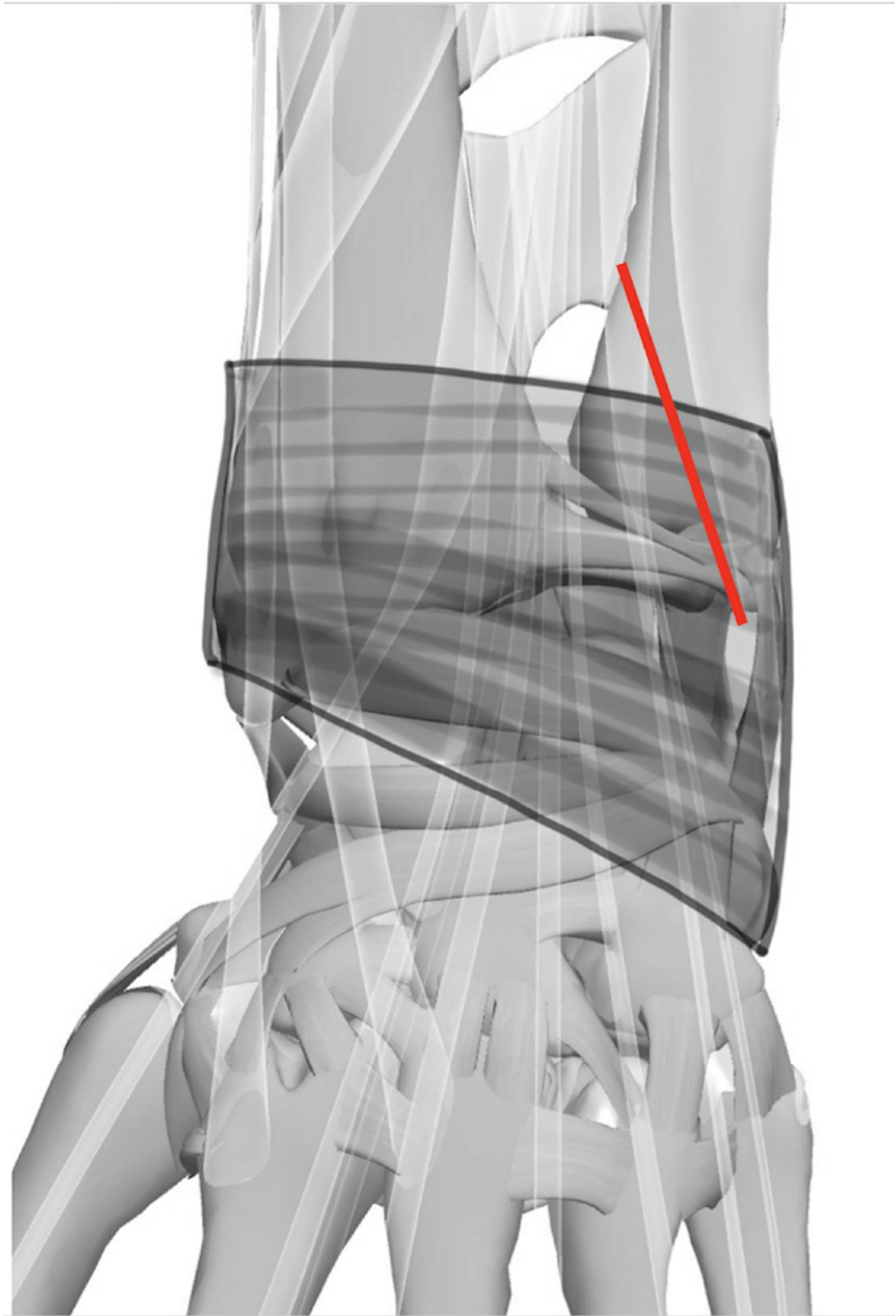


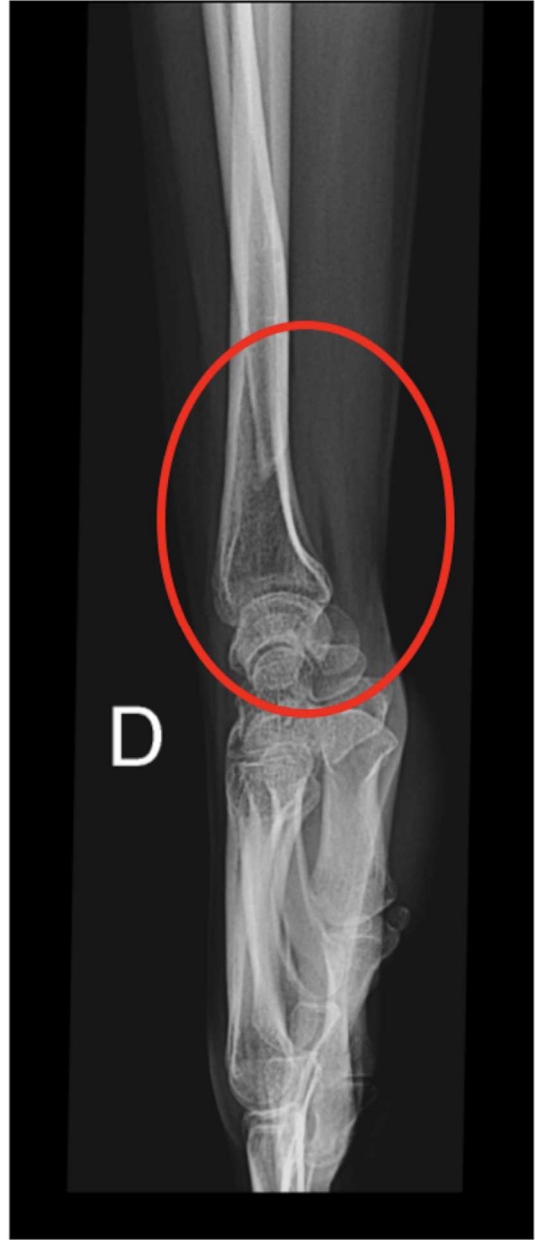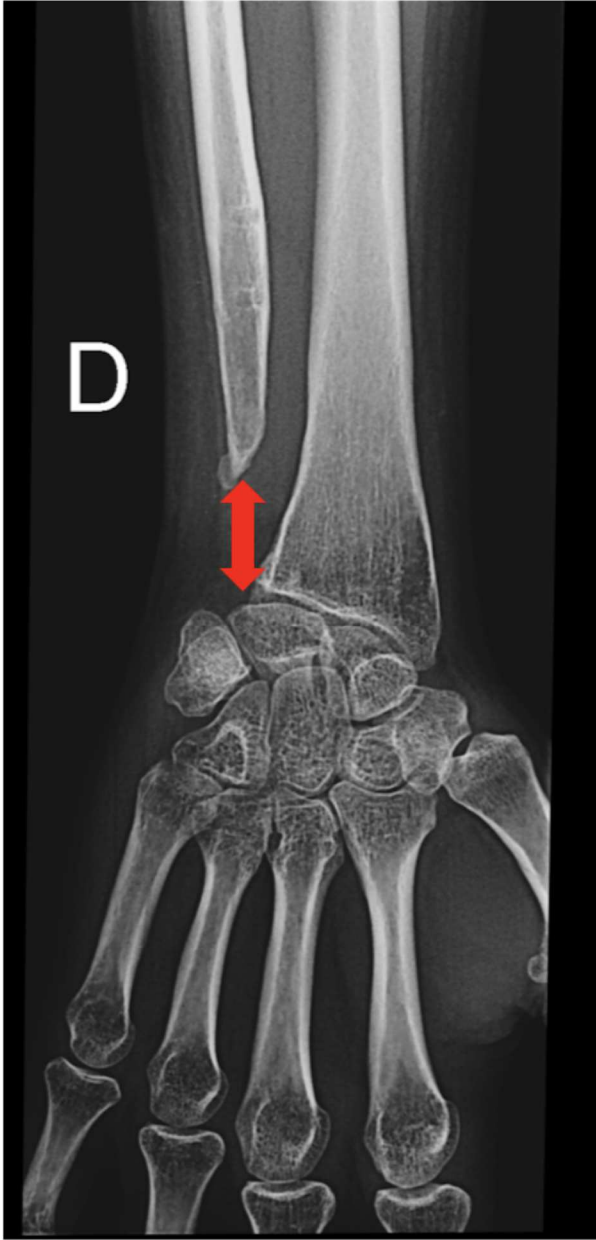
21 A. Total:
TWA Group

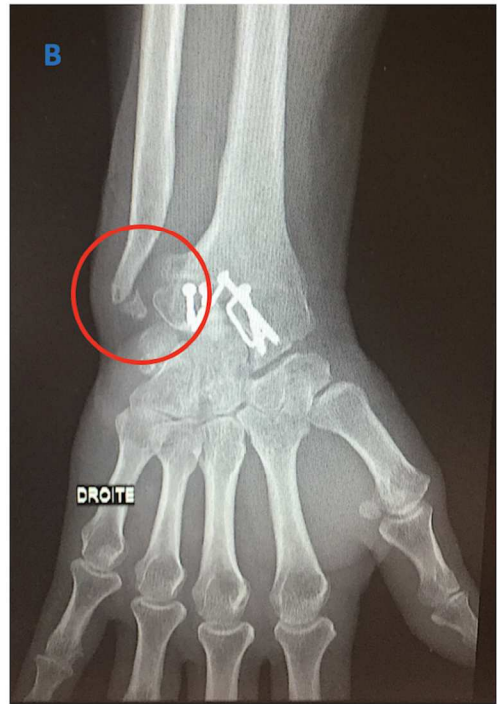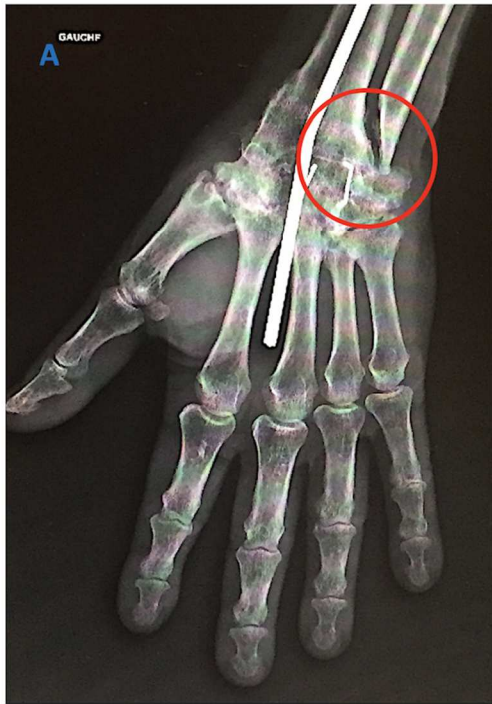17 A. Partial:
RPRA Group

12 isolated modified
Watson:
IMDUR Group









| | Overall (n=50) | TWA (n=21) | RPRA (n=17) | IMDUR (n=12) | p value |
|-------------------------------|-------------------|---------------|-------------|--------------|-------------------|
| Sex : % females | 20/30 ; 60% | 6/15 ; 71% | 13/4 ; 24% | 1/11 ; 92% | 0.002 |
| Age, y, mean±SD | 58.9±12 | 60±11 | 55.5±16 | 53±13 | NS |
| Dominant side | 35 (70%) | 15 (71%) | 11 (65%) | 9 (75%) | NS |
| Bilateral | 5 | 3 | 1 | 1 | NS |
| In work | 26 (52%) | 7 (33%) | 14 (82%) | 5 (42%) | NS |
| Retired, active | 18/26 (69%) | 2/7 (28%) | 13/14 (93%) | 3/5 (60%) | |
| Causes: | | | | | |
| - RA and other IJD | 35 (70%) | 21 (100%) | 4 (24%) | 10 (83%) | < 0.001 |
| - Post-traumatic | 14 (28%) | 0 | 13 (76%) | 1 (8.5%) | |
| - Madelung | 1 (2%) | 0 | 0 | 1 (8.5%) | |
| Concomitant procedures | | | | | |
| - synovectomy | 34 (68%) | 21 (100%) | 3 (18%) | 10 (83%) | <0.001 |
| - suture of an extensor | 11 (22%) | 5 (24%) | 1 (6%) | 5 (42%) | |
| - resection distal scaphoid | 7 (14%) | 0 | 7 (41%) | 0 | |
| - excision of triquetrum | 2 (4%) | 0 | 2 (12%) | 0 | |
| - median nerve release | 2 (4%) | 1 (5%) | 1 (6%) | 0 | |
| - surgery on TMJ | 3 (6%) | 2 (9.5%) | 0 | 1 (8.5%) | |
| - arthrodesis PIPJ | 2 (4%) | 2 (9.5%) | 0 | 0 | |

Tableau 1: Demographic characteristics, causes, and concomitant procedures

TWA: total wrist arthrodesis; RPRA: radius-to-proximal row arthrodesis; IMDUR: isolated matched distal ulnar resection; RA: rheumatoid arthritis; IJD: inflammatory joint disease; TMJ: trapezio-metacarpal joint; PIPJ: proximal interphalangeal joint; NS: not significant

| | Overall (n=50) | TWA (n=21) | RPRA (n=17) | IMDUR (n=12) | <i>p</i> value |
|---|-------------------|---------------|----------------|-----------------|-------------------|
| Wrist VAS score | 1.32±2.1 | 1.5±2.4 | 1.1±1.2 | 1.4±2.3 | NS |
| % patients free of pain | 62% (31/50) | 67% (14/21) | 53% (9/17) | 67% (8/12) | NS |
| SWV difference from pre- to post-operative | 44.3±26.5 | 45.9±33.3 | 43.5±17.1 | 42.5±27.1 | NS |
| Satisfaction | 77.1±19.7 | 74.3±29.2 | 89.7±10.3 | 86.25±16.7 | NS |
| Would have the procedure again | 45/50 (90%) | 18/21 (86%) | 16/17 (94%) | 11/12 (92%) | NS |
| Snapping (%) | 2/50 (4%) | 1/21 (5%) | 0/17 (0%) | 1/12 (8%) | NS |
| Instability (0 to 10) | 0.16±0.6 | 0.15±0.6 | 0 | 0.25±0.8 | NS |
| N of patients with “instability” | 2/50 (4%) | 1/21 (5%) | 0 | 1/12 (8%) | |
| Weakness | 18/50 (36%) | 9/21 (43%) | 3/17 (18%) | 6/12 (50%) | NS |
| Pain (while carrying 2 kg) | 2/50 (4%) | 1/21 (5%) | 0/17 (0%) | 1/12 (8%) | NS |
| CRPS | 2 (4%) | 1 (5%) | 1 (5%) | / | |

Table 2: Post-operative clinical outcomes

TWA: total wrist arthrodesis; RPRA: radius-to-proximal row arthrodesis; IMDUR: isolated matched distal ulnar resection; VAS, visual analogue scale for pain; SWV, Subjective Wrist Score; CRPS, complex regional pain syndrome; NS, not significant ($p>0.05$)

| | Overall (n=50) | TWA (n=21) | RPRA (n=17) | IMDUR (n=12) |
|--|-------------------|---------------|----------------|-----------------|
| Follow-up (years) | 8.4±5.2 | 6.6±3.2 | 12.4±5.8 | 6±4 |
| Ulnocarpal impingement | 2 (4%) | 1 (5%) | 1 (5%) | / |
| Instability with DRUJ convergence | 2 (4%) | 1 (5%) | / | 1 (5%) (*) |
| Ossification of the TFCC | 2 (4%) | / | 1 (5%) | 1 (8%) |
| Di Benedetto change (last FU) - (post op) | / | / | / | -0.011 +/- 1.9 |
| Pre-operative DRUJ subluxation | 25/50 (50%) | 11/21 (52%) | 7/17 (41%) | 7/12 (58%) |
| Post-operative DRUJ subluxation | 0 | 1 | 0 | 1 |

Tableau 3: Radiographic outcomes

TWA: total wrist arthrodesis; RPRA: radius to proximal row arthrodesis; IMDUR: isolated matched distal ulnar resection; DRUJ: distal radio-ulnar joint; TFCC; triangular fibrocartilage complex; FU, follow-up; post op: post-operative

(*) Revision surgery to stabilise the stump using the flexor carpi ulnaris muscle

| | Overall (n=50) | TWA (n=21) | RPRA (n=17) | IMDUR (n=12) | <i>p</i> value |
|---|-------------------|---------------|----------------|-----------------|----------------|
| Pronation (°) | 76.6±5.9 | 74+/-6.4 | 79.4±4 | 77.1±3.2 | NS |
| Pronation relative to the unaffected side (%) | 93.8±6.2 | 93.8±26.1 | 94.7±7.9 | 93.5±5.8 | NS |
| Supination (°) | 78.6±8.7 | 76.4±8.4 | 79.7±8.6 | 80.8±7.3 | NS |
| Supination relative to the unaffected side (%) | 93.5±11.7 | 93.4±27.2 | 94.9±28 | 95.2±7.1 | NS |
| Grasp strength relative to the unaffected side (%) | 85.4±35.1 | 85.4±34.3 | 78.5±26.7 | 87.4±26.7 | NS |
| MWS | 60.7±13.8 | 60.7±14 | 77.3±14 | 67.1±15.2 | NS |

Table 4: Range of motion and functional scores after surgery

TWA: total wrist arthrodesis; RPRA: radius to proximal row arthrodesis; IMDUR: isolated matched distal ulnar resection; MWS: Mayo Wrist Score; NS, not significant ($p>0.05$)