



**HAL**  
open science

## **Clinical and biological features in PIEZO1-hereditary xerocytosis and Gardos channelopathy: a retrospective series of 126 patients**

Veronique Picard, Corinne Guitton, Isabelle Thuret, Christian Rose, Laurence Bendelac, Kaldoun Ghazal, Patricia Aguilar-Martinez, Catherine Badens, Claire Barro, Claire Bénéteau, et al.

### ► To cite this version:

Veronique Picard, Corinne Guitton, Isabelle Thuret, Christian Rose, Laurence Bendelac, et al.. Clinical and biological features in PIEZO1-hereditary xerocytosis and Gardos channelopathy: a retrospective series of 126 patients. *Haematologica*, 2019, 104 (8), pp.1554-1564. <10.3324/haematol.2018.205328>. <hal-02929666>

**HAL Id: hal-02929666**

**<https://hal.umontpellier.fr/hal-02929666v1>**

Submitted on 3 Sep 2020

HAL is a multi-disciplinary open access archive for the deposit and dissemination of scientific research documents, whether they are published or not. The documents may come from teaching and research institutions in France or abroad, or from public or private research centers.

L'archive ouverte pluridisciplinaire HAL, est destinée au dépôt et à la diffusion de documents scientifiques de niveau recherche, publiés ou non, émanant des établissements d'enseignement et de recherche français ou étrangers, des laboratoires publics ou privés.



HAL Authorization



Ferrata Storti Foundation

## Clinical and biological features in *PIEZO1*-hereditary xerocytosis and Gardos channelopathy: a retrospective series of 126 patients

Véronique Picard,<sup>1,2</sup> Corinne Guitton,<sup>3</sup> Isabelle Thuret,<sup>4</sup> Christian Rose,<sup>5</sup> Laurence Bendelac,<sup>1</sup> Kaldoun Ghazal,<sup>6</sup> Patricia Aguilar-Martinez,<sup>7</sup> Catherine Badens,<sup>8</sup> Claire Barro,<sup>9</sup> Claire Bénéteau,<sup>10</sup> Claire Berger,<sup>11</sup> Pascal Cathébras,<sup>12</sup> Eric Deconinck,<sup>13</sup> Jacques Delaunay,<sup>14</sup> Jean-Marc Durand,<sup>15</sup> Nadia Firaah,<sup>16</sup> Frédéric Galactéros,<sup>17</sup> Bertrand Godeau,<sup>18</sup> Xavier Jaïs,<sup>19</sup> Jean-Pierre de Jaureguiberry,<sup>20</sup> Camille Le Stradic,<sup>21</sup> François Lifermann,<sup>22</sup> Robert Maffre,<sup>1</sup> Gilles Morin,<sup>23</sup> Julien Perrin,<sup>24</sup> Valérie Proulle,<sup>1</sup> Marc Ruivard,<sup>25</sup> Fabienne Toutain,<sup>26</sup> Agnès Lahary<sup>27</sup> and Loïc Garçon<sup>1,28</sup>

**Haematologica** 2019  
Volume 104(8):1554-1564

<sup>1</sup>Laboratoire d'Hématologie, Center Hospitalier Universitaire (CHU) Bicêtre, Assistance publique – Hôpitaux de Paris (AP-HP), Le Kremlin-Bicêtre; <sup>2</sup>Université Paris Sud Paris Saclay, Faculté de Pharmacie, Chatenay Malabry; <sup>3</sup>Service de Pédiatrie Générale, CHU Bicêtre et Filière MCGRE, AP-HP, Le Kremlin-Bicêtre; <sup>4</sup>Service de Pédiatrie, Hôpital La Timone, Aix Marseille University, Marseille; <sup>5</sup>Service d'Oncologie et d'Hématologie, Hôpital Saint Vincent de Paul, Lille; <sup>6</sup>Laboratoire de Biochimie, CHU Bicêtre, AP-HP, Le Kremlin-Bicêtre; <sup>7</sup>Laboratoire d'Hématologie Biologique, CHU Saint-Eloi, Montpellier; <sup>8</sup>Service de Génétique Médicale, Hôpital La Timone, Marseille; <sup>9</sup>Laboratoire d'Hématologie Biologique, CHU Grenoble, Grenoble; <sup>10</sup>Génétique Médicale, CHU Nantes, Nantes; <sup>11</sup>Service d'Hématologie-Oncologie Pédiatrique, CHU, Saint-Etienne; <sup>12</sup>Service de Médecine Interne, CHU Saint-Etienne; <sup>13</sup>Service d'Hématologie, CHU Jean Minioz, Besançon; <sup>14</sup>Centre Catherine de Sienne, Nantes; <sup>15</sup>Service de Médecine Interne, Hôpital La Timone, Marseille; <sup>16</sup>Service de Pédiatrie, Centre Hospitalière (CH) Pau; <sup>17</sup>Centre de Référence des Syndromes Drépanocytaires Majeurs, Hôpital Henri-Mondor, AP-HP, Créteil; <sup>18</sup>Service de Médecine Interne, CHU Henri Mondor, AP-HP, Créteil; <sup>19</sup>Service de Pneumologie, CHU Bicêtre, AP-HP, Le Kremlin-Bicêtre; <sup>20</sup>Service de Médecine Interne, Sainte Anne, Toulon; <sup>21</sup>Service de Pédiatrie – Néonatalogie, CH de Bretagne Sud, Lorient; <sup>22</sup>Service de Médecine interne, CH Dax; <sup>23</sup>Génétique Médicale, CHU Amiens; <sup>24</sup>Laboratoire d'Hématologie, CHRU Nancy; <sup>25</sup>Service de Médecine Interne, CHU Estaing, Clermont-Ferrand; <sup>26</sup>Service d'Hémo-Oncologie Pédiatrique, CHU Sud, Rennes; <sup>27</sup>Laboratoire d'Hématologie, CHU Rouen and <sup>28</sup>Equipe d'Accueil 4666 HEMATIM Université de Picardie Jules Verne and Service d'Hématologie Biologique, CHU Amiens, France

### Correspondence:

LOÏC GARÇON  
Garcon.Loic@chu-amiens.fr

Received: September 4, 2018.

Accepted: January 15, 2019.

Pre-published: January 24, 2019.

doi:10.3324/haematol.2018.205328

Check the online version for the most updated information on this article, online supplements, and information on authorship & disclosures: [www.haematologica.org/content/104/8/1554](http://www.haematologica.org/content/104/8/1554)

©2019 Ferrata Storti Foundation

Material published in *Haematologica* is covered by copyright. All rights are reserved to the Ferrata Storti Foundation. Use of published material is allowed under the following terms and conditions:

<https://creativecommons.org/licenses/by-nc/4.0/legalcode>. Copies of published material are allowed for personal or internal use. Sharing published material for non-commercial purposes is subject to the following conditions: <https://creativecommons.org/licenses/by-nc/4.0/legalcode>, sect. 3. Reproducing and sharing published material for commercial purposes is not allowed without permission in writing from the publisher.



### ABSTRACT

We describe the clinical, hematologic and genetic characteristics of a retrospective series of 126 subjects from 64 families with hereditary xerocytosis. Twelve patients from six families carried a *KCNN4* mutation, five had the recurrent p.Arg352His mutation and one had a new deletion at the exon 7-intron 7 junction. Forty-nine families carried a *PIEZO1* mutation, which was a known recurrent mutation in only one-third of the cases and private sequence variation in others; 12 new probably pathogenic missense mutations were identified. The two dominant features leading to diagnosis were hemolysis that persisted after splenectomy and hyperferritinemia, with an inconstant correlation with liver iron content assessed by magnetic resonance imaging. *PIEZO1*-hereditary xerocytosis was characterized by compensated hemolysis in most cases, perinatal edema of heterogeneous severity in more than 20% of families and a major risk of post-splenectomy thrombotic events, including a high frequency of portal thrombosis. In *KCNN4*-related disease, the main symptoms were more severe anemia, hemolysis and iron overload, with no clear sign of red cell dehydration; therefore, this disorder would be better described as a ‘Gardos channelopathy’. These data on the largest series to date indicate that *PIEZO1*-hereditary xerocytosis and Gardos channelopathy are not the same disease although they share hemolysis, a high rate of

iron overload and inefficient splenectomy. They demonstrate the high variability in clinical expression as well as genetic bases of *PIEZO1*-hereditary xerocytosis. These results will help to improve the diagnosis of hereditary xerocytosis and to provide recommendations on the clinical management in terms of splenectomy, iron overload and pregnancy follow-up.

## Introduction

Hereditary stomatocytoses are dominant red cell membrane disorders characterized by an increased cation leak through the membrane and a subsequent alteration in cell hydration.<sup>1,2</sup> Also called hereditary xerocytosis (HX) (MIM #194380), dehydrated stomatocytosis is the most frequent of these disorders, with an estimated incidence of 1:50000 births.<sup>3,4</sup> It is characterized by chronic hemolysis<sup>5</sup> as well as non-hematologic features including transient perinatal edema, pseudohyperkalemia,<sup>6</sup> iron overload<sup>7</sup> and post-splenectomy thromboembolic complications<sup>8</sup> that often dominate the phenotype and delay the diagnosis. In addition, diagnosis is complex because of the lack of an easily available biological test. Osmotic gradient ektacytometry is the most efficient diagnostic tool so far,<sup>9</sup> showing a typical left-shifted curve with increased osmotic resistance. However, it is only performed in a few specialized laboratories.

HX is most often caused by gain-of-function mutations in *PIEZO1* which encodes a mechanosensitive ion channel that translates a mechanic stimulus into an increased intracellular calcium concentration.<sup>10–12</sup> Recent reports have shown that *PIEZO1* mutants induce an inappropriate increase in intracellular Ca<sup>2+</sup> which in turn activates the Gardos channel inducing potassium leak, water loss and consequently erythrocyte dehydration.<sup>13</sup> Of note, erythrocyte dehydration related to *PIEZO1* gain-of-function mutations has also been associated with protection against malaria.<sup>14</sup> In HX, it can be assumed that *PIEZO1* mutations lead to a stronger dehydration and subsequently to hemolysis. Besides *PIEZO1* mutations, gain-of-function mutations in *KCNN4*, encoding the Gardos channel, directly cause another subset of HX.<sup>15,16</sup>

Up to now, with the exception of a recent report,<sup>17</sup> the clinical and biological features of HX have been mostly described in small series. Large-scale clinical and biological descriptions at diagnosis and comparisons with the underlying genotypes are required. We report here a retrospective study describing the clinical and biological features in the largest series to date including 126 patients from 64 families with HX diagnosed based on ektacytometry and/or genetics between 1993 and 2017.

## Methods

### Patients and data collection

This retrospective cohort included 126 patients from 64 apparently unrelated families who were diagnosed with HX when tested for red cell membrane diseases in a context of chronic hemolysis after elimination of other causes such as hemoglobinopathies except otherwise mentioned, at the hematology laboratory of Bicêtre hospital, between 1993 and 2017. The study was conducted according to French ethics regulations regarding retrospective, non-interventional studies. Data were collected directly from clinical

records and through the French Cohort of Hereditary Stomatocytosis, declared to the French National Commission on Informatics and Liberty. Twenty families have been previously reported and are presented here with complementary phenotypic or genotypic data.<sup>10,11,13,15,18,19</sup>

### Phenotypic red cell analysis

Red blood cell analyses were performed in the same laboratory and were processed within 24 h after blood drawing and transport at 4°C. Cell counts, red cell and reticulocyte indices were measured using an ADVIA2120 analyzer (Siemens®). Blood smears were observed after May-Grünwald-Giemsa staining using standard methods. Screening for red cell membrane disorders was performed by osmotic gradient ektacytometry, as previously described.<sup>20–22</sup>

### Gene analysis

Genetic analysis was performed with informed consent according to the Declaration of Helsinki. Genomic DNA was extracted from blood samples collected on EDTA using the QIAamp or QIASymphony DSP Midi blood DNA extraction kit (Qiagen®). The *PIEZO1* and *KCNN4* coding exons and exon-intron boundaries were sequenced as described in the *Online Supplementary Data*. Each sequence variation with an allele frequency under 5% in the GnomAD v2.0.1 database was recorded. Family studies were performed when possible and pathogenicity scores were calculated using various bioinformatic software (SIFT 6.2.0, Mutation Taster 2013, Polyphen-2 2.2.6). The predicted pathogenicity is described in Table 1.

### Statistical analysis

Statistical analyses were performed using parametric tests with two-tailed *P* values. Statistical significance used was  $\alpha=0.05$ . We used the Student *t*-test for quantitative variables. All numerical values are expressed as mean values  $\pm$  standard error of mean.

## Results

### Patients and clinical features at diagnosis

We identified 126 patients with HX, including 64 probands and 62 family members, between 1993 and 2017. The diagnosis of HX was based on clinical phenotype, red cell parameters and morphology, a normal eosin-5-maleimide (EMA) binding test and a typical osmotic gradient ektacytometry curve for 103 patients, and genetic testing with non-typical or normal ektacytometry for 12 patients. Eleven patients presenting typical clinical or biological features and belonging to families with genetically proven HX were also included although they had no ektacytometry or genetic analysis.

For probands, the mean age at diagnosis was 32 $\pm$ 18 years ( $n=64$ ), with the range extending from the perinatal period to more than 88 years old (Figure 1A). Clinical and biological features at diagnosis were comparable between probands and family members including mainly non-

spherocytic chronic hemolysis in 84% of all cases, hyperferritinemia (36%), thrombosis after splenectomy (11%), and perinatal edema in 17% of all cases (Figure 1B).

Cholelithiasis was noted in 52% of cases (n=67) with the incidence increasing with age: 22% before 20 years old (n=23), 62% between 20 and 40 years (n=29) and 80% after 40 years (n=15). Splenomegaly was noted at diagnosis in 56% of cases (n=47): 67% before the age of 20 years vs. 51% after the age of 40 years. The mean bilirubin and haptoglobin levels were, respectively,  $2.5 \pm 1.4$  mg/dL (n=36) and  $0.28 \pm 0.24$  g/L (n=24), among whom only nine had a level  $< 0.1$  g/L. All other notable medical issues are listed in *Online Supplementary Table S1*.

### Biological diagnosis and genetic testing in hereditary xerocytosis

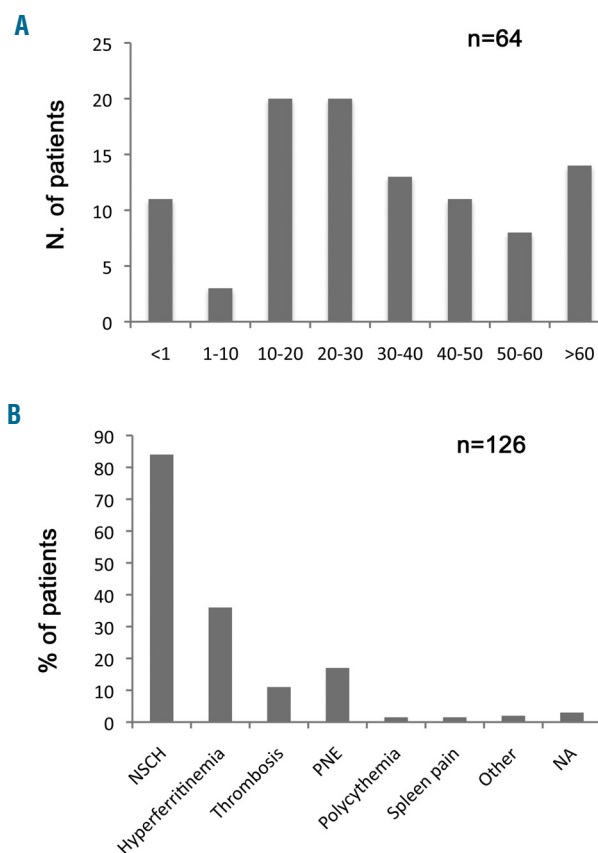
Ektacytometry was performed for 115 patients (90%), including 62/64 index cases and 53/62 family members. Genetic analysis was available for 103 subjects (81%) including 55 index cases (86%). Overall, 56 probands (87%) were diagnosed thanks to a typical dehydrated osmotic gradient ektacytometry profile (*Online Supplementary Figure S1*) and six (6/56, 11%) following genetic testing. Two index cases (one fetus and one neonate) died and could not be tested; the diagnosis was made after family study. Out of the 56 patients with a typical osmotic gradient ektacytometry profile, 49 subjects could be genotyped. Rare *PIEZO1* coding sequence variations were recorded for all these families whereas no variation was detected in *KCNN4* (Table 1 and *Online Supplementary Table S2*). These *PIEZO1* sequence variations co-segregated with the disease in 30/49 informative families.

In 19/49 families (39%), a known *PIEZO1* recurrent mutation in exon 51 was identified: (i) p.Leu2495\_Glu2496dup (10 probands, 20 subjects; in 1 subject, it was associated with a second substitution p.Val2474Met), (ii) p.Arg2456His (6 probands, 15 subjects), p.Arg2488Gln (3 probands, 6 subjects, associated with the polymorphisms p.Gly718Ser *in cis* in 1 family and (iii) p.Arg1925Trp in another family). The other 30 families (61%) carried rare private *PIEZO1* missense sequence variations (n=34). Six families were described or carried known mutations considered pathogenic (in 1 case, 2 mutations *in cis*: p.Gly782Ser and p.Arg808Gln); 15 families carried new unique mutations that we scored as probably pathogenic (n=11) or of unknown significance (n=4) as defined in Table 1. A probably pathogenic sequence variation in exon 16 (p.Asp669Tyr) was present in two apparently unrelated families. In seven families, we identified two associated missense sequence variations; in two of them, one mutation was scored probably pathogenic (p.Val598Leu and p.Gly2433Arg) and was associated with the quite frequent p.Pro2510Leu substitution, the other mutations were scored as being of 'unknown significance' and their role needs to be further established. Overall, ten families (20%) carried two *PIEZO1* rare sequence variations, *in cis* in three families, and whose transmission could not be defined in seven (*Online Supplementary Table S2*). Finally, one subject carried an apparently homozygous mutation, possibly due to hemizygoty since from exon 5 to 51, all *PIEZO1* variations were homozygous (data from the parents were not available). This patient had chronic compensated hemolysis with a hemoglobin concentration of 175 g/L, reticulocyte count of  $500 \times 10^9/L$ ,

a moderate increase in ferritin level and a typical osmotic gradient ektacytometry profile. In one case we only found the *PIEZO1* c.1013C>A (p.Ser 338Tyr) substitution scored as a polymorphism.

Overlapping features with lymphedema were identified in two families: one patient with a mild HX phenotype presented two sequence variations (p.Leu939Met, p.Phe2458Leu) previously described *in cis* in the parent of a patient with *PIEZO1*-related lymphedema;<sup>23</sup> three out of four related patients carrying two substitutions (p.Gly782Ser and p.Arg808Gln) *in cis* in exon 18 co-segregating with the disease through three generations presented with severe perinatal edema, including one with persistent lymphedema during adulthood.

In six families (12 patients), osmotic gradient ektacytometry did not lead to the diagnosis of HX, since the profiles were either atypical (n=1) or normal (n=5) (*Online Supplementary Figure S1*). All index cases had chronic hemolytic anemia/hyperferritinemia, four of them had a family history of undiagnosed dominant hemolysis. Gene analysis identified a mutation in *KCNN4* in all of them (with no *PIEZO1* nucleotide variation). Five families, two



**Figure 1. Main clinical and biological features at diagnosis of the probands and their family members.** (A) Repartition of age at diagnosis for the 64 index cases. The mean age was  $32 \pm 18$  years (range, 0-88). (B) Biological and clinical features at the time of diagnosis of hereditary xerocytosis (HX) in the 64 index cases and 62 family members; only post-splenectomy thromboses are shown; other: B19 parvovirus infection (n=1), persistent isolated jaundice after birth (n=1), systematic exploration in a context of familial porphyria leading to an "incidental" diagnosis of *PIEZO1*-related HX (n=1). The figure does not show one case of extramedullary hematopoiesis. NSCH: non-spherocytic chronic hemolysis; PNE: perinatal edema; NA: data not available (4 patients).

**Table 1.** Heterozygous rare *PIEZO1* coding sequence variations identified in families with hereditary xerocytosis. (overall allele frequency <5% as reported in the GnomAD v2.0.1 database, <http://www.gnomad.broadinstitute.org>).

Variant dbSNP	Mutation in		Amino acid	Frequency GnomAD %	Cons nt AA	Predicted mutation effect scores				Predicted pathogenicity	n family (subject) <sup>§</sup>	Reported family (subject) ref
	NM_001142864.2	Exon				PolyPhen-2 HumVar	SIFT score	MT value				
rs112081600	c.1013C>A	8	p.Ser338Tyr	3.86	-	0.001 B	0.52 T	1 PM	PM	1 <sup>43</sup> (2)	-	
None	c.1792G>A	14	p.Val598Met	0	+/-	0.998 Pr	0.1 T	0.998 DC	Y	1 <sup>21</sup> (1)	1(1) <sup>13</sup>	
None	c.1792G>C (1)	14	p.Val598Leu	0	+/-	0.993 Pr	0.32 T	0.997 DC	PP	1 <sup>32</sup> (1)	-	
None	c.1813A>G (2)	14	p.Met605Val	0.0016	+	0.952 Pr	0.05 T	0.993 DC	US	1 <sup>55</sup> (3)	-	
None	c.1815G>A	14	p.Met605Ile	0	+/-	0.968 Pr	0.08 T	0.983 DC	PP	1 <sup>9</sup> (1)	-	
None	c.2005G>T	16	p.Asp669Tyr	0	+	0.956 Pr	0.05 D	1 DC	PP	2 <sup>27,52</sup> (4)	-	
None	c.2042T>C	16	p.Phe681Ser	0	+	0.973 Pr	0 D	1 DC	Y	1 <sup>14</sup> (1)	1(1) <sup>13</sup>	
rs755885744	c.2152G>A (3)	16	p.Gly718Ser	0.004	--	0.001 B	0.69 T	1 PM	PM	1 <sup>11</sup> (2)	1 (2) <sup>11,18</sup>	
rs200970763	c.2344G>A (4)	18	p.Gly782Ser	0.41	+/-	0.921 Pr	0.21 T	1 DC	Y	1 <sup>47</sup> (4)	1 (2) <sup>11,18</sup>	
rs202103485	c.2423G>A (4)	18	p.Arg808Gln	0.41	+	0.638 Po	0.1 T	0.999 DC	Y	1 <sup>47</sup> (4)	1 (2) <sup>11,18</sup>	
rs201226914	c.2815C>A* (5)	21	p.Leu939Met	0.11	-	0.999 Pr	0.05 D	0.996 DC	US	1 <sup>34</sup> (1)	* <sup>23</sup>	
None	c.4069A>G	29	p.Ile1357Val	0	+/-	0.985 Pr	0 D	1 DC	PP	1 <sup>38</sup> (2)	-	
None	c.4071C>G	29	p.Ile1357Met	0	-	0.998 Pr	0 D	0.995 DC	PP	1 <sup>38</sup> (1)	-	
rs587776990	c.4073G>C	29	p.Arg1358Pro	0	-	0.998 Pr	0 D	1 DC	Y	1 <sup>37</sup> (1)	1 (1) <sup>10</sup>	
rs767365106	c.4556A>C (6)	34	p.Gln1519Pro	0.038	--	0.827 Po	0.31 T	0.76 DC	US	1 <sup>8</sup> (1)	-	
rs200929552	c.5728G>A (6)	40	p.Glu1910Lys	0.19	--	0.001 B	0.86 T	1 PM	PM	1 <sup>8</sup> (1)	-	
rs201442593	c.5773C>T (7)	40	p.Arg1925Trp	0.054	-	0.332 B	0.04 D	1 PM	PM	1 <sup>57</sup> (1)	-	
None	c.5981C>T	42	p.Ser1994Phe	0	+	0.024 B	0.01 D	1 DC	PP	1 <sup>39</sup> (1)	-	
None	c.6007G>A (8)	42	p.Ala2003Thr	0	+	0.124 B	0.64 T	1 DC	US	1 <sup>24</sup> (1)	-	
None	c.6008C>A	42	p.Ala2003Asp	0	+	0.305 B	0.03 D	1 DC	PP	1 <sup>13</sup> (2)	1 (4) <sup>11,18</sup>	
None	c.6016G>A	42	p.Val2006Ile	0	+/-	0.005 B	0.26 T	0.994 DC	US	1 <sup>42</sup> (1)	-	
None	c.6019A>C	42	p.Met2007Leu	0	+	0.068 B	0 D	1 DC	PP	1 <sup>54</sup> (3)	-	
rs587776989	c.6058G>A**	42	p.Ala2020Thr	0	+	0.579 Po	0 D	1 DC	Y	1 <sup>2</sup> (3)	** <sup>10</sup>	
rs556794769	c.6329G>A Hmz	44	p.Arg2110Gln	0.0026	+	0.649 Po	0.24 T	1 DC	nd	1 <sup>41</sup> (1)	-	
rs587776991	c.6380C>T	44	p.Thr2127Met	0.0037	+	0.998 Pr	0.02 D	1 DC	Y	1 <sup>6</sup> (1)	1 (1) <sup>10</sup>	
None	c.6451T>C	44	p.Cys2151Arg	0	+	0.997 Pr	0 D	1 DC	PP	1 <sup>17</sup> (3)	-	

continued on the next page

continued from the previous page

Variant dbSNP	Mutation in		Amino acid	Frequency GnomAD %	Cons nt AA	Predicted mutation effect scores			Predicted pathogenicity	n family (subject) <sup>§</sup>	Reported family (subject) ref
	NM_001142864.2	Exon				PolyPhen-2 HumVar	SIFT score	MT value			
None	c.6479C>T	45	p.Pro2160Leu	0	+ +	0.983 Pr	0 D	1 DC	PP	1 <sup>45</sup> (1)	-
None	c.6574C>A	45	p. Leu2192Ile	0	+ +	0.754 Po	0.06 T	1 DC	us	1 <sup>53</sup> (1)	-
None	c.6601G>T	45	p.Val2201Phe	0	+ +	0.826 Po	0.01 D	1 DC	PP	1 <sup>28</sup> (2)	-
rs563555492	c.6829C>A (2)	47	p.Leu2277Met	0.53	+/ +/-	0.873 Po	0.07 T	0.676 DC	US	1 <sup>55</sup> (3)	-
None	c.6922C>G	47	p.Gln2308Glu	0	+ +/-	0.437 B	0.21 T	0.994 DC	US	1 <sup>49</sup> (1)	-
None	c.7297G>C (9)	50	p.Gly2433Arg	0	+ +/-	0.811 Po	0.01 D	1 DC	PP	1 <sup>7</sup> (1)	-
rs587776988	c.7367G>A	51	p.Arg2456His	0	+/ +	0.998 Pr	0 D	1 DC	Y	6 <sup>14,12,33,40,56</sup> (15)	2 (8) <sup>19</sup>
rs202127176	c.7374C>G* (5)	51	p.Phe2458Leu	0	+/ +/-	0.557 Po	0.25 T	1 DC	US	1 <sup>34</sup> (1)	*23
None	c.7391A>C	51	p.His2464Pro	0	+ +/-	0.394 B	0.07 T	1 DC	US	1 <sup>26</sup> (2)	-
rs200243384	c.7420G>A (10)	51	p.Val2474Met	0.016	+ +/-	0.973 Pr	0.04 D	1 DC	US	1 <sup>22</sup> (1)	-
rs749288233	c.7463G>A (3, 7)	51	p.Arg2488Gln	0.00066	+ +	0.978 Pr	0 D	1 DC	Y	3 <sup>11,31,57</sup> (6)	1(1) <sup>11,18</sup>
None	c.7467G>C	51	p.Glu2489Asp	0	+/ +	0.995 Pr	0 D	1 DC	PP	1 <sup>46</sup> (3)	-
rs201746476	c.7471C>T (8)	51	p.Arg2491Trp	0.029	+/ -	0.892 Pr	0.02 D	1 PM	US	1 <sup>24</sup> (1)	-
rs587776992	c.7479_7484dup (10)	51	p.L2495_E2496 dup	0	nd	nd	nd	nd	Y	10 <sup>5,15,16,22,25</sup> 29,36,44,50,51 (20)	8(14) <sup>10</sup>
rs61745086	c.7529C>T (1, 9)	51	p.Pro2510Leu	0.68	+ +	0.991 Pr	0 D	1 DC	US	2 <sup>7,32</sup> (2)	-

Cons: phylogenetic conservation of nucleotide (nt) and amino acids (AA) according to Alamut software v2.10.0 (- not conserved, - weakly conserved, +/- moderately conserved, + highly conserved). Predicted mutation effect scores from Polyphen-2 v2.2.6 (B: benign, Po: possibly damaging, Pr: probably damaging), SIFT v6.2.0 (T: tolerated, D: deleterious when score <0.05) and Mutation Taster v2013 (PM: polymorphism, DC: disease causing) algorithms. Pathogenicity: Y pathogenic as described in previous reports; PP scored probably pathogenic: mutation identified in a family with typical dehydrated erythrocytometry, absent in population databases, affecting a moderately or highly conserved amino acid and predicted as pathogenic by at least two algorithms, PM polymorphism: sequence variation known in population databases and amino acid weakly or not conserved and predicted as tolerated by at least two algorithms, US: unknown significance if not pathogenic, probably pathogenic or polymorphism. \*: the data shown for each mutation are: total number of families, identification of each family according to *Online Supplementary Table S2* (in superscript), and the total number of patients (in brackets). NB: c.6329G>A was homozygous (hmz). \*Both sequence variations present on the same allele were described in a parent of a child with *PIEZO1*-linked lymphedema<sup>23</sup> \*\*This mutation was described in an apparently unrelated family<sup>10</sup>

already reported and three new families, carried the recurrent c.1055G>A *KCNN4* mutation leading to the p.Arg352His Gardos channel substitution.<sup>15</sup> The last family included three members with marked anemia and splenomegaly; all three carried a novel *KCNN4* 28 bp deletion (c.1109\_1119+17del). This deletion encompassed the exon-intron 7 junction and its consequences are not known so far, although the use of an alternate splice site can be hypothesized.

### Hematologic features at diagnosis

The mean hemoglobin level of the whole cohort was 131±20 g/L (n=115). Most subjects with HX (68%) were not anemic at diagnosis and presented with compensated hemolysis. No patient was transfusion-dependent on a regular basis; occasional transfusions were necessary for

eight patients. Analysis of red cell indices indicated a trend towards macrocytosis (MCV 97±8 fL) and a high reticulocyte count (294±102×10<sup>9</sup>/L). The mean corpuscular hemoglobin concentration was 351±13 g/L, with 38% of the patients having a level above 360 g/L (Figure 2A). After exclusion of neonates, 29 patients out of 97 from 20 families (30%) had a hemoglobin level below 120 g/L, including 8/12 *KCNN4*-mutation carriers. Interestingly, seven adults presented at diagnosis with a hemoglobin level above 160 g/L, including two who were referred for “polycythemia” (hemoglobin level of 181 g/L and 175 g/L), with hemolytic features. All these patients carried a *PIEZO1* mutation (Figure 2B).

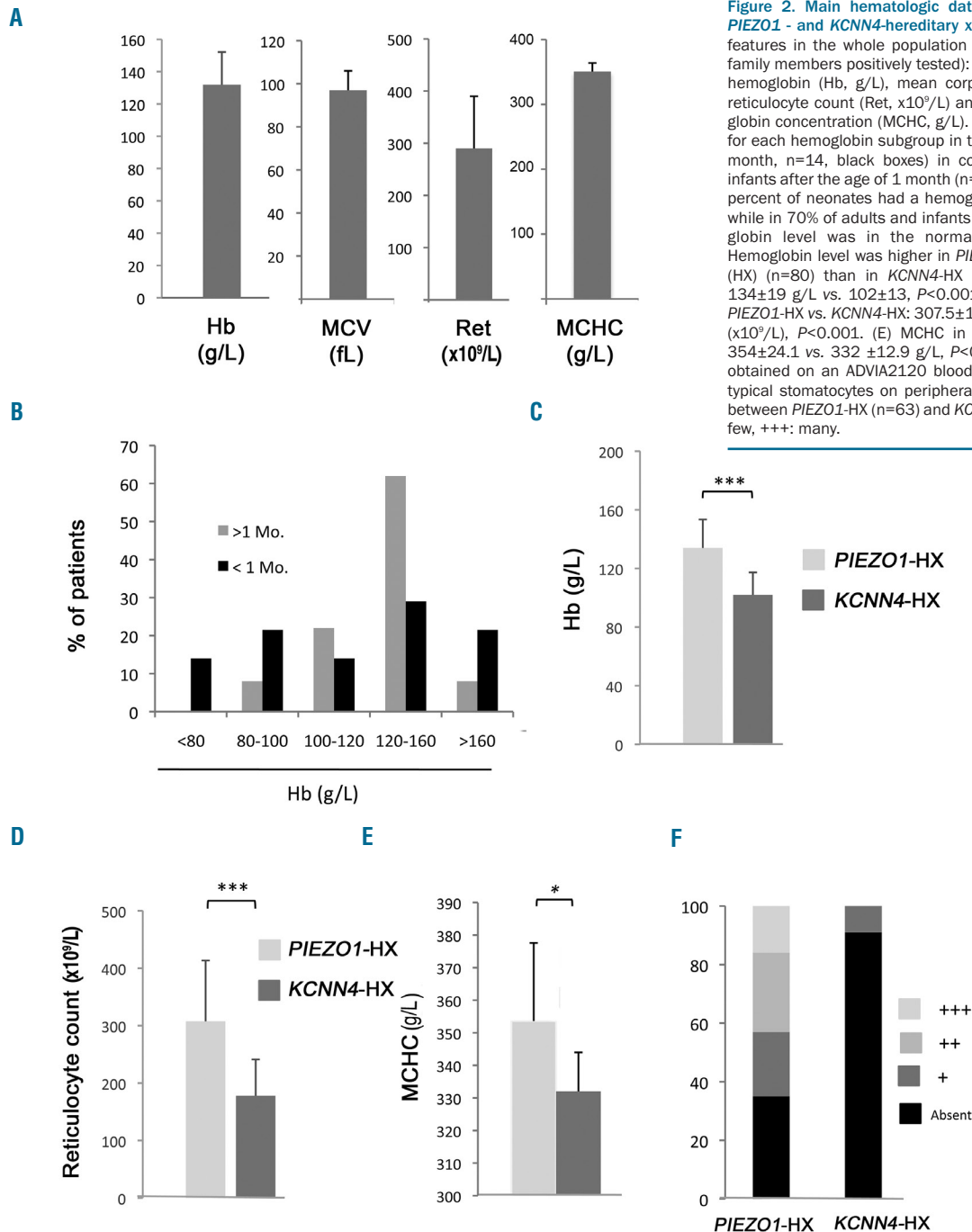
Regarding neonatal and childhood hematologic features, 19 cases were diagnosed before the age of 1 year (including 11 probands). Focusing on 15 cases with suffi-

cient data, seven had neonatal jaundice, requiring *ex sanguino* transfusion in one case and phototherapy in the other six. During the first month of life, anemia was more marked, 48% having a hemoglobin level below 120 g/L (Figure 2B). Five infants were transfused during their first year of life. After the age of 1 year, no patient was regularly transfused except one *KCNN4*-HX infant with severe anemia requiring *in utero* then post-natal transfusions, who underwent splenectomy with a partial improvement thereafter.<sup>13</sup> These data demonstrate the more severe hematologic phenotype after birth, and the progressive improvement as the patients become older.

Focusing on hematologic parameters for each geno-

type, *KCNN4*-HX cases were characterized by a lower hemoglobin level ( $102 \pm 13$  vs.  $134 \pm 19$  g/L,  $P < 0.001$ ), reticulocyte count ( $178.1 \pm 63.1$  vs.  $307.5 \pm 106 \times 10^9/L$ ,  $P < 0.001$ ) and mean corpuscular hemoglobin concentration ( $332 \pm 12.9$  vs.  $354 \pm 24.1$  g/L,  $P < 0.05$ ) than *PIEZO1*-HX cases (Figure 2C-E). The normal mean corpuscular hemoglobin concentration as well as the non-typical erythrocytometry profile reflected the absence of clear erythrocyte dehydration in *KCNN4*-HX.

In terms of red cell morphology, stomatocytes were noted on the blood smear in the majority of *PIEZO1*-HX (65%) samples and were considered as “few” or “rare” on semi-quantitative evaluation in 75% of them.

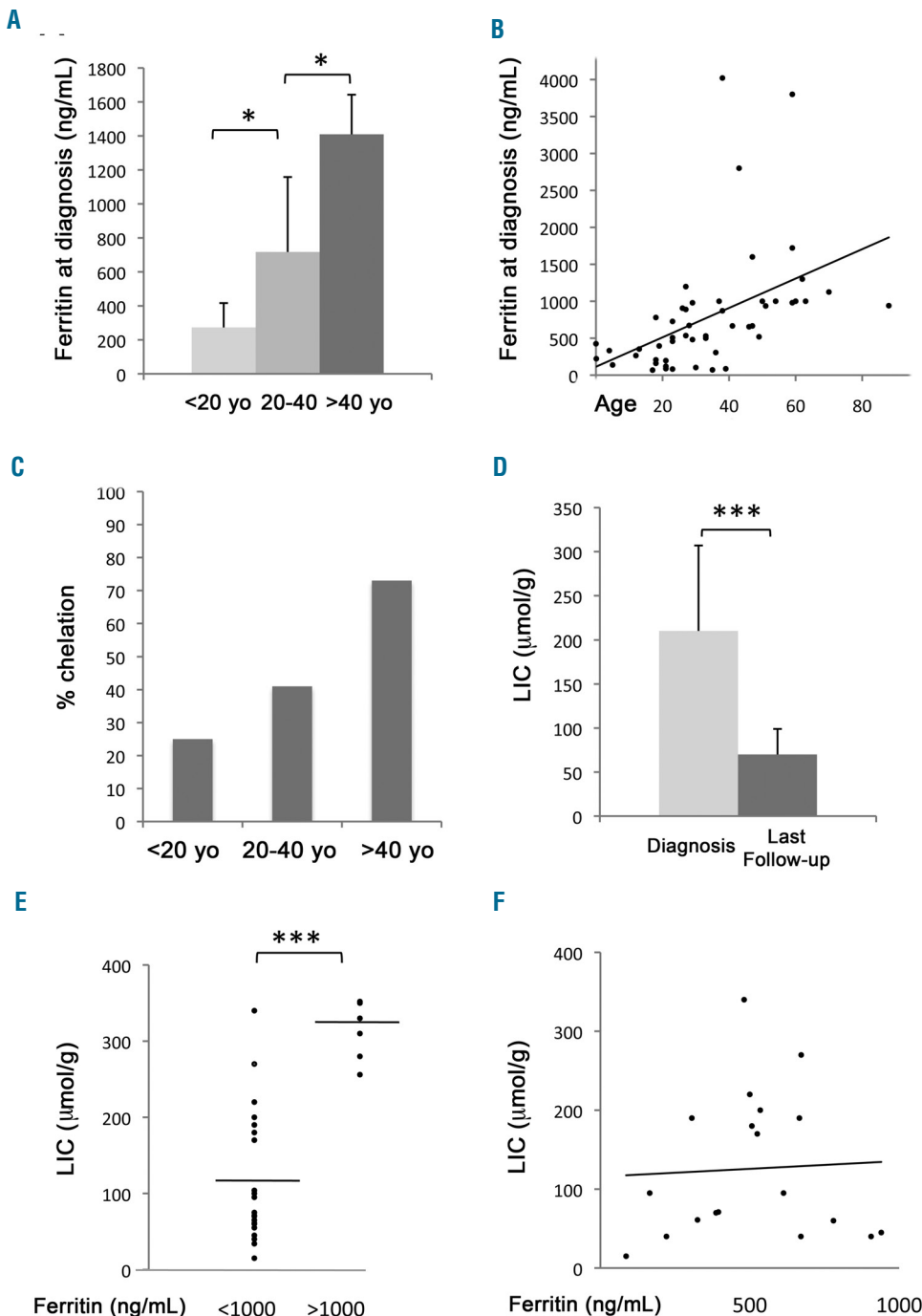


**Figure 2. Main hematologic data and red cell indices in *PIEZO1*- and *KCNN4*-hereditary xerocytosis.** (A) Hematologic features in the whole population of patients (index cases + family members positively tested): results are shown as mean hemoglobin (Hb, g/L), mean corpuscular volume (MCV, fL), reticulocyte count (Ret,  $\times 10^9/L$ ) and mean corpuscular hemoglobin concentration (MCHC, g/L). (B) Percentages of patients for each hemoglobin subgroup in the neonatal period (age <1 month, n=14, black boxes) in comparison with adults and infants after the age of 1 month (n=97, gray boxes). Forty-eight percent of neonates had a hemoglobin value under 100 g/L, while in 70% of adults and infants older than 1 month, hemoglobin level was in the normal range for the age. (C) Hemoglobin level was higher in *PIEZO1*-hereditary xerocytosis (HX) (n=80) than in *KCNN4*-HX (n=12): mean hemoglobin  $134 \pm 19$  g/L vs.  $102 \pm 13$ ,  $P < 0.001$ . (D) Reticulocyte count in *PIEZO1*-HX vs. *KCNN4*-HX:  $307.5 \pm 106$  ( $\times 10^9/L$ ) vs.  $178.1 \pm 63.1$  ( $\times 10^9/L$ ),  $P < 0.001$ . (E) MCHC in *PIEZO1*-HX vs. *KCNN4*-HX:  $354 \pm 24.1$  vs.  $332 \pm 12.9$  g/L,  $P < 0.05$ . The MCHC value was obtained on an ADVIA2120 blood analyzer. (F) Frequency of typical stomatocytes on peripheral blood smear examination between *PIEZO1*-HX (n=63) and *KCNN4*-HX (n=10): +: rare, ++: few, +++: many.

Stomatocytes were absent in ten of the 12 cases of *KCNN4*-HX and rare in the other two cases (Figure 2F). Finally, with regards to *PIEZO1*-HX, we compared carriers of p.Arg2456His (n=15) and p.Leu2495\_Glu2496dup (n=20) to those with all other mutations. Hemoglobin level was lower for both recurrent mutations, although only statistically significantly for p.Leu2495\_Glu2496dup [mean hemoglobin: 121.3±11.1 g/L (p.Leu2495\_Glu2496dup) vs. 130.6±14.5 g/L (p.Arg2456His) vs. 143.7±16.7 g/L (all other mutations);  $P<0.05$ ]. There was no difference in terms of reticulocyte count ( $290\pm74 \times 10^9/L$  vs.  $344\pm76 \times 10^9/L$  vs.  $325\pm131 \times 10^9/L$ ,  $P=NS$ ).

**Splenectomy and thrombotic events**

We recorded thrombotic events in four non-splenectomized patients: a 51-year old man with transient cerebral stroke, a 31-year old female HbS carrier with splenic infarction who was then splenectomized and presented severe thrombotic events after splenectomy, an 18-year old female with painful splenic infarcts and a 52-year old man with hepatic artery thrombosis after liver transplantation for hepatocarcinoma. In contrast, thrombotic events were frequent in splenectomized patients. Overall, 16 patients underwent splenectomy, including eight *PIEZO1*-HX patients from eight families and four *KCNN4*-subjects from two families. Genetic diagnosis



**Figure 3. Hyperferritinemia and iron overload.** (A, B) Ferritin level at diagnosis was correlated to the age of patients: the later in life the diagnosis was made, the higher the ferritin level was: the mean ferritin level was  $273 \pm 141$  ng/mL in patients < 20 years vs.  $717 \pm 441$  ng/mL in patients between 20-40 years ( $P<0.05$ ) vs.  $1409 \pm 653$  ng/mL in those older than 40 years ( $P<0.05$ ). (C) Percentages of patients receiving chelation therapy, depending on the age at diagnosis. (D) Efficiency of iron chelation on liver iron content (LIC), evaluated by magnetic resonance imaging (MRI), between patients at diagnosis (n=20) and patients at last follow-up (n=14): mean LIC:  $200 \pm 103$   $\mu\text{mol/g}$  vs.  $88 \pm 42$   $\mu\text{mol/g}$ ,  $P<0.001$ . (E, F) Correlation between LIC assessed by liver MRI and ferritin level (< or > 1000 ng/mL) for patients for whom these two data were available simultaneously: LIC:  $318 \pm 31$   $\mu\text{mol/g}$  for patients with ferritin >1000 ng/mL (n=7) vs.  $113 \pm 68$   $\mu\text{mol/g}$  for patients with ferritin <1000 ng/mL (n=25),  $P<0.001$ . (E) Eight patients with a ferritin level below 1000 ng/mL already had a LIC >150  $\mu\text{mol/g}$ , and (F) no clear correlation was found between LIC and ferritin below 1000 ng/mL.

was not available for four patients. Splenectomy was performed for persistent hemolysis and/or symptomatic splenomegaly before the diagnosis of HX was made, with a mean delay of 15 years between splenectomy and diagnosis (range, 1-32 years). The mean age at splenectomy was 24 years (range, 4-41 years). Splenectomy did not abrogate hemolysis: the mean hemoglobin level and reticulocyte count were  $112 \pm 19$  g/L and  $280 \pm 134 \times 10^9/L$ , respectively, in splenectomized patients.

Twelve (75%) splenectomized patients (8 patients with *PIEZO1* mutation and 4 not genotyped) experienced 19 thrombotic events, including five portal thromboses (1 previously reported<sup>13</sup>), five cerebral strokes, six episodes of venous thromboembolism and three cases of chronic thromboembolic pulmonary hypertension (Online Supplementary Figure S2). Thrombotic events occurred with a mean delay of  $13 \pm 8.6$  years after splenectomy. All splenectomized *PIEZO1*-HX subjects (8/8) developed thrombotic events and received long-term anticoagulation therapy (Online Supplementary Figure S2). None of the four *KCNN4*-HX splenectomized patients experienced thrombosis, with a mean follow-up of 26.5 years (range, 2-44 years). One non-genotyped patient with severe thrombotic events after splenectomy (patient #5, Online Supplementary Figure S2) received anagrelide therapy for a *JAK2*<sup>V617F</sup>-negative essential thrombocythemia. Two patients presented heterozygous globin gene mutations in association with HX and experienced severe thrombosis after splenectomy: a woman with AS trait (patient #10, Online Supplementary Figure S2),<sup>24</sup> and a male with *PIEZO1*-HX,  $\beta$ -thalassemia trait and  $\alpha$ -globin gene triplication (patient #11, Online Supplementary Figure S2). Both experienced cerebral stroke and chronic thromboembolic pulmonary hypertension.

### Occurrence of perinatal edema in hereditary xerocytosis

Twenty-two patients from 13 families had a known history of perinatal edema. We focused on 19 patients, from 11 families, with well-documented records (Online Supplementary Table S3). In 13 cases, no family history of HX was known when the perinatal edema occurred. The diagnosis of HX was made at birth or in the first month in 12 cases, *in utero* in two cases, or retrospectively, later in life, in a context of non-spherocytic chronic hemolysis and/or recurrence of perinatal edema during a second pregnancy in five cases. Genetic data were available for ten families (18 patients) and revealed *PIEZO1* mutations in all of them. Recurrent mutations were found in five families and private sequence variations in the other five. Five families had histories of recurrent perinatal edema. In family 1, the grandmother had a history of fetal loss due to edema. In families 2, 10 and 11, perinatal edema was noted in two siblings; no data were available for the other affected members. In family 4, all affected members had a history of perinatal edema. In the other families, recurrence of perinatal edema could not be evaluated because of the absence of other HX cases and/or of other pregnancies. In terms of severity, we observed one death *in utero* at 27 weeks of gestation, one medical termination of pregnancy due to severe hydrops at 28 weeks of gestation, and one death 15 days after birth with refractory effusions and cerebral edema. Five cases required *in utero* punctures, and five required post-natal punctures. The forms of perinatal edema were hydrops (n=6), pleural effusion (n=5), ascites (n=11), hydramnios (n=2), jugular cyst (n=1), subcuta-

neous edema (n=3), pericardial effusion (n=2) and hygroma (n=1). Anemia in a context of perinatal edema was documented in three cases, two of whom received *in utero* transfusions; the last one underwent *ex sanguino* transfusion at 23 weeks of gestation. The evolution was favorable in 14 cases with complete resorption of the perinatal edema, except for one patient who still presented moderate lymphedema of the lower limbs at adult age.

### Hyperferritinemia

Ferritin level at diagnosis was available for 49 patients. The mean ferritin level was  $764 \pm 480$  ng/mL and correlated with age (Figure 3A,B). The mean ferritin level at diagnosis was  $1702 \pm 1048$  ng/mL in adult *KCNN4*-HX (n=5) and  $656 \pm 428$  ng/mL in *PIEZO1*-HX (n=40). This hyperferritinemia was not related to transfusions since no patient was transfused on a regular basis. Among these patients, *HFE* genotyping was available for 45 patients: 14 carried p.His63Asp heterozygous mutations, three were heterozygous for the p.Cys282Tyr mutation and one was a composite heterozygous p.Cys282Tyr/ p.His63Asp. We did not find any difference in ferritin levels between wild-type and mutated patients ( $742 \pm 549$  ng/mL vs.  $874 \pm 534$  ng/mL, respectively; *P*=NS). Diabetes mellitus was noted in three cases; one patient developed a hepatocarcinoma and underwent liver transplantation; hypogonadism was recorded in one case, hypothyroidism in one case and osteoporosis in three cases. The percentage of patients treated for iron overload increased with age (25% before the age of 20 years, 41% between 20 and 40 years, and 73% after the age of 40 years) (Figure 3C). Treatments included phlebotomy (n=15), deferasirox (n=9), deferoxamine (n=3) and deferiprone (n=1). Mean liver iron content, evaluated using magnetic resonance imaging, was  $200 \pm 103$   $\mu\text{mol/g}$  at diagnosis (n=20) vs.  $88 \pm 42$  (n=14) at the last follow-up (*P*<0.001), showing that iron chelation was efficient in decreasing iron content in the liver (Figure 3D). There was a strong difference in liver iron content between patients with a ferritin level above 1000 ng/mL (n=7) and under 1000 ng/mL (n=25):  $318 \pm 31$   $\mu\text{mol/g}$  vs.  $113 \pm 68$   $\mu\text{mol/g}$ , respectively (Figure 3E). However, focusing on patients with ferritin levels below 1000 ng/mL, the correlation was poor (Figure 3F). Therefore, even patients with a moderate ferritin increase should undergo an evaluation of tissue iron content at diagnosis.

### Pseudohyperkalemia

Among the 35 patients for whom data on potassium concentration at the same time as ektacytometry were available, the potassium level was above the upper range in 18 cases (51%). However, no specific potassium release test at room temperature was performed.

### Discussion

Because of its heterogeneous presentation, HX is an underestimated condition, as suggested recently.<sup>25</sup> The aim of our report is to describe precisely the mean phenotypic and genotypic HX features, in order to facilitate the diagnosis. Our first conclusion is that most HX subjects have a mild hematologic phenotype, with two-thirds of patients having a fully compensated hemolysis; non-erythroid features, including iron overload, perinatal edema and thrombotic events after splenectomy often deter-

mined the disease severity. Considering this heterogeneity, we investigated whether genetics could discriminate patients who would require a more intensive management. We identified 49 families with *PIEZO1*-HX, and six with *KCNN4*-HX, this ratio being in agreement with those in other reports.<sup>5</sup> One recurrent mutation (p.Arg352His) accounted for most cases of *KCNN4*-HX (5/6 families). We also identified a new 18-base pair *KCNN4* deletion, while only missense mutations have been reported so far, indicating a new genetic basis for this disorder. In the Gardos channelopathies reported so far, the single residue substitution increased the activity of the Gardos channel through an altered calmodulin binding.<sup>15,26</sup> In this family, we observed the 18-base pair deletion overlapped the exon-intron 7 junction. We hypothesized that the use of a potential upstream splice site at c.G1104(TG/GT) might lead to an in-frame deletion of five residues (p.369\_373VDISKdel), creating a Gardos channel missing five amino acids in the calmodulin-binding domain. The consequences on Gardos channel sequence and function remain however unclear and need to be tested.

In contrast to Gardos channelopathy, recurrent mutations accounted for only one-third of *PIEZO1*-HX cases. The three recurrent mutations are located in exon 51, the main mutation hotspot that encodes the canal pore and the C-terminal region. Regions including exons 14 to 18 and exons 42 to 45 appeared as secondary 'hotspots', the former region affects peripheral helices forming the extracellular 'blade', the latter region encodes distinct  $\alpha$  helices close to the canal pore. Indeed, we identified a new recurrent mutation, p.Asp669Tyr in exon 16, present in two unrelated families and recently reported in one other patient.<sup>17</sup> In other families, one or two rare or undescribed private sequence variations were present, indicating very heterogeneous genetic backgrounds in *PIEZO1*-HX. Indeed, a *PIEZO1* sequence variation, not scored as a polymorphism, was identified in all tested families except one. For the large majority of patients, the diagnosis was made based on phenotypic data before the genetic test was available. So far, no clear genotype-phenotype correlation could be drawn. Given the high number of *PIEZO1* polymorphisms described in databases, the effect of these private, newly described mutations cannot be ascertained. From a practical point of view, these data underline the requirement for phenotype-based methods and functional experiments in addition to genetics to confirm *PIEZO1*-HX diagnosis, when unreported mutations are identified. If osmotic gradient ektacytometry can be seen as an indirect phenotypic test reflecting red cell dehydration, functional electrophysiological tests would represent a major advance in the characterization of new mutations. Some of the mutations involved here have been tested functionally, but not in a systematic manner because of the lack of available tools.<sup>10,13,26</sup> The recent characterization of a *PIEZO1* gain-of-function mutation through high-throughput patch clamping on red cells is promising in this respect.<sup>27</sup>

Recent *in vitro* studies showed that both *PIEZO1*-HX and *KCNN4*-HX share a common pathophysiology leading to red cell dehydration.<sup>13,26</sup> Indeed, both disorders share hemolytic features and frequent hyperferritinemia. Hyperferritinemia was not related to transfusions and was frequently at the front line of the diagnosis. Hyperferritinemia is well described in chronic hemolytic diseases,<sup>28</sup> but is notably much more frequent in HX than

in hereditary spherocytosis.<sup>29</sup> Although associated *HFE* mutations may worsen iron overload in HX,<sup>7</sup> they could not be associated with more severe iron overload in our series. Alternative mechanisms of increased iron uptake may be involved, including chronic hypoxia, increased erythroferrone secretion, and erythroblast proliferation possibly associated with some inefficient erythropoiesis. Alternatively, expression of a mutated *PIEZO1* or Gardos protein at the cell surface could directly deregulate hepcidin expression in liver cells or drive iron entry through the gut. From a practical point of view, we observed a weak correlation between ferritin and liver iron content, particularly for ferritin levels below 1000 ng/mL. In terms of clinical management, these data highlight the requirement for an annual iron status evaluation and for measurement of liver iron content by magnetic resonance imaging when ferritin increases above normal values.

On the other hand, *PIEZO1*-HX and *KCNN4*-HX differed in several ways. First, in terms of severity, patients with *PIEZO1*-HX had a milder hematologic phenotype: 27% had a hemoglobin level below 120 g/L vs. 75% of patients with *KCNN4*-HX. It is worth noting that some patients with *PIEZO1*-HX had a hemoglobin level in the upper normal range or above it. Therefore, *PIEZO1* gain-of-function mutations may stimulate erythropoiesis by itself, explaining the 'compensated hemolysis' phenotype as a balance between hemolysis and increased erythropoiesis. Of note, red cell dehydration was not the main cause of hemolysis since it was predominant in *PIEZO1*-HX, but discreet or absent in *KCNN4*-HX despite a more severe anemia. This difference has a practical consequence: ektacytometry, which responds to red cell hydration, identified *PIEZO1*-HX but not *KCNN4*-HX. Therefore, genetic testing should be performed to rule out this subset of HX in the case of undiagnosed hemolysis, even when ektacytometry is normal. It has been recently suggested to use the term "Gardos channelopathy", instead of xerocytosis,<sup>30</sup> for this variant and we agree with this proposal.

Another difference between *PIEZO1*-HX and Gardos channelopathy was the rate of post-splenectomy thrombosis. Thrombosis occurred in 100% of *PIEZO1*-HX cases (8/8), in agreement with other reports,<sup>3,24,30-34</sup> but in 0/4 Gardos-mutated patients. However, these data must be interpreted carefully because: (i) the number of Gardos-splenectomized patients was low; (ii) four patients with thrombotic complications were not genotyped; and (iii) the persistence in all cases of hemolysis after splenectomy represents a risk by itself. Indeed, thrombosis is a well-described complication after splenectomy, particularly when removal of the spleen does not abrogate hemolysis. Several factors may be involved, including platelet aggregation, decrease in nitric oxide level, high level of circulating microparticles, high rate of phosphatidylserine-expressing red cells and increased reticulocyte adherence.<sup>35-37</sup> However, *PIEZO1* seems to have a specific role that may involve endothelial dysfunction.<sup>38,39</sup> Thus, a mutated *PIEZO1* at the cell surface could alter interactions between endothelial cells and dehydrated erythrocytes and favor thrombosis. Considering the type of thrombosis, we made two interesting findings. There was a high rate of portal thrombosis (40% of patients), which may even be underestimated since asymptomatic portal thrombosis was not systematically evaluated after splenectomy as recently suggested.<sup>40</sup> Secondly, we

observed severe thrombotic complications, including pulmonary hypertension in two patients carrying heterozygous globin gene mutations, one with A/S trait and the other with  $\beta$ -thalassemia trait +  $\alpha$ -triplication, suggesting a synergistic deleterious effect of these conditions. Gene analysis was not available for the former, and the latter had two *PIEZO1* missense sequence variations (p.Gln1519Pro and p.Glu1910Lys, scored as unknown significance and as a polymorphism, respectively), the role of these associated mutations on *PIEZO1* function remains to be established.

Finally, perinatal edema was observed in *PIEZO1*-HX and not in *KCNN4*-mutated patients in this series. However, the low number of *KCNN4*-mutated families does not allow definitive conclusion to be drawn on this issue and we recommend that pregnancies should be monitored closely in both genotypes. The severity of perinatal edema was heterogeneous, ranging from nuchal clarity to fetal loss or death after birth. This highlights the requirement for a careful pregnancy follow-up with at least monthly ultrasonography monitoring when one parent is affected. Whether severe perinatal edema is restricted to a subset of *PIEZO1* mutations is unclear, but we observed recurrent perinatal edema in all informative families. Perinatal edema apparently did not involve the effect of *PIEZO1* on red cells, since anemia was not present in most cases. The occurrence of chylous ascites and hygro-ma cysts evoked a primary defect in the lymphatic system.<sup>6,18,41,42</sup> *PIEZO1* is expressed in human embryo lymphatic vessels<sup>11</sup> and its bi-allelic loss of function is associated with congenital lymphatic dysplasia.<sup>23,43</sup> It is puzzling that gain-of-function mutations induced a similar phenotype in the perinatal period. Morpholino *PIEZO1*-knock-down in zebrafish induced anemia;<sup>31</sup> hemolysis with stomatocytes on the blood smear was seen in some patients with congenital lymphatic dysplasia.<sup>23</sup> Moreover, one patient in our series carried a mutation associated with congenital lymphatic dysplasia, while another patient with a history of perinatal edema had persistent lymphedema in adulthood. Edema and hemolysis may

represent two features in the spectrum of *PIEZO1*-related diseases which may sometimes overlap. Again, functional studies are needed to decipher the pathophysiology of both entities.

In summary, we report here the clinical, biological and genetic features of the largest series of HX patients to date. We have uncovered the heterogeneous genetic bases of *PIEZO1*-HX reporting 12 novel mutations, and its varied clinical expression, characterized by a normal to high hemoglobin level, iron overload, occurrence of perinatal edema, and the high thrombosis rate after splenectomy. Gardos channelopathy was characterized by more severe hemolysis, and less erythrocyte dehydration. Taken together, our results provide a better picture of this disorder and will help the diagnosis and clinical management of patients, particularly in terms of contraindications of splenectomy, iron overload and pregnancy follow-up.

### Acknowledgments

We particularly want to thank all the families, the patients and the French Registry of Hereditary Stomatocytosis. We thank all technicians and biologists of the Hematology Laboratory of Hôpital Bicêtre for their contribution and Mme Hélène Ponsin, for excellent resource management. We also thank the ARFH (Association Recherche et Formation en Hématopathologie) for its constant support. Finally, we thank all investigators and contributors: Dr. Madeleine Fénéant-Thibault, Dr. Gérard Tertian, Pr. Gilles Tchernia, Dr. Philippe Agape, Dr. Nathalie Aladjidi, Dr. Yannick Bacq, Dr. Fiorenza Barraco, Dr. Sophie Bayart, Dr. Jean-Sébastien Blade, Pr. Photis Beris, Dr. Jean-Yves Boucher, Dr. Marie Pierre Castex, Dr. Denis Cléau, Dr. Luc Darnige, Dr. Xavier Delbrel, Dr. Valérie Mathieu, Dr. Vincent Di Martino, Dr. Valérie Doireau, Dr. Bernard Drenou, Pr. Cécile Goujard, Dr. Isabelle Grulois, Pr. Xavier Jeunemaitre, Dr. Marie-Françoise Le Coz, Dr. Nicolas Limal, Dr. Jean-Philippe Miguet, Dr. Laetitia Morel, Dr. Philippe Nicoud, Dr. Emmanuel Plouvier, Pr. Jacques Pouchot, Dr. Michel Renoux, Dr. Anne-Laure Suc, and Dr. Hacene Zerazhi. We thank the RFH association for its support.

### References

- Gallagher PG. Disorders of erythrocyte hydration. *Blood*. 2017;130(25):2699–2708.
- Caulier A, Rapetti-Mauss R, Guizouarn H, Picard V, Garçon L, Badens C. Primary red cell hydration disorders: pathogenesis and diagnosis. *Int J Lab Hematol*. 2018;40 Suppl 1:68–73.
- Delaunay J. The hereditary stomatocytoses: genetic disorders of the red cell membrane permeability to monovalent cations. *Semin Hematol*. 2004;41(2):165–172.
- Andolfo I, Russo R, Gambale A, Iolascon A. New insights on hereditary erythrocyte membrane defects. *Haematologica*. 2016;101(11):1284–1294.
- Andolfo I, Russo R, Gambale A, Iolascon A. Hereditary stomatocytosis: an underdiagnosed condition. *Am J Hematol*. 2018;93(1):107–121.
- Grootenboer S, Barro C, Cynober T, et al. Dehydrated hereditary stomatocytosis: a cause of prenatal ascites. *Prenat Diagn*. 2001;21(13):1114–1118.
- Syfuss P-Y, Ciupea A, Brahimi S, et al. Mild dehydrated hereditary stomatocytosis revealed by marked hepatosiderosis. *Clin Lab Haematol*. 2006;28(4):270–274.
- Stewart GW, Amess JA, Eber SW, et al. Thrombo-embolic disease after splenectomy for hereditary stomatocytosis. *Br J Haematol*. 1996;93(2):303–310.
- Delaunay J. The molecular basis of hereditary red cell membrane disorders. *Blood Rev*. 2007;21(1):1–20.
- Albuisson J, Murthy SE, Bandell M, et al. Dehydrated hereditary stomatocytosis linked to gain-of-function mutations in mechanically activated *PIEZO1* ion channels. *Nat Commun*. 2013;4:1884.
- Andolfo I, Alper SL, De Franceschi L, et al. Multiple clinical forms of dehydrated hereditary stomatocytosis arise from mutations in *PIEZO1*. *Blood*. 2013;121(19):3925–3935.
- Zarychanski R, Schulz VP, Houston BL, et al. Mutations in the mechanotransduction protein *PIEZO1* are associated with hereditary xerocytosis. *Blood*. 2012;120(9):1908–1915.
- Rapetti-Mauss R, Picard V, Guittion C, et al. Red blood cell Gardos channel (*KCNN4*): the essential determinant of erythrocyte dehydration in hereditary xerocytosis. *Haematologica*. 2017;102(10):e415–e418.
- Ma S, Cahalan S, LaMonte G, et al. Common *PIEZO1* allele in African populations causes RBC dehydration and attenuates plasmodium infection. *Cell*. 2018;173(2):443–455.e12.
- Rapetti-Mauss R, Lacoste C, Picard V, et al. A mutation in the Gardos channel is associated with hereditary xerocytosis. *Blood*. 2015;126(11):1273–1280.
- Glogowska E, Lezon-Geyda K, Maksimova Y, Schulz VP, Gallagher PG. Mutations in the Gardos channel (*KCNN4*) are associated with hereditary xerocytosis. *Blood*. 2015;126(11):1281–1284.
- Andolfo I, Russo R, Rosato BE, et al. Genotype-phenotype correlation and risk stratification in a cohort of 123 hereditary stomatocytosis patients. *Am J Hematol*. 2018;93(12):1509–1517.
- Grootenboer S, Schischmanoff PO, Laurendeau I, et al. Pleiotropic syndrome of dehydrated hereditary stomatocytosis, pseudohyperkalemia, and perinatal edema maps to 16q23-q24. *Blood*. 2000;96(7):2599–2605.
- Beneteau C, Thierry G, Blesson S, et al. Recurrent mutation in the *PIEZO1* gene in two families of hereditary xerocytosis with fetal hydrops. *Clin Genet*. 2014;85(3):293–295.
- Cynober T, Mohandas N, Tchernia G. Red cell abnormalities in hereditary spherocytosis.

- sis: relevance to diagnosis and understanding of the variable expression of clinical severity. *J Lab Clin Med.* 1996;128(3):259–269.
21. Llaudet-Planas E, Vives-Corrons JL, Rizzuto V, et al. Osmotic gradient ektacytometry: a valuable screening test for hereditary spherocytosis and other red blood cell membrane disorders. *Int J Lab Hematol.* 2018;40(1):94–102.
  22. Lazarova E, Gulbis B, Oirschot B van, van Wijk R. Next-generation osmotic gradient ektacytometry for the diagnosis of hereditary spherocytosis: interlaboratory method validation and experience. *Clin Chem Lab Med.* 2017;55(3):394–402.
  23. Fotiou E, Martin-Almedina S, Simpson MA, et al. Novel mutations in PIEZO1 cause an autosomal recessive generalized lymphatic dysplasia with non-immune hydrops fetalis. *Nat Commun.* 2015;6:8085.
  24. Jaïs X, Till SJ, Cynober T, et al. An extreme consequence of splenectomy in dehydrated hereditary stomatocytosis: gradual thrombo-embolic pulmonary hypertension and lung-heart transplantation. *Hemoglobin.* 2003;27(3):139–147.
  25. Kaufman HW, Niles JK, Gallagher DR, et al. Revised prevalence estimate of possible hereditary xerocytosis as derived from a large U.S. laboratory database. *Am J Hematol.* 2018;93(1):E9–E12.
  26. Rapetti-Mauss R, Soriani O, Vinti H, Badens C, Guizouarn H. Senicapoc: a potent candidate for the treatment of a subset of hereditary xerocytosis caused by mutations in the Gardos channel. *Haematologica.* 2016;101(11):e431–e435.
  27. Rotterdam MG, Fermo E, Becker N, et al. A novel gain-of-function mutation of Piezo1 is functionally affirmed in red blood cells by high-throughput patch clamp. *Haematologica.* 2019;104(5):e179–e183.
  28. Barcellini W, Fattizzo B. Clinical applications of hemolytic markers in the differential diagnosis and management of hemolytic anemia. *Dis Markers.* 2015;2015:635670.
  29. Mariani M, Barcellini W, Vercellati C, et al. Clinical and hematologic features of 300 patients affected by hereditary spherocytosis grouped according to the type of the membrane protein defect. *Haematologica.* 2008;93(9):1310–1317.
  30. Fermo E, Bogdanova A, Petkova-Kirova P, et al. “Gardos Channelopathy”: a variant of hereditary Stomatocytosis with complex molecular regulation. *Sci Rep.* 2017;7(1):1744.
  31. Perel Y, Dhermy D, Carrere A, et al. Portal vein thrombosis after splenectomy for hereditary stomatocytosis in childhood. *Eur J Pediatr.* 1999;158(3):628–630.
  32. Bergheim J, Ernst P, Brinch L, Gore DM, Chetty MC, Stewart GW. Allogeneic bone marrow transplantation for severe post-splenectomy thrombophilic state in leaky red cell membrane haemolytic anaemia of the stomatocytosis class. *Br J Haematol.* 2003;121(1):119–122.
  33. Murali B, Drain A, Seller D, Dunning J, Vuylsteke A. Pulmonary thromboendarterectomy in a case of hereditary stomatocytosis. *Br J Anaesth.* 2003;91(5):739–741.
  34. Carli P, Graffin B, Gisserot O, Landais C, De Jaureguiberry J-P. [Recurrence of thromboembolic disease after splenectomy for hereditary xerocytosis]. *Rev Med Interne.* 2007;28(12):879–881.
  35. Gallagher PG, Chang SH, Rettig MP, et al. Altered erythrocyte endothelial adherence and membrane phospholipid asymmetry in hereditary hydrocytosis. *Blood.* 2003;101(11):4625–4627.
  36. Smith BD, Segel GB. Abnormal erythrocyte endothelial adherence in hereditary stomatocytosis. *Blood.* 1997;89(9):3451–3456.
  37. Cappellini MD, Grespi E, Cassinero E, Bignamini D, Fiorelli G. Coagulation and splenectomy: an overview. *Ann N Y Acad Sci.* 2005;1054:317–324.
  38. Li J, Hou B, Tumova S, et al. PIEZO1 integration of vascular architecture with physiological force. *Nature.* 2014;515(7526):279–282.
  39. Wang S, Chennupati R, Kaur H, Iring A, Wettschurek N, Offermanns S. Endothelial cation channel PIEZO1 controls blood pressure by mediating flow-induced ATP release. *J Clin Invest.* 2016;126(12):4527–4536.
  40. Iolascon A, Andolfo I, Barcellini W, et al. Recommendations regarding splenectomy in hereditary hemolytic anemias. *Haematologica.* 2017;102(8):1304–1313.
  41. Entezami M, Becker R, Menssen HD, Marcinkowski M, Versmold HT. Xerocytosis with concomitant intrauterine ascites: first description and therapeutic approach. *Blood.* 1996;87(12):5392–5393.
  42. Ami O, Picone O, Garçon L, et al. First-trimester nuchal abnormalities secondary to dehydrated hereditary stomatocytosis. *Prenat Diagn.* 2009;29(11):1071–1074.
  43. Lukacs V, Mathur J, Mao R, et al. Impaired PIEZO1 function in patients with a novel autosomal recessive congenital lymphatic dysplasia. *Nat Commun.* 2015;6:8329.