



HAL
open science

Percutaneous arthroscopic calcaneal osteosynthesis for displaced intra-articular calcaneal fractures: Systematic review and surgical technique

Stanislas Marouby, Nicolas Cellier, Olivier Mares, Pascal Kouyoumdjian,
Rémy Coulomb

► To cite this version:

Stanislas Marouby, Nicolas Cellier, Olivier Mares, Pascal Kouyoumdjian, Rémy Coulomb. Percutaneous arthroscopic calcaneal osteosynthesis for displaced intra-articular calcaneal fractures: Systematic review and surgical technique. *Foot and Ankle Surgery*, 2019, 26 (5), pp.503-508. 10.1016/j.fas.2019.07.002 . hal-02860839

HAL Id: hal-02860839

<https://hal.umontpellier.fr/hal-02860839>

Submitted on 7 Sep 2020

HAL is a multi-disciplinary open access archive for the deposit and dissemination of scientific research documents, whether they are published or not. The documents may come from teaching and research institutions in France or abroad, or from public or private research centers.

L'archive ouverte pluridisciplinaire **HAL**, est destinée au dépôt et à la diffusion de documents scientifiques de niveau recherche, publiés ou non, émanant des établissements d'enseignement et de recherche français ou étrangers, des laboratoires publics ou privés.

Percutaneous arthroscopic calcaneal osteosynthesis for displaced intra-articular calcaneal fractures: Systematic review and surgical technique

Stanislas Marouby*, Nicolas Cellier, Olivier Mares, Pascal Kouyoumdjian, Remy Coulomb

Department of Orthopedic Surgery, Caremeau University Hospital, place du Professeur Robert Debré, 30029 Nîmes, France

ABSTRACT

Background: The aim of this study was to systematically evaluate the available literature on technique and outcomes of percutaneous arthroscopic calcaneal osteosynthesis for displaced intra-articular calcaneal fractures.

Methods: A systematic review of the literature available in MEDLINE, EMBASE, and the Cochrane Library database was performed, including studies from January 1985 to August 2018. The literature search, data extraction, and quality assessment were conducted by 2 independent reviewers. The surgical technique and perioperative management, clinical outcomes scores, radiographic outcomes and complication rate were evaluated.

Results: Of 66 reviewed articles, 8 studies met the inclusion criteria. The included studies reported on the results of 152 patients. At last follow up the mean American Orthopaedic Foot & Ankle Society ankle-hindfoot was ranging from 72.1 to 94.1. The complication rate was low, including only one superficial infection.

Conclusions: The studies included were of too little level of evidence to allow for data pooling or meta-analysis. However, the percutaneous arthroscopic calcaneal osteosynthesis seems to be a good option for displaced intra-articular calcaneal fractures with a low complication rate. Appropriately powered randomized controlled trials with long-term follow up are needed to confirm the efficacy of this technique.

Level of evidence: Level III, systematic review of Level III studies.

Keywords:

Displaced intra-articular calcaneal fracture
Subtalar arthroscopy
Arthroscopic assisted percutaneous screw fixation
Fluoroscopy
Injury
Trauma

Contents

1.	Introduction
2.	Materials and methods
2.1.	Search strategy
2.2.	Study selection
2.3.	Data extraction
2.4.	Study quality assessment
2.5.	Data analysis
3.	Results
3.1.	Population characteristics
3.2.	Study quality
3.3.	Surgical techniques (Table 3)
3.4.	Hospital stay and post-operative instructions
3.5.	Clinical scores
3.6.	Radiographic evaluation

* Corresponding author.

E-mail address: Stanislasmarb@gmail.com (S. Marouby).

3.7. Complications	
4. Discussion	
4.1. Learning curve, technical notes, and limitations	
5. Conclusion	
Discloser	
Conflict of interest	
References	

1. Introduction

Calcaneal fractures are uncommon (2% of all fractures) but occur in younger patients with a majority of subtalar intra-articular lesions and thus leading to low functional result [1]. Anatomic restoration of the calcaneal shape and joint congruity predict greater functional scores and a lower incidence and rate of subtalar arthritis and subtalar fusion [1–3].

Common surgical procedure consists in an open reduction in order to restore the height, width, length and joint congruence. However, the complication rate related to soft tissue range from 2.8% to 14.3% and infection from 8% to 25% [4,5]. Surgeons perform a variety of percutaneous techniques [6], including Schanz pins and Kirschner wires fixation, cannulated screws fixation and more recently bone cement injection and calcaneal nail [7]. Percutaneous techniques aim to reduce wound complications [8,9] but it seems difficult to restore joint congruence with only Broden’s fluoroscopic view [6,10]. Arthroscopic assisted technique has been widely used on traumatic case (hip, knee, wrist) and for foot and ankle surgery as well [11]. Thus in 2002, a first authors reported a percutaneous arthroscopic calcaneal osteosynthesis [6]. Many authors published others series but none systematic review was performed since.

This systematic review aims to assess the surgical technique, outcomes and safety of this for displaced intra-articular calcaneal fractures.

2. Materials and methods

2.1. Search strategy

A systematic review of literature in PubMed (MEDLINE), EMBASE and the Cochrane database was done until august 2018. The search terms used and combined were: “calcaneus”, “fracture”, “percutaneous” and “arthroscopy”. After the initial Medical Subject Headings keyword search, additional manual searches were conducted using the bibliographies of all selected full-text articles. Sixty-six potential titles and abstracts were identified from the electronic database.

2.2. Study selection

A time frame for the literature search was set from January 1985 to august 2018. This time frame was chosen regarding the beginning of the practice and research of arthroscopic techniques in foot surgery. So we decided not to include studies published before 1985, year of the first report of subtalar arthroscopy. Included studies fulfilled the following criteria: Investigating humans treated with percutaneous arthroscopic calcaneal osteosynthesis, published papers in English, including at least ten patients followed-up for a minimum of one year, and reporting at least one outcome measure relating to pain or function outcome, radiographic evaluation and complication rates. The percutaneous fixation was defined as the use of mini-incision and direct application of wires or screws from the skin surface. Exclusion criteria included any paper that did not meet the inclusion criteria, as well as those that included patients with extensive lateral

approach. For study selection, the titles and abstracts of the identified studies were screened first, and then selected studies were scanned with full text.

2.3. Data extraction

Two reviewers independently extracted data using a predefined data extraction form (visual human reading of papers). Data included demographic information, methodology, Sander’s classification [12], details on interventions and reported outcomes. Clinical outcomes were evaluated at last follow up using a visual analog scale (VAS), the Ankle-Hindfoot Scale developed by the American Orthopaedic Foot & Ankle Society (AOFAS), the Short Form Health Survey (SF-36; Physical Function) [13]. Complications included superficial and/or deep infections and wounds, implant removal (for prominent subcutaneous screw head with symptoms), conversion to an open technique, subfibular pain (due to a prominent screw head that subsided after screw removal), sural nerve injury, subtalar joint arthritis with rate of fusion. Radiographic parameters such as Böhler’s angle were measured with preoperative and last follow-up radiographs. Preoperative radiograph CT evaluation determine Sanders type: type I is a fracture without displacement and type IV is severely comminuted fractures, with usually four or more parts. Type II is a two-part fracture, subdivided into types A, B and C, depending on the position of the main fracture line. Type III is a fracture in three parts with a central depression, divided into three parts: AB, BC or AC, depending on the combination of two fracture lines [12].

2.4. Study quality assessment

Methodological quality of each study was assessed via the MINORS score, a methodological index for evaluation of non-randomized studies [14]. The exact criteria assessed are found in Table 1. Studies with a MINORS score over or equal to 75% were considered at low risk of bias. Studies with a MINORS score lower than 75% were considered at high risk of bias.

2.5. Data analysis

The reporting of this systematic review was done in accordance with the Preferred Reporting Items for Systematic Reviews and Meta-Analyses (PRISMA) statement [15]. Data were extracted from the papers by systematic analysis of each article and summarization (Microsoft Excel version 2010, Microsoft, Redmond, WA, USA).

3. Results

The results of the search strategy and study selection criteria are shown in Fig. 1. A total of 8 studies were included in this systematic review [9,10,15–22].

3.1. Population characteristics

The 8 studies reported a total of 152 patients with 155 affected feet. Most of them were male (71%). The mean age range from 39.6

Table 1

Minors score for each study, quality assessment of individual studies.

Author	Score	Risk of bias	1	2	3	4	5	6	7	8	9	10	11	12
Park et al. 2018	15/24	High	2	2	0	2	1	1	1	0	2	0	2	2
Woon et al. 2011	12/16	Low	2	1	2	2	1	1	1	2				
Pastides et al. 2015	12/16	Low	2	2	2	2	1	1	0	2				
Gavlik et al. 2002	8/16	High	2	1	0	2	1	1	1	0				
Yeap et al. 2016	17/24	Low	2	2	0	2	1	1	2	0	2	2	2	1
Sivakumar et al. 2014	10/16	High	2	2	0	2	2	1	1	0				
Rammelt et al. 2002	11/24	Low	1	1	0	2	1	1	1	0	1	0	1	2
Law et al. 2017	10/16	High	2	1	0	2	2	2	1	0				

The final score comprises the results of 8 items or 12 items in case of comparative studies: 1. a clearly stated aim; 2. inclusion of consecutive patients; 3. prospective collection of data; 4. endpoints appropriate to the aim of the study; 5. unbiased evaluation of the study endpoint; 6. follow-up period appropriate to the aim of the study; 7. loss to follow-up less than 5%; 8. prospective calculation of the study size; 9. an adequate control group; 10. contemporary groups; 11. baseline equivalence of groups; 12. adequate statistical analysis. For each item score ranged from 0 to 2.

to 52.3 years. The mean follow-up period ranged from 14 to 79.2 month. The mean time from injury to surgery ranged from 3.9 days to 8 days. Five studies [10,16,17,19,22] included only Sanders type 2. Two studies [18,20], included Sanders type 2 and 3 and one study [21] type 4. Only 1 open fracture was treated by this technique [20]. Demographic details are shown in Table 2.

3.2. Study quality

The assessment of the methodological quality using the MINORS scale resulted in a mean score of 10.4/16 (maximum score of 12/16) for non-comparative studies, and of 14.3/24 (maximum score of 17/24) for comparative studies Table 1. One study was of level II of evidence [17], seven level III [6,9,15–22].

3.3. Surgical techniques (Table 3)

Surgery was usually performed under general anaesthesia. Patients were in lateral decubitus position (except in case of bilateral fracture). Seven studies described exclusively percutaneous approach and only one author used minimal invasive sinus tarsi approach (4-cm incision was made along the tarsal sinus from the tip of the lateral malleolus to the calcaneo-cuboid joint along the tarsal sinus) [16] similar to the modified palmer lateral approach [8].

The subtalar arthroscopy [23] was performed with an anterolateral portal (placed 1 cm below and anterior to the fibula tip and 0.5 cm posterior to the anterior calcaneal process), a posterolateral (placed in line with the joint, 1 cm behind the fibula). A middle portal was used in some cases (immediately anterior to the distal fibula, directly over the sinus tarsi). A small diameter arthroscope (1.9–2.7 mm/0–30°) and a small shaver was used because of the narrow space in the subtalar joint (Fig. 2).

A 6.5 mm cancellous Schanz screw with handle was introduced into the fragment from the dorsal direction after mini-incision and drilling to achieve a good reduction of the tuberosity. The screw was placed centrally into the main portion of the fragment parallel to the upper aspect of the tuberosity and directed to the most distal aspect of the displaced posterior facet. Using the Schanz screw as a lever, the tuberosity fragment was reduced. After loosening the impacted fragment with medial/lateral stress, the handle was moved downward in order to bring the tuberosity fragment back into alignment with the main sustentacular fragment. Additional varus misalignment was reduced with lateral movement of the handle, or valgus with medial movement. Reduction was checked with fluoroscopy and arthroscopy and additional Kirschner wires was used on more complex fractures. Percutaneous osteosynthesis was performed with three to six cannulated cortical screws. Mean operative time ranged from 82.6 to 112.9 min.

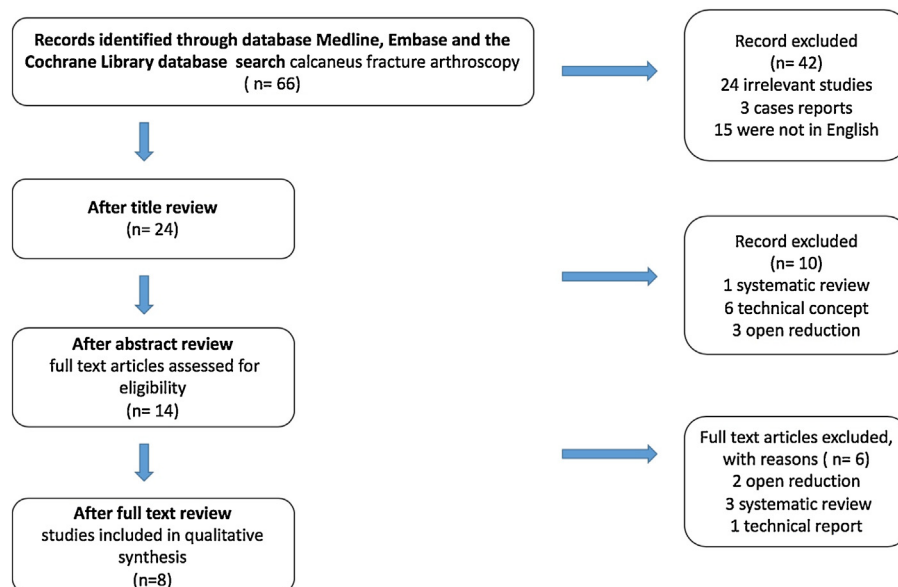


Fig. 1. Search strategy. PRISMA flow diagram. PRISMA, preferred reporting items for systematic reviews and meta-analyses.

Table 2

Studies with percutaneous and arthroscopic technique on calcaneal fracture included in the systematic review.

Investigator, year	Type of study/level of evidence	Patients (fractures)	Age, year	Follow-up time (mean), month	Surgical procedure	Sander's type	AOFAS score, last follow up	Bohler's angle, mean improvement last follow up (°)	Complications (n)
Park et al. 2018	Retrospective comparative study (level III)	23	52.3	15.9 (12–27)	STA + percutaneous and arthroscopy	II	91.7 (72–100)	14.7	3 (SNI), 2 (SP)
Woon et al. 2011	Prospective cohort (level II)	22	43 (19–61)	33 (24–42)	Percutaneous and arthroscopy	II	84.2 ± 13.9	15.9	1 (HR)
Pastides et al. 2015	Retrospective cohort (level III)	30 (33)	39.6 (27–63)	24 (5–57)	Percutaneous and arthroscopy	II, III	72.18 (18–100)	12.4	1 (IW), 2 (HR), 2 (COS)
Gavlik et al. 2002	Retrospective cohort (level III)	15 (15)	41.1 (35–48)	14 (12–28)	Percutaneous and arthroscopy	II	93.7 (87–100)	11.2	1 (HR), 2 (COS)
Yeap et al. 2016	Retrospective comparative study (level III)	14	42.1 (17–27)	16.9	Percutaneous and arthroscopy	II, III	86.7	15.9	1 (HR)
Sivakumar et al. 2014	Retrospective cohort (level III)	13	44.4 (18–69)	14.3 (13–34)	Percutaneous and arthroscopy	II, III, IV	87.8 (69–100)	16.6	1 (HR)
Rammelt et al. 2002	Retrospective cohort (level III)	21 (21)	41.1 (35–49)	15 (12–23)	Percutaneous and arthroscopy	II	94.1 (87–100)	12.7	3 (COS), 1 (HR)
Law et al. 2017	Retrospective cohort (level III)	14 (16)	5.4 (39.3–66.9)	79.2 (64–100)	Percutaneous and arthroscopy	II	90.3 ± 12.2	14.1	2 (HR)

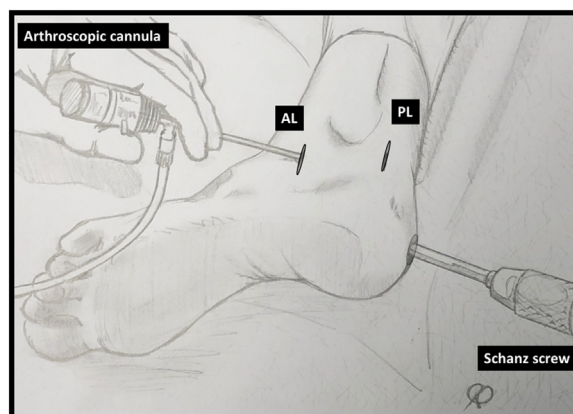
Abbreviations: PACO, percutaneous arthroscopic calcaneal osteosynthesis; STA, sinus tarsi approach; AOFAS, American Orthopaedic Foot and Ankle Society; HR, hardware removal; IW, infection or wound; NR, not recorded; SNI, sural nerve injury; SP, subfibular pain; COS, conversion to open surgery.

Table 3

Details of surgical techniques: percutaneous arthroscopic calcaneal osteosynthesis on studies included in the review.

Investigator, year	Surgical procedure	Time from injury to surgery (day)	Arthroscopie optique, (mm, °)	Arthroscopic portals	Operative time, (min)	Immobilisation, (week)	Duration of non-weight bearing (week)	Mean postoperative hospital stay, (day)
Park et al. 2018	STA + PACO	3.9	2.4	ST, AL	82.6	4	6–8	NR
Woon et al. 2011 and Law et al. 2017	PACO	8	2.4; 0	AL, C	95	2	3–6	4
Pastides et al. 2015	PACO,	7	4.0; 30	ST, PL	NR	2	NR	1.92
Gavlik et al. 2002	PACO,	6	1.9; 0 or 4.0; 30	AL, PL	NR	No	6	NR
Yeap et al. 2016	PACO,	6.9	2.7; 30	AL, C, PL	112.9	NR	6	3.8
Sivakumar et al. 2014	PACO,	NR	2.9; 30	AL, C	NR	NR	10–12	NR
Rammelt et al. 2002	PACO,	6	1.9; 0 or 4.0; 30	AL, PL	NR	NR	6–12	NR

Abbreviations: PACO, percutaneous arthroscopic calcaneal osteosynthesis; STA, sinus tarsi approach; NR, not recorded; ST, sinus tarsi; AL, antero-lateral; C, central; PL, postero-lateral.

**Fig. 2.** Subtalar arthroscopy portals and reduction of calcaneal fractures by percutaneous leverage with a pin on the tuberosity.

AL, anterolateral portal (placed 1 cm below and anterior to the fibula tip and 0.5 cm posterior to the anterior calcaneal process). PL, posterolateral portal (placed in line with the subtalar joint, 1 cm behind the fibula).

3.4. Hospital stay and post-operative instructions

The mean postoperative hospital stay was reported in 3 studies and range from 1.9 to 4 days. An early passive mobilisation was performed on first postoperative day. Partial weight-bearing was allowed during the first six weeks associated to extensive physical therapy program including active ROM exercises and passive mobilization of the midfoot and rearfoot. Some authors reported the use of elastic dressing or aircast boot. Full weight-bearing was generally allowed after 6 weeks.

3.5. Clinical scores

All studies reported AOFAS score. The average ranged from 72.1 to 94.1 at last follow up. Three studies, reporting VAS and SF-36 score, found a mean value ranging from 1.2 to 2.9 and from 57 to 79.2 respectively at last follow up.

3.6. Radiographic evaluation

The mean Bohler's angle improvement ranged from 11.2 to 16.6°. Only 3 studies had done post-operative radiographic CT scan and 2 studies found that 87 and 100% of patients had posterior facet articular step of <2 mm.

3.7. Complications

None wound dehiscence was described but one superficial infection (manage with oral antibiotic, no bone infection) was reported (0.6%). Five percent of misplaced screws (with hardware removal) were noted (9 patients). Three sural nerve injury (resolved within the 6 month after surgery) and two subfibular pain (due to a prominent screw head that subsided after screw removal) were noted in case of sinus tarsi approach. Four percent of conversion to open surgery after reduction failure was reported (7 patients). None subtalar fusion had been required at the end of studies follow-up period.

4. Discussion

This review highlight that subtalar arthroscopy during treatment of displaced intra-articular calcaneal fractures allowed control of reduction before percutaneous fixation, ovoid open techniques with large surgical approaches and decrease wound dehiscence and infection.

Most of calcaneus fractures are articular and the prognosis is related to the reduction of posterior facet [10,24]. If percutaneous technique have decreased deep infection from 8 to 25% with extended lateral approach [5] to 0–11% [25], bad reduction of posterior facet and misplacement of screws was difficult to assess because of the irregular shape of the posterior facet makes it difficult to use Broden's views in fluoroscopy. Use of CT scans reveals 24% of misplaced articular screws not visible on radiograph [24]. In 2010 [26], it has been found on 83 percutaneous fixation without arthroscopy 12% of mispositioned screws. Concerning the 152 patients included in this review, the use of dual modality imaging (fluoroscopy and arthroscopy) decrease rate of misplaced screws to 5% and restore joint congruency. A recent study found that 100% of patients had posterior facet articular step of less than 2 mm and decrease wound complication (none) or deep infection (0.7%) but with 2 hardware removals on 33 patients (6%) [18].

Clinical evaluation showed good satisfaction rate at last follow up. A recent study found at a mean follow up of 79.2 month a mean AOFAS score at 90.3 ± 12.2 [22]. But the multiplicity of clinical scores made the comparison difficult. Another work found no difference on all clinical evaluations between the use or not of the

dual modality imaging. However, significant difference were found on CT reduction and rate of mispositioned screws [16]. A mean AOFAS score of 89.26 at 29 month of follow up was found on 60 patients treated with percutaneous technique without use of arthroscopy (only fluoroscopy) [27]. But the short follow-up periods of these studies could explain this lack of difference.

4.1. Learning curve, technical notes, and limitations

Some authors insisted on difficulty to manage subtalar arthroscopy without iatrogenic chondral injury [16]. The use of small diameter arthroscope (less than 2.4 mm) is necessary for the author, without distraction system but only with exertion of varus stress with the Steinmann pin. It has been reported at the beginning of learning curve, temporary use of external fixator on the first 4 cases [21].

This procedure was more time consuming on the beginning. Two works reported 165 min on the first case [17] and 91.3 min on the first case for 73.2 min on the last case for another author [16], but operative time was not different with the use or no of arthroscopy because of the least need of a fluoroscopic control of the reduction.

In case of percutaneous methods failures or deep impactions, additional portals or conversion to small incision (sinus tarsi approach) can be considered. Only one study reported conversion to open surgery concerning 3 of 21 patients [10]. In two other studies, the conversion (in 4 patients) was an exclusion criteria [6,18].

Those injuries more adapted to percutaneous fixation with dual modality imaging are tongue-type fractures with limited anterior comminution [21], usually Sanders type II and more rarely type IV (2 patients). Although management does not differ for both tongue-type and joint depressed fractures. However reduction and its maintain are technically more difficult in case of depressed fractures [17].

This technique could be used on patient with surgical risk factors such as smokers (54.6% in the review), diabetics and probably open fractures (0.7%). This type of surgical technique has to be proposed early after the injury to allow percutaneous mobilisation of fracture. The mean time from injury to surgery ranged from 3.9 days to 8 days. The mean postoperative stay was 1.9 to 4 days, there were almost no wound complications, this treatment allowed discharge on day 0 or day 1.

Use of calcaneal nail with arthroscopic assistance may be a good alternative, giving at the same time a primary stability and a decreased risk of soft tissue complications. In a recent study [7] it has found on 15 cases operated by calcaneal nail assisted by arthroscopy and 91 cases by sinus approach, 1.2% of wound complication, 0.9% of soft tissue infection, good radiological outcomes (posterior facet step-off was 0.7 mm, Böhler angle 28.7° at six months), good clinical outcomes (AOFAS at 92.6 at 12-month follow-up).

This systematic review study has some limitations. First, except for two prospective study [17,18], most of the included studies are case series with a low level of evidence and with small numbers of patients, mean of 19 patients (13–30). That can be explain by the recent character of the arthroscopic technique and the small incidence of calcaneal fractures [1]. Furthermore, the majority of the studies that have been included have a poor MINORS score and have been considered at high risk of bias. In addition, the inconsistency of the clinical outcome measures used in the different studies made the comparisons difficult. Otherwise the follow-up was relatively short with an average of 19.3 months (5–42). Therefore draw conclusions on early complications (wound complication and hardware removal) and on the reliability of the rate of fusion at 0% have to be considered carefully. Only 3 studies

reported outcomes after more than 2 years and one after 4 years. Caution should be also taken on the results presented in this review.

5. Conclusion

The included studies consisted on too low level of evidence for data pooling or meta-analysis. The present systematic review ascertaining the clinical and radiological findings, describing surgical technique, results and limitations of the percutaneous arthroscopic calcaneal osteosynthesis. This technique seems to be a fair option to consider for the treatment of displaced intra-articular calcaneal fractures and allows a low complication rate. Appropriate powered randomized controlled trials and long-term follow up are necessary to assess the efficacy of this technique versus open reduction and internal fixation.

Discloser

All authors were fully involved in the study and preparation of the manuscript and that the material within has not been and will not be submitted for publication elsewhere.

S.M; N.C; R.C; P.K: the conception and design of the study, or acquisition of data, or analysis and interpretation of data.

S.M; N.C; R.C; P.K; O.M: drafting the article or revising it critically for important intellectual content.

S.M; N.C; R.C; P.K.: final approval of the version to be submitted. S.M. statistics.

Conflict of interest

No benefits in any form have been received or will be received from a commercial party related directly or indirectly to the subject of this article. The authors declare that they have no competing interest. Apart from this work, N. C. declares to have been consultant for STRYKER. P.K. is an educational consultant for STRYKER, which is not related to this work. No funds were received in support of this study.

References

- [1] Sanders R. Displaced intra-articular fractures of the calcaneus. *J Bone Joint Surg Am* 2000;82:225–50.
- [2] Thordarson DB, Krieger LE. Operative vs. nonoperative treatment of intra-articular fractures of the calcaneus: a prospective randomized trial. *Foot Ankle Int* 1996;17:2–9.
- [3] SooHoo NF, Vyas R, Samini D. Responsiveness of the foot function index, AOFAS clinical rating systems, and SF-36 after foot and ankle surgery. *Foot Ankle Int* 2006;27:930–4.
- [4] Court-Brown CM, Schmied M, Schmidt M, Schutte BG. Factors affecting infection after calcaneal fracture fixation. *Injury* 2009;40:1313–5.
- [5] Buckley R, Tough S, McCormack R, Pate G, Leighton R, Petrie D, et al. Operative compared with nonoperative treatment of displaced intra-articular calcaneal fractures: a prospective, randomized, controlled multicenter trial. *J Bone Joint Surg Am* 2002;84:1733–44.
- [6] Gavlik JM, Rammelt S, Zwipp H. Percutaneous, arthroscopically-assisted osteosynthesis of calcaneus fractures. *Arch Orthop Trauma Surg* 2002;122:424–8.
- [7] Zwipp H, Paša L, Žilka L, Amlang M, Rammelt S, Pompach M. Introduction of a new locking nail for treatment of intra-articular calcaneal fractures. *J Orthop Trauma* 2016;30:88–92.
- [8] Gupta A, Ghalambor N, Nihal A, Trepman E. The modified Palmer lateral approach for calcaneal fractures: wound healing and postoperative computed tomographic evaluation of fracture reduction. *Foot Ankle Int* 2003;24:744–53.
- [9] Wagstrom EA, Downes JM. Limited approaches to calcaneal fractures. *Curr Rev Musculoskelet Med* 2018;11:485–94.
- [10] Rammelt S, Gavlik JM, Barthel S, Zwipp H. The value of subtalar arthroscopy in the management of intra-articular calcaneus fractures. *Foot Ankle Int* 2002;23:906–16.
- [11] Hamilton GA, Doyle MD, Castellucci-Garza FM. Arthroscopic-assisted open reduction internal fixation. *Clin Podiatr Med Surg* 2018;35:199–221.
- [12] Piovesana LG, Lopes HC, Pacca DM, Ninomiya AF, Dinato MCME, Pagnano RG. Assessment of reproducibility of sanders classification for calcaneal fractures. *Acta Ortop Bras* 2016;24:90–3.
- [13] Kitaoka HB, Alexander IJ, Adelaar RS, Nunley JA, Myerson MS, Sanders M. Clinical rating systems for the ankle-hindfoot, midfoot, hallux, and lesser toes. *Foot Ankle Int* 1994;15:349–53.
- [14] Slim K, Nini E, Forestier D, Kwiatkowski F, Panis Y, Chipponi J. Methodological index for non-randomized studies (minors): development and validation of a new instrument. *ANZ J Surg* 2003;73:712–6.
- [15] Moher D, Liberati A, Tetzlaff J, Altman DG, PRISMA Group. Preferred reporting items for systematic reviews and meta-analyses: the PRISMA statement. *Int J Surg* 2010;8:336–41.
- [16] Park CH, Yoon DH. Role of subtalar arthroscopy in operative treatment of sanders type 2 calcaneal fractures using a sinus tarsi approach. *Foot Ankle Int* 2018;39:443–9.
- [17] Woon CY-L, Chong K-W, Yeo W, Eng-Meng Yeo N, Wong M-K. Subtalar arthroscopy and fluoroscopy in percutaneous fixation of intra-articular calcaneal fractures: the best of both worlds. *J Trauma* 2011;71:917–25.
- [18] Pastides PS, Milnes L, Rosenfeld PF. Percutaneous arthroscopic calcaneal osteosynthesis: a minimally invasive technique for displaced intra-articular calcaneal fractures. *J Foot Ankle Surg* 2015;54:98–804.
- [19] Gavlik JM, Rammelt S, Zwipp H. The use of subtalar arthroscopy in open reduction and internal fixation of intra-articular calcaneal fractures. *Injury* 2002;33:63–71.
- [20] Yeap EJ, Rao J, Pan CH, Soelar SA, Younger ASE. Is arthroscopic assisted percutaneous screw fixation as good as open reduction and internal fixation for the treatment of displaced intra-articular calcaneal fractures? *Foot Ankle Surg* 2016;22:164–9.
- [21] Sivakumar BS, Wong P, Dick CG, Steer RA, Tetsworth K. Arthroscopic reduction and percutaneous fixation of selected calcaneus fractures: surgical technique and early results. *J Orthop Trauma* 2014;28:569–76.
- [22] Law GW, Yeo NEM, Yeo W, Koo K, Chong KW. Subtalar arthroscopy and fluoroscopy in percutaneous fixation of intra-articular calcaneal fractures. *J Orthop Surg (Hong Kong)* 2017;25:2309499016684995.
- [23] Parisien JS, Vangsness T. Arthroscopy of the subtalar joint: an experimental approach. *Arthroscopy* 1985;1:53–7.
- [24] Janzen DL, Connell DG, Munk PL, Buckley RE, Meek RN, Schechter MT. Intra-articular fractures of the calcaneus: value of CT findings in determining prognosis. *Am J Roentgenol* 1992;158:1271–4.
- [25] Wallin KJ, Cozzetto D, Russell L, Hallare DA, Lee DK. Evidence-based rationale for percutaneous fixation technique of displaced intra-articular calcaneal fractures: a systematic review of clinical outcomes. *J Foot Ankle Surg* 2014;53:740–3.
- [26] DeWall M, Henderson CE, McKinley TO, Phelps T, Dolan L, Marsh JL. Percutaneous reduction and fixation of displaced intra-articular calcaneus fractures. *J Orthop Trauma* 2010;24:466–72.
- [27] Abdelgaid SM. Closed reduction and percutaneous cannulated screws fixation of displaced intra-articular calcaneus fractures. *Foot Ankle Surg* 2012;18:164–79.