



**HAL**  
open science

# A catastrophic antiphospholipid syndrome complicated with heparin-induced thrombocytopaenia, successfully managed with double filtration plasmapheresis, steroids and a direct thrombin inhibitor

Julien Prouvot, Cedric Aglae, Laurent Daniel, Olivier Moranne

## ► To cite this version:

Julien Prouvot, Cedric Aglae, Laurent Daniel, Olivier Moranne. A catastrophic antiphospholipid syndrome complicated with heparin-induced thrombocytopaenia, successfully managed with double filtration plasmapheresis, steroids and a direct thrombin inhibitor. *BMJ Case Reports*, 2019, 12 (9), pp.e231161. 10.1136/bcr-2019-231161 . hal-02796302

**HAL Id: hal-02796302**

**<https://hal.umontpellier.fr/hal-02796302>**

Submitted on 16 Nov 2023

**HAL** is a multi-disciplinary open access archive for the deposit and dissemination of scientific research documents, whether they are published or not. The documents may come from teaching and research institutions in France or abroad, or from public or private research centers.

L'archive ouverte pluridisciplinaire **HAL**, est destinée au dépôt et à la diffusion de documents scientifiques de niveau recherche, publiés ou non, émanant des établissements d'enseignement et de recherche français ou étrangers, des laboratoires publics ou privés.

## Case report

# A catastrophic antiphospholipid syndrome complicated with heparin-induced thrombocytopenia, successfully managed with double filtration plasmapheresis, steroids and a direct thrombin inhibitor

Julien Prouvot,<sup>1,2</sup> Cédric Aglaé,<sup>1,2</sup> Laurent Daniel,<sup>3</sup> Olivier Moranne<sup>1,2</sup>

<sup>1</sup>Service de Néphrologie-Dialyse-Aphérese, Centre Hospitalier Universitaire Caremeau, Nîmes, France

<sup>2</sup>Faculté de Médecine, Université de Montpellier, Montpellier, France

<sup>3</sup>Laboratoire d'Anatomie et Cytologie Pathologiques, Centre Hospitalier Universitaire de la Timone, Marseille, France

## Correspondence to

Julien Prouvot,  
julien.prouvot@chu-nimes.fr

Accepted 21 August 2019

## SUMMARY

A middle-aged woman with history of antiphospholipid syndrome, admitted to our hospital for lethargy and persistent chest pain, developed during hospitalisation intracerebral transverse sinus and sigmoid vein thromboses, retinal thromboses, acute renal failure and cardiac involvement associated with thrombocytopenia. Diagnosis of catastrophic antiphospholipid syndrome was made and treated with IV steroids, heparin infusion and double filtration plasmapheresis (DFPP) without fresh frozen plasma. Heparin-induced thrombocytopenia was second diagnosed because of persistent severe thrombocytopenia after 2 weeks of treatment associated with positive conversion of antibodies against platelet factor 4, and a positive functional assay. The clinical course was complicated by cerebellar haematomas that appeared a few days after the last session of DFPP. Heparin-induced thrombocytopenia was managed by administration of argatroban, a direct thrombin inhibitor with an increase in platelet count. Neurologically, the patient recovered completely and was discharged on vitamin K antagonist treatment and regular dialysis.

## BACKGROUND

Antiphospholipid syndrome (APS) is characterised by the association of a thrombotic clinical event or an adverse obstetrical event with the presence of antiphospholipid antibodies in plasma on at least 2 occasions 12 weeks apart.<sup>1</sup> The most severe and life threatening form of this syndrome with involvement of at least three different organs is called 'catastrophic antiphospholipid syndrome' (CAPS), first described in 1992.<sup>2</sup> Its diagnostic criteria are well established,<sup>3</sup> but its pathophysiology is not well understood, and current treatment recommendations<sup>4</sup> are mainly established from observational studies from the 'CAPS Registry'.<sup>5</sup> Although not so rare,<sup>6</sup> it remains a difficult diagnosis especially when associated with another alternative diagnosis: heparin-induced thrombocytopenia (HIT), which is little described.<sup>7</sup> HIT is an autoimmune disease due to anti-platelet factor 4 (PF4) antibodies, causing platelet activation and multiple thromboses. Stopping heparin therapy is its main treatment.

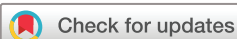We report a complicated case of CAPS associated with HIT with a favourable clinical response under triple therapy with steroids, direct thrombin inhibitor and double filtration plasmapheresis (DFPP) without fresh frozen plasma (FFP) supplementation.

## CASE PRESENTATION

A 47-year-old woman with history of APS, diagnosed a few years ago and under treatment with clopidogrel and aspirin, was admitted to the hospital for persistent chest pain and lethargy. Her blood pressure was normal, her heart rate was regular at 113 beats/min, oxygen saturation was 92% in ambient atmosphere, without fever, skin rash or livedo. Lab tests on admission are shown in [table 1](#). Cardiac troponins were stable a few hours later, and an ECG did not show any sign of myocardial infarction. A CT showed volume overload and mediastinal lymphadenopathies without sign of pulmonary embolism. She was hospitalised for more investigations. Two days later, deep vein thromboses of the left sigmoid and transverse sinus were diagnosed on cerebral MRI ([figure 1](#)) to explain headache and vomiting, with signs of retinal vasculopathy in the ophthalmoscopic examination but with no evidence of intracranial hypertension. IV curative heparin therapy was introduced, with IV moderate doses of glucocorticoids. A few days later, in this context of cerebral thromboses, thrombocytopenia appeared ( $100 \times 10^9/L$ ), leading to a switch from heparin to danaparoid because of suspicion of HIT. Simultaneously, the patient developed a nonobstructive acute kidney injury (AKIN 3) without proteinuria.

## INVESTIGATIONS

There were no signs of haemolysis, but an increase in cardiac troponins (843 µg/L) with no more chest pain. Bone marrow examination showed no sign of central thrombocytopenia and lumbar puncture showed no sign of infection or inflammation. A transjugular renal biopsy was performed, showing a fibrin thrombus within a hilar arteriole compatible with APS renal involvement ([figure 2](#)). Thus, alternative diagnoses (disseminated intravascular coagulation, HIT) were eliminated, and a diagnosis



© BMJ Publishing Group Limited 2019. No commercial re-use. See rights and permissions. Published by BMJ.

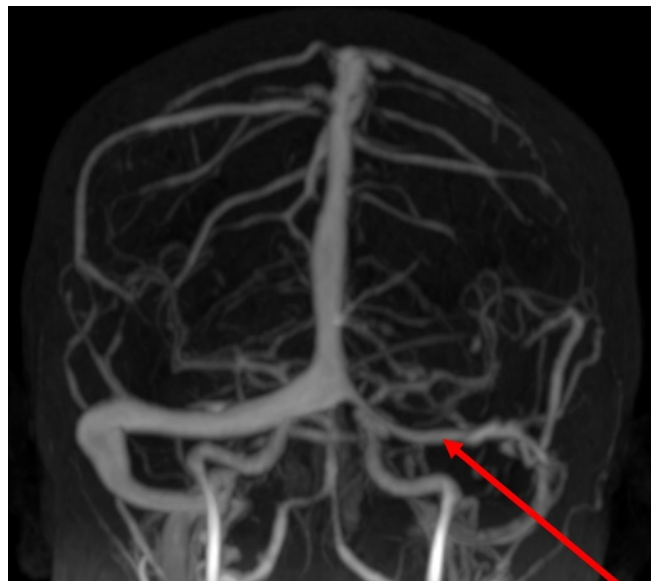
**To cite:** Prouvot J, Aglaé C, Daniel L, et al. *BMJ Case Rep* 2019;**12**:e231161. doi:10.1136/bcr-2019-231161

**Table 1** Biological parameters at day 1

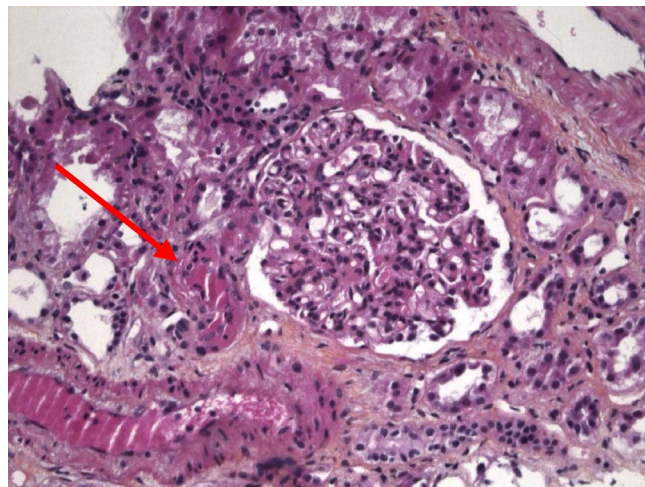
Biological analysis	Value	Unit
Partial prothromboplastin time	2.45	
Prothrombin ratio	86	%
Haemoglobin	85	g/l
Platelet	314	10 <sup>9</sup> /l
Leucocytes	7.04	10 <sup>9</sup> /l
C reactive protein	210.4	mg/l
Natraemia	138	mmol/l
Kalaemia	4.3	mmol/l
Base excess	21	mmol/l
Creatinine	0.86	mg/dl
Urea	13.16	mg/dl
Albumin	32.7	g/l
Calcium	2.36	mmol/l
Aspartate Transaminase (AST)	54	IU/l
Alanine Transaminase (ALT)	83	IU/l
Creatin phosphokinase	32	IU/l
Lactate dehydrogenases	274	IU/l
Haptoglobin	3.45	g/l
Ferritin	160	µg/l
Cardiac troponin	18.2	ng/l

of CAPS was made with haematologic, cerebral, retinal, cardiac and biopsy proven renal involvements.

Treatment for CAPS consisted of high dose glucocorticoids (starting with IV methylprednisolone 10 mg/kg/d) for 3 days and DFPP. Anti-PF4 antibodies were negative and danaparoid was replaced with unfractionated heparin. DFPP sessions were done using a central jugular venous catheter and an HF 440 device (INFOMED) using granopen as the primary filter and cascadeflo EC-50 as secondary filter. For each session, 2000 IU of unfractionated heparin was infused at initiation, with 3.5 litres of plasma filtrated and albumin 20% 100 mL infused at the end. Eight sessions of DFPP were done in 15 days without FFP infusion, with haemodialysis sessions in tandem when necessary. This treatment permitted clinical stabilisation and a decrease



**Figure 1** MRI venography showing thrombosis of left transverse sinus (arrow).



**Figure 2** Kidney biopsy showing a fibrin thrombus within a hilar arteriole (arrow). Hematoxylin, Eosin and Safran stain, x 200.

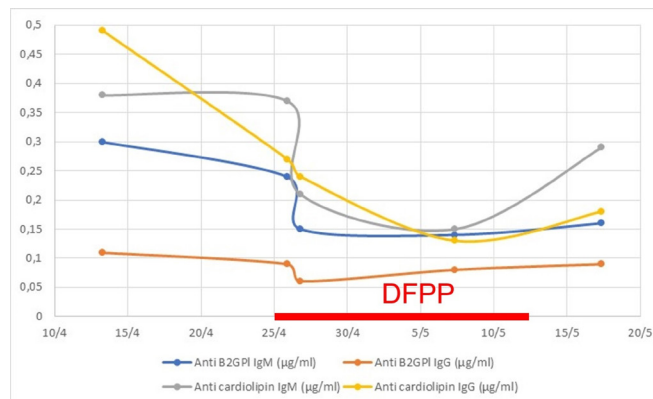
in plasmatic antiphospholipid concentrations during DFPP (figure 3), but thrombocytopaenia persisted.

A few days after the last session of plasmapheresis, the patient presented a cerebellar haematoma while she was still thrombocytopenic but in the absence of physical trauma (figure 4).

She was under unfractionated heparin therapy (anti-factor Xa activity 0.84 U/mL) and vitamin K antagonists, waiting to reach the recommended International Normalized Ratio. Vitamin K antagonists were stopped and new haematologic assessment was performed, in which anti-PF4 antibodies became positive, leading to the diagnosis of HIT and resulting in a switch from IV heparin to IV direct thrombin inhibitor (argatroban), due to the incompatibility of danaparoid with renal replacement therapy. The introduction of argatroban was associated with a normalisation of platelet count in less than a week, and a positive serotonin-release assay confirmed the diagnosis of HIT.

**OUTCOME AND FOLLOW-UP**

Later, after the introduction of vitamin K antagonist (INR 2.5) with aspirin, the patient went home a few days later with a steroid tapering protocol without any neurologic or ophthalmic sequela but with persistent renal failure initially treated with haemodialysis, then switched to peritoneal dialysis. A summary of the case presentation is shown in figure 5.



**Figure 3** Evolution of antiphospholipid antibodies before and after double filtration plasmapheresis.

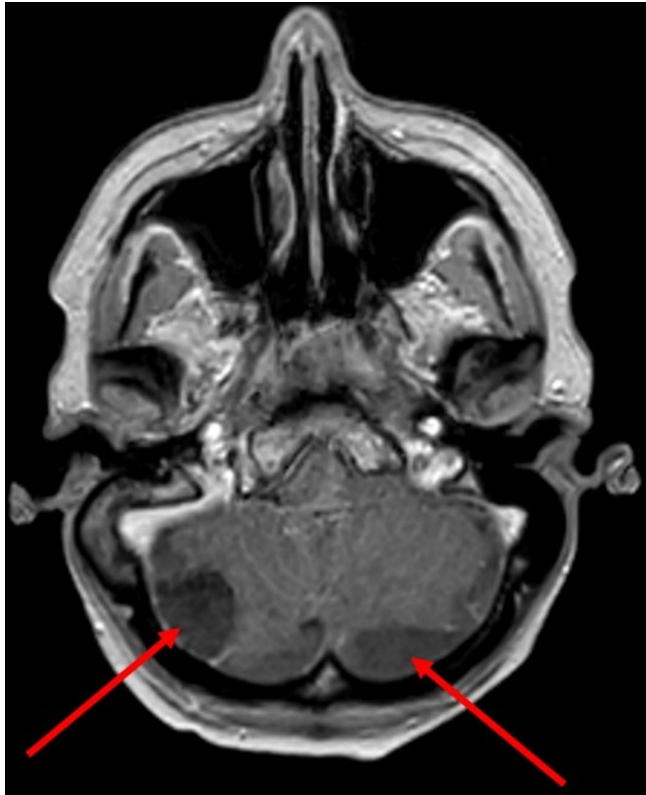

Figure 4 Cerebral MRI showing two cerebellar haematomas (arrows).

DISCUSSION

To our knowledge this is the first case of CAPS associated with HIT treated by triple therapy including DFPP without FFP supplementation, and direct antithrombin with a favourable outcome. Moreover, we report a new association of CAPS with HIT treated with IV direct thrombin inhibitor (argatroban) before a switch to oral vitamin K antagonist. Patient management was further complicated by cerebellar haematoma.

Currently, the recommended treatment is a triple therapy involving curative anticoagulation, high dose glucocorticoids and plasma exchanges (PE).<sup>3 8</sup> There is a debate concerning replacement fluid with PE,<sup>9 10</sup> and no data exist about the efficiency of DFPP without FFP in this indication. In this case, we chose DFPP because of low albumin infusion needs, no systematic FFP infusion and thus no significant fluid intakes. We did

not use IV FFP, which could have brought several coagulation factors, complement activation products and cytokines, and could have increased thrombotic events. Finally, some studies show that FFP leads to infectious or allergic complications more often than albumin.<sup>10 11</sup> Recommendations about CAPS<sup>4</sup> don't specify which apheresis method should be used. The American Society for Apheresis recommends<sup>8</sup> PE and fluid replacement with FFP (alone or in combination with albumin) to keep sufficient quantities of antithrombin, but with low quality evidence. Unfortunately, the CAPS registry does not specify which method is used for therapeutic plasmapheresis.

For the treatment of HIT, we used argatroban instead of danaparoid because of haemodialysis and moreover because the use of direct oral anticoagulant in the context of cerebral haemorrhage is forbidden.<sup>12</sup> A functional assay confirmed our suspicion of HIT, considering the low positive predictive value of anti-PF4-heparin enzyme immunoassays.<sup>13 14</sup> Confirmation was essential in this context of long-term anticoagulation.

Learning points

- ▶ Catastrophic antiphospholipid syndrome (CAPS) must not be forgotten in the context of multi-organ failure, especially in patient with a history of antiphospholipid syndrome (APS).
- ▶ CAPS with heparin-induced thrombocytopenia (HIT) is a rare but potential occurrence with difficult diagnosis. IV direct antithrombin (argatroban) can be an option for CAPS with haemodialysis.
- ▶ Triple therapy including apheresis such as double filtration plasmapheresis without fresh frozen plasma could be proposed in the case of CAPS.
- ▶ Any suspicion of HIT with positive anti-platelet factor 4-heparin enzyme immunoassay must be confirmed by a functional assay, especially in APS.

Acknowledgements Thank you to M Cohen for revision.

Contributors Supervised by OM. Patient was under the care of CA and OM. Biopsy analysis was performed by LD. Report was written by JP, CA, OM and LD.

Funding The authors have not declared a specific grant for this research from any funding agency in the public, commercial or not-for-profit sectors.

Competing interests None declared.

Patient consent for publication Obtained.

Provenance and peer review Not commissioned; externally peer reviewed.

REFERENCES

- 1 Miyakis S, Lockshin MD, Atsumi T, et al. International consensus statement on an update of the classification criteria for definite antiphospholipid syndrome (APS). *J Thromb Haemost* 2006;4:295–306.
- 2 Asherson RA. The catastrophic antiphospholipid syndrome. *J Rheumatol* 1992;19:508–12.
- 3 Asherson RA, Cervera R, de Groot PG, et al. Catastrophic antiphospholipid syndrome: international consensus statement on classification criteria and treatment guidelines. *Lupus* 2003;12:530–4.
- 4 Erkan D, Aguiar CL, Andrade D, et al. 14th International Congress on Antiphospholipid Antibodies: task force report on antiphospholipid syndrome treatment trends. *Autoimmun Rev* 2014;13:699–707.
- 5 Cervera R. CAPS Registry. *Lupus* 2012;21:755–7.
- 6 Cervera R, Piette JC, Font J, et al. Antiphospholipid syndrome: clinical and immunologic manifestations and patterns of disease expression in a cohort of 1,000 patients. *Arthritis Rheum* 2002;46:1019–27.
- 7 Gelisse E, Gratia E, Just B, et al. Catastrophic antiphospholipid syndrome and heparin-induced thrombocytopenia presenting with adrenal insufficiency caused by bilateral hemorrhagic adrenal infarction during sepsis. *Ann Fr Anesth Reanim* 2014;33:e83–4.
- 8 Schwartz J, Padmanabhan A, Aqul N, et al. Guidelines on the use of therapeutic apheresis in clinical practice-evidence-based approach from the writing committee

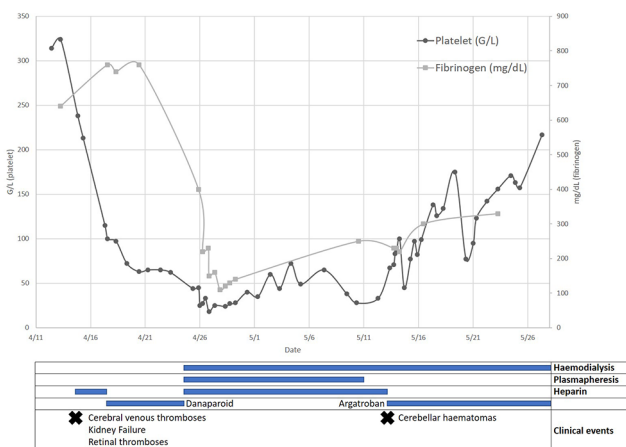


Figure 5 Timing chart.



- of the American Society for Apheresis: the seventh special issue. *J Clin Apher* 2016;31:149–338.
- 9 Özgür G, Beyan C. Therapeutic apheresis in the treatment of catastrophic antiphospholipid syndrome. *Transfus Apher Sci* 2018;57:13–15.
  - 10 Marson P, Bagatella P, Bortolati M, *et al.* Plasma exchange for the management of the catastrophic antiphospholipid syndrome: importance of the type of fluid replacement. *J Intern Med* 2008;264:201–3.
  - 11 Pandey S, Vyas GN. Adverse effects of plasma transfusion. *Transfusion* 2012;52:65S–79.
  - 12 Erkan D, Aguiar CL, Andrade D, *et al.* 14th International Congress on Antiphospholipid Antibodies: task force report on antiphospholipid syndrome treatment trends. *Autoimmun Rev* 2014;13:685–96.
  - 13 Greinacher A. Clinical practice. Heparin-Induced Thrombocytopenia. *N Engl J Med* 2015;373:252–61.
  - 14 Pouplard C, Amiral J, Borg J-Y, *et al.* Decision analysis for use of platelet aggregation test, Carbon 14–Serotonin release assay, and heparin–platelet factor 4 Enzyme-Linked immunosorbent assay for diagnosis of Heparin-Induced Thrombocytopenia. *Am J Clin Pathol* 1999;111:700–6.

Copyright 2019 BMJ Publishing Group. All rights reserved. For permission to reuse any of this content visit <https://www.bmj.com/company/products-services/rights-and-licensing/permissions/>  
BMJ Case Report Fellows may re-use this article for personal use and teaching without any further permission.

Become a Fellow of BMJ Case Reports today and you can:

- ▶ Submit as many cases as you like
- ▶ Enjoy fast sympathetic peer review and rapid publication of accepted articles
- ▶ Access all the published articles
- ▶ Re-use any of the published material for personal use and teaching without further permission

### Customer Service

If you have any further queries about your subscription, please contact our customer services team on +44 (0) 207111 1105 or via email at [support@bmj.com](mailto:support@bmj.com).

Visit [casereports.bmj.com](http://casereports.bmj.com) for more articles like this and to become a Fellow