HAL open science

Partial Vertebrectomies without Instrumented Stabilization During En Bloc Resection of Primary Bronchogenic Carcinomas Invading the Spine: Feasibility Study and Results on Spine Balance

Sam Ng, Julien Boetto, Gaëtan Poulen, Jean-Philippe Berthet, Charles Marty-Ané, Nicolas Lonjon

To cite this version:

Sam Ng, Julien Boetto, Gaëtan Poulen, Jean-Philippe Berthet, Charles Marty-Ané, et al.. Partial Vertebrectomies without Instrumented Stabilization During En Bloc Resection of Primary Bronchogenic Carcinomas Invading the Spine: Feasibility Study and Results on Spine Balance. World Neurosurgery, 2019, 122, pp.e1542-e1550. 10.1016/j.wneu.2018.11.098 . hal-02571390

HAL Id: hal-02571390

https://hal.umontpellier.fr/hal-02571390

Submitted on 21 Oct 2021

HAL is a multi-disciplinary open access archive for the deposit and dissemination of scientific research documents, whether they are published or not. The documents may come from teaching and research institutions in France or abroad, or from public or private research centers.

L'archive ouverte pluridisciplinaire **HAL**, est destinée au dépôt et à la diffusion de documents scientifiques de niveau recherche, publiés ou non, émanant des établissements d'enseignement et de recherche français ou étrangers, des laboratoires publics ou privés.

Distributed under a Creative Commons Attribution - NonCommercial 4.0 International License

Version of Record: https://www.sciencedirect.com/science/article/pii/S1878875018326482
Manuscript_d239deb7d8ee5a23eab5d27609081422

Partial vertebrectomies without instrumented stabilization during en bloc resection of primary bronchogenic carcinomas invading the spine: feasibility study and results on spine balance

Authors

Sam Ng [(1)], Julien Boetto [(1)], Gaëtan Poulen [(1)], Jean-Philippe Berthet [(2)], Charles Marty-Ane[(3)], Nicolas Lonjon [(1,4)]

(1) Department of Neurosurgery, Hôpital Guide Chauliac, Montpellier University Medical Center, Montpellier, France

(2) Department of Thoracic surgery, Hôpital Pasteur, Nice University Medical Center, Nice, France

(3) Department of Thoracic surgery, Hôpital Arnaud de Villeneuve, Montpellier University Medical Center, Montpellier, France

(4) INSERM U1198, University of Montpellier, France

Key words

Primary bronchogenic carcinomas, Non-small-cell lung cancers, Lung cancers, Pancoast tumors, Vertebrectomies, Vertebral resection, Spine deformity

Abbreviations and Acronyms

CCA: Coronal Cobb angle

CT: Computed tomography

NSCLC: Non-small-cell lung cancers

PBCIS: Primary bronchogenic carcinomas invading the spine

PET: Positron emission tomography

© 2018 published by Elsevier. This manuscript is made available under the CC BY NC user license
https://creativecommons.org/licenses/by-nc/4.0/

SCA_{EOR}: Sagittal Cobb angle at the edge of the resection

SCA_{T1-T12}: T1-T12 sagittal Cobb angle

VB: Vertebral body

Abstract

Objective:

It is unknown if spinal instrumentation is required to prevent deformity after partial vertebrectomy in the treatment of primary bronchogenic carcinomas invading the spine (PBCIS). In this study, we focus on the postoperative spine deformity in patients operated for partial vertebrectomies without instrumentation during en bloc PBCIS resection. Our objective was to determine if deformity depends on the type of vertebral resection and if any vertebral resection threshold can be observed to justify additional spinal instrumentation.

Methods:

This is a retrospective study, including all patients with PBCIS operated without spinal instrumentation from 2009 to 2018. Partial vertebrectomies were classified into categories A, B and C depending on vertebral resection. Patients had a long-term radiological follow-up assessing the spine deformity evolution.

Results:

Eighteen patients were included. The median follow-up was 27 months. Four patients underwent a secondary posterior instrumentation surgical procedure due to progressive spinal deformity. A low-risk

group of deformation was characterized as type A resection and type B resection on less than three vertebrae.

Conclusion:

There are no validated criteria to justify a systematic spinal instrumentation when performing a partial vertebrectomy during en bloc resection of PBCIS. Performed alone without spine instrumentation, both type A and type B resections on less than three resected vertebrae were not subject to sagittal and coronal deformity even after a long follow-up, emphasizing that a systematic stabilization is not needed in this low-risk group. These results could help to reduce the perioperative morbidity of these procedures that are usually long and complex.

Text

Introduction:

Primary bronchogenic carcinomas invading the spine (PBCIS) are mainly represented by non-small-cell lung cancers (NSCLC)[1,2] located along the costovertebral gutter. When invading the superior pulmonary sulcus tumors (Pancoast tumors), characteristic symptoms are complete or partial Pancoast-Tobias syndrome. Invasion of the ribs, the vertebrae and the subclavian vessels causes pain in the shoulder area; invasion of the lower part of the brachial plexus and invasion of the nerve roots causes radicular pain or muscle weakness; and invasion of the stellate ganglion and sympathetic chain is revealed by Horner syndrome [3,4].

Spinal invasion is commonly considered to be a negative prognostic factor in primary bronchogenic carcinomas, making them historically considered as incurable[5]. With the advances in the delivery of chemotherapy, radiation and surgical management, carefully selected patients with spine-invading NSCLC can be eligible to complete surgical resection, allowing a major increase of survival[6-8]. Neoadjuvant treatment with chemotherapy induction and concurrent radiation followed by complete en bloc resection is now a standard treatment option with demonstrated oncological results[9,10]. This procedure usually requires thoracic and spine surgery teams and the perioperative mortality rate remains high and varies from 9% to 58%[10-12]. A spinal instrumented stabilization is always performed when a complete vertebrectomy is required, increasing the mean operative time, the blood losses and the postoperative morbidities. However, the usefulness of a spinal instrumentation to prevent spine deformity has not yet been assessed, especially concerning partial vertebrectomies. In this study, we focused on the postoperative spine deformity in patients operated with en bloc resection of PBCIS without instrumented stabilization. The objective was to determine if a secondary spine deformity depends on which type of vertebral resection was performed and if any vertebral resection threshold can be observed to justify additional spinal instrumentation.

<u>Patients and Methods:</u>

This is a retrospective single-center study, including all patients with PBCIS operated from 2009 to 2018. Data were retrieved from the electronic medical records. All patients underwent preoperative neoadjuvant chemotherapy and radiation. Immediate preoperative spine invasion was assessed with Weinstein, Boriani and Biagini [13] (WBB) staging (**Figure 1**) and the Spine Instability Neoplastic Score [14] (SINS) (**Table 1**). Both lung, chest wall resection and partial vertebrectomy were performed during a single-stage procedure. Surgical approaches included anterior cervico-thoracotomy (n=1) and posterolateral thoracotomy with extended incision to expose the spine (n=17). No patient underwent spinal instrumentation during procedure.

Surgical technique

The patient is positioned in lateral position to expose the side invaded by the tumor upwards (Shaw-Paulson approach). A posterolateral incision passing below the tip of the scapula is performed. The scapula is then mobilized laterally and superiorly after a careful dissection of the trapezius and rhomboid muscles. The penetration into the chest cavity is performed laterally to identify the tumor without violating its margins. Intrathoracic procedure including lung, bronchus and vascular dissection is performed by the thoracic surgeon. The incision is then extended posteriorly to expose the affected vertebrae. Partial vertebrectomies using osteotomes are then performed in the affected levels. If the posterior vertebral elements are invaded, the tumor is isolated from the unaffected vertebra by performing a unilateral laminectomy. The dura and nerve roots are then gradually exposed.

Invaded nerve roots are clipped to prevent cerebrospinal fluid leakage and cut. The osteotomy is extended to the vertebral body (VB). It is performed medially to the ipsilateral pedicle, allowing a facet and pedicle removal en bloc with the tumor. The invaded VB osteotomy is performed through osteotomy and followed by the section of the anterior longitudinal ligament. A safety margin is respected to avoid any violation of the tumor. After removing the tumor en bloc (**Figure 2**), mediastinal lymphadenectomy is performed.

Spine balance analysis

Immediate postoperative computed tomography (CT) scan were analysed and compared to preoperative CT scan. We used the classification described by Jain[15] (**Figure 3** and **Figure 4**) and created three groups depending on the quantity of resected bone measured on the CT scan: type A were partial vertebrectomies including costotransversectomy and/or less than 25% VB resection, type B were partial vertebrectomies including pedicle resection and/or facetectomy and/or less than 50% VB resection, and type C were partial vertebrectomies including more than 50% VB resection. The amount of resected VB was measured on a single axial section of the immediate postoperative CT scan. We chose systematically the single axial section showing the most extensive resection of the VB. The vertebra with the most important resection was chosen in case of multiple vertebral resection. Two composite groups were also created: a low-risk group of deformity, including group A and group $B_{n<3}$, and a high-risk group including group $B_{n>=3}$ and group C. Operative time length, blood loss volume and hospital length of stay

were recorded. Each patient had a long-term clinical and radiological follow up with spine CT scans and spine X-rays. The end-point of the follow-up was at the time of the last X-ray retrieved from medical records, or at the time of the second surgery for spine stabilization if needed. The need for a second surgery was decided by the spine surgeon and after a multidisciplinary consultation. Reoperation for stabilization was decided according to importance of the progressive spine deformity, back pain, performance status, operability and patient demand. Coronal Cobb angle (CCA), sagittal Cobb angle at the edge of the resection (SCA_{EOR}), T1-T12 sagittal Cobb angle (SCA_{T1-T12}) were reported immediately after surgery and at the end of the follow-up (**Figure 5**). The difference between immediate postoperative angles and the late postoperative angles was then reported and compared between each vertebral resection group and according to the number of resected vertebrae. We also provide a qualitative analysis concerning the risk factors of a sagittal deformity over 5° and 10°.

Statistical analysis:

We used Student's *t*-tests for spine angles analyses. The distribution of categorical variables was compared with Fisher's exact test. All tests were two-sided and a p-value of ≤0.05 was considered to be statistically significant. Statistical analyses were performed using Statview version 5.0 software (SAS Institute, Cary, NC, USA).

Results:

Eighteen patients were included. The median age was 60 years-old (range 46-81 years-old). Demographic and intraoperative data are summarized in

Table 2. WBB staging and SINS are reported in **Table 3**. The tumor histology was adenocarcinoma in 11 patients, squamous cell carcinoma in 5 patients, and undetermined or other NSCLC in 2 patients. The average blood loss was 1614 ml (200-4500 ml) and average operative length was 390 minutes (range 140-650 min). The average hospital length of stay was 13 days (range 5-37 days). No patient suffered from a serious complication within the 30 days following the surgery. A cerebrospinal fluid leak due to a dural tear occurred in one patient. Three patients underwent type A vertebral resection (Group A), fourteen patients underwent type B vertebral resection (Group B) and one patient underwent type C vertebral resection (Group C). Among group B, five patients had less than 3 resected vertebrae (Group $B_{n<3}$) and nine patients had 3 or more resected vertebrae (Group $B_{n>=3}$). The overall average number of resected vertebrae was 2,8 (range, 1-5) from level T1 to T9. The median overall follow-up was 27 months (range 2-109). A second surgical procedure for posterior spinal stabilization was needed for 4 patients (median delay was 8,5 months, range 2-18 months). Among these 4 patients, 3 were re-operated because of back pain and progressive deformity (angles for these patients were reported from preoperative X-rays, and reported in the **Table 4**). All of them had good performance status without progression of their disease. The fourth reoperated patient received emergency surgery for decompression and stabilization 5 months after en bloc resection because of local tumor recurrence revealed by a spinal cord compression. Among the fourteen other patients, three patients died respectively 5 months, 6 months and 34

months after surgery because of the progression of their cancer. Among the remaining patients (n=11), the median follow-up was 36 months (range 10-109). The variation of angles between immediate and late postoperative assessment by specimen and for each groups are reported in **Table 4** and **Table 5**. Since only one patient was in the group C, we did not perform statistical analysis with this subgroup alone. There was no statistical difference on the sagittal or coronal balance between group A and group B (**Table 6**). Within the group B, resection of three vertebrae or more trended to be associated with a higher risk of sagittal deformity, even if the statistical significance was not reached with p=0,061 (SCA_{EOR}) and p=0,066 (SCA_{T1-T12}). Among the composite groups, the high-risk group showed significantly more sagittal deformity at the end of the follow-up (p=0,01) (**Table 6**). We then made a categorical analysis of which patients had a progression of the sagittal kyphosis of more than 5° and more than 10°. We confirmed that the high-risk group was significantly associated with a worsening of the local and regional kyphosis (p=0.01 and p=0.004, respectively) whereas the low-risk group was not (**Table 7**). This trend showing a threshold in term of sagittal balance when more than 3 vertebras were resected was supported by our clinical experience: within the four patients who needed additional spinal stabilization, three patients were from group $B_{n>=3}$ and one of them was from group C, all of them belonging to the high-risk group.

<u>Discussion:</u>

Preoperative status, assessment and staging of the disease

The management of BPCIS has evolved through the last decade. Tumors with an invasion of the spine have long been considered as inoperable and fatal[5]. An appropriate staging with a careful assessment of the oncologic status prior to the surgery is essential to choose between therapeutic options. Actually, an incomplete tumoral resection is associated with a poorer oncologic outcome [6,16]. The Tumor, Node and Metastasis classification makes chest wall involvement at least grade T3 and VB involvement grade T4 [17]. Preoperative evaluation of the mediastinum with CT, MRI, positron emission tomography (PET) and/or mediastinoscopy are required to determine lymph nodes invasion and metastatic status before any curative surgery attempt. The role of preoperative radiotherapy and chemotherapy is widely supported in the literature [5,6,10,18-20]. Potential benefits are the decrease in the size of the tumor, the improved resectability and a lower dissemination rate of the tumor during surgery[10]. Various classifications about primary and secondary bone tumors are provided in the literature. The aim of these classifications is to help the surgeon in planning the most appropriate tumoral resection in spinal tumors. The WBB staging[13] were reported to describe with more accuracy the characteristics of our cohort, even if the relevance of this classification is not evaluated for PBCIS. In our study, the local extension often came from the junction between the rib and the VB by contiguity invasion, explaining why the WBB sector was

usually scored between 3-4 and 9-10 and always started at layer A. The SINS was developed by Fisher et al[14] to define neoplastic-induced instability of the spine. The SINS was also quite homogenous due to contiguity invasion of the VB: involvement of spinal posterior elements was always unilateral (score = 1), without VB collapse (score 0 or 1), and without spinal alignment abnormalities or deformity (score = 0).

Surgical techniques

Different surgical techniques have been described for lung cancers invading the spine. Intralesional resection was studied by several authors like Bolton et al[21] who reviewed two case-series of 17 patients and 39 patients with NSCLC invading the spine, or Bilsky et al[22] who also reported 42 intralesional approach with a combined two-staged procedure (posterolateral approach and midline posterior approach). Grunenwald et al[6] reported a 19-patients study of superior and non-superior sulcus tumors invading the spine treated with en bloc surgical technique. Fadel et al[20] and Collaud et al[16] also performed en bloc resection technique in a 54-patients study (although 17 patients were concerned with hemivertebrectomies) and in a 48-patients study respectively, both with excellent overall survival rates. Rates of local and distant recurrence seem similar between these different methods, whether the en bloc resection or the intralesional technique was performed. However, more recent reports favour en bloc resection through less invasive procedures: Stoker et al[23] reported a case-series

of 8 en bloc resection with a sequential video-assisted thoracoscopic surgery combined with posterior spinal resection, showing a lower estimated blood loss quantity and lower length of the hospital stay. Tomita et al[24] and Jain et al[15] described a single-stage posterior midline approach for en bloc resection with circumferential spinal stabilization. This approach offers a one-stage definitive resection and stabilization. Overall comparison of previously cited studies tends to show a better rate of complete resection with en bloc resection techniques[6,10,16,25]. In our study, all patients underwent a single-stage procedure through a posterolateral thoracotomy with an extended incision over the posterior midline to expose the spine. When an anterior cervico-thoracotomy was required due to anatomical consideration, no second-stage was necessary because posterior spinal instrumentation was not performed. All resections were performed with en bloc technique without violating the edge of the tumors.

Survival status and perioperative morbidity and mortality

In most studies involving surgical treatment with vertebral resection, the 5-year survival rate ranges between 10 and 61%[6,15,21,22]. High rates of postoperative morbidity or mortality[6,10,16,18,20,25] makes surgical management challenging for multidisciplinary teams. Trying to reduce operative time length and blood loss is a key point to improve postoperative course. Various postoperative complications are reported in the literature: bronchopleural fistula, meningitis, atelectasis, acute respiratory distress syndrome, hypovolemia, deep infection, compression

fracture at the distal end of instrumentation, spinal device dislocation or wound dehiscence[23]. Few reports take into consideration operative blood loss and mean operative time. Stoker et al[23] reported a mean estimated blood loss of 813 mL for video-assisted thoracoscopic thoracotomy combined to posterior spinal approach, and an estimated blood loss of 1250 mL concerning opened thoracotomies. In our study, the mean operative time reported was 367 minutes (thoracoscopic thoracotomy) and 518 minutes (opened thoracotomy). Anraku et al[10] reported an analysis over 23 consecutive patients with systematic spinal instrumentation. Nine patients underwent a one-stage operation and 14 underwent a two-stage operation. The average number of vertebrae resected were 3,5 (staged surgery) and 2,5 (1-stage surgery), which seems to be comparable to the average number of vertebrae resected in our study (n=2,8). Mean operative time was 12,3 hours and 19,3 hours respectively with mean blood loss during surgery of 2700 mL and 4000mL respectively. Median duration of hospitalization was 23 days and 2 patients (8,7%) died during immediate postoperative course because of pneumonia and bronchopleural fistula. In our study, we report lower operative blood loss (mean bleeding was 1614 mL), lower operative time (mean operative time was 390 minutes), lower duration of hospitalization (median was 13 days) and no postoperative death.

Spinal instrumentation and spine deformity

There is no consensus about spinal instrumentation after partial vertebrectomy for PBCIS. Bolton et al[21] performed instrumentation

only in case of total vertebrectomy (n=15) excepted for the case of one patient who underwent resection of all posterior elements over two adjacent levels. However, most authors perform at least anterior or posterior instrumentation, or even both anterior and posterior instrumentation in case of pre-existent spinal deformity or multilevel vertebral involvement[26]. From our experience, the outcomes in terms of spinal deformity depend on the type of the vertebral resection and on the number of adjacent resections. It is commonly admitted that type A resections do not require complementary spinal instrumentation whereas type B resections require posterior instrumentation and type C resections require both anterior and posterior instrumentation[15,27]. While we found this postulate acceptable for type A and type C resection, we made the hypothesis that type B resection group does not require complementary spinal instrumentation in any cases. To our knowledge, no vertebral resection threshold was previously reported in the literature to justify spinal instrumentation. There is also a paucity of the literature concerning deformity issues and outcome concerning this population. Our results suggest that type A and type B with less than 3 resected vertebrae (low-risk group) are not subject to important sagittal and coronal deformity even after a late follow-up while type B on more than three vertebrae and type C resection are more likely to present a sagittal deformity. Statistical difference between low risk and high risk groups was only reached in term of sagittal deformity. This suggesting that a systematic stabilization might be avoided in the low-risk group, thus limiting the surgical

morbidity associated with these procedures. However, our study clearly suffers from a lack of statistical power. Further investigations with larger controlled case-series are needed to confirm these results.

Conclusion:

Selected patients with PBCIS are eligible to curative surgical attempt with en bloc resection including complete or partial vertebral resection. There are no validated criteria to justify a systematic spinal instrumentation in these procedures. Our results suggest that selected patients with partial vertebrectomies do not need additional spine stabilization. A low-risk profile remains to be defined with a higher level of evidence but our results suggest that this profile depends on the type of vertebral resection combined with the number of resected vertebrae. These results could help to reduce the perioperative morbidity of these procedures that are usually long and complex. Further prospective studies are needed to validate these preliminary results.

Figures

Figure 1 (COLOR)

Modified Weinstein, Boriani and Biagini (WBB) surgical staging system by consensus of the Spine Oncology Study Group. 12 radiating zones are numbered from 1 to 12 in a clockwise order. Six concentric layers are described: A (extraosseous sof tissues), B (intraosseous superficial), C (intraosseous deep), D (extraosseous extradural), E (extraosseous intradural) and F (Vertebral artery involvement).

Figure 2 (COLOR)

Specimen of an en bloc resected tumor involving lung, chest wall and three vertebrae.

Figure 3 (COLOR)

Different types of partial vertebrectomies: type A partial vertebrectomy includes costotransversectomy and/or less than 25% vertebral body resection, type B partial vertebrectomy includes pedicle resection and/or facetectomy and/or less than 50% vertebral body resection, and type C partial vertebrectomy includes more than 50% vertebral body resection.

Figure 4

CT scan axial section reconstructions showing Type A (A), Type B (B) and Type C (C) partial vertebrectomies.

Figure 5 (COLOR)

Thoracic spine represented on sagittal plane (left) and on coronal plane (right). Yellow marks illustrate T1-T12 sagittal Cobb angle (SCA_{T1-T12}), red marks illustrate sagittal Cobb angle at the edge of the resection (SCA_{EOR}) and blue marks illustrate coronal Cobb angle (CCA).

Tables

Table 1: The Spine Instability Neoplastic Score (SINS)

Table 2: Preoperative spinal invasion assessment: Weinstein, Boriani, Biagini (WBB) classification and Spine Instability Neoplastic Score (SINS).

Table 3: Characteristics of the surgical cohort

Table 4: Difference between immediate and late CCA, SCA_{EOR}, SCA_{T1-T12} by specimen.

Table 5: Difference between immediate and late CCA, SCA_{EOR}, SCA_{T1-T12} by subgroups.

Table 6: Comparison of spine deformity depending on type of vertebral resection

Table 7: Comparison of effectives with variation of the sagittal kyphosis over 5° and over 10°

References

1. Komaki R, Roth JA, Walsh GL, Putnam JB Jr, Vaporciyan A, Lee JS, et al. Out- come predictors for 143 patients with superior sulcus tumors treated by multidisciplinary approach at the University of Texas MD Anderson Cancer Center. Int J Radiat Oncol Biol Phys. 2000;48:347-54.
2. Farray D, Mirkovic N, Albain KS. Multimodality therapy for stage III non-small-cell lung cancer. J Clin Oncol. 2005;23:3257-69.
3. Pancoast HK. Superior pulmonary sulcus tumor: tumor characterized by pain, Horner's syndrome, destruction of bone and atrophy of hand muscles. JAMA 1932;99:1391-6.
4. Tobias JW. Sindrome apico-costo-vertebral doloroso por tumor apexiano: su valor diagnostico en el cancer primitvo pulmonary. Rev Med Latino Am. 1932;17:1522-56.

5. Stamatis G, Djuric D, Eberhardt W, Pottken C, Zaboura G, Fechner S, et al. Post- operative morbidity and mortality after induction chemoradiotherapy for locally advanced lung cancer: an analysis of 350 operated patients. Eur J Cardiothorac Surg. 2002;22:292-7.

6. Grunenwald DH, Mazel C, Girard P, Veronesi G, Spaggiari L, Gossot D, et al.
Radical en bloc resection for lung cancer invading the spine. J Thorac Cardiovasc Surg. 2002;123:271-9.

7. Gandhi S, Walsh GL, Komaki R, Gokaslan ZL, Nesbitt JC, Put- nam JB Jr, et al: A multidisciplinary surgical approach to superior sulcus tumors with vertebral invasion. Ann Thorac Surg 68: 1778–1785, 1999

8. Mazel C, Grunenwald D, Laudrin P, Marmorat JL. Radical excision in the management of thoracic and cervicothoracic tumors involving the spine: results in
a series of 36 cases. Spine. 2003;28:782-92; discussion 92.

9. Rusch VW, Giroux DJ, Kraut MJ, Crowley J, Hazuka M, Winton T, et al. Induction chemoradiation and surgical resection for superior sulcus non-small-cell lung carcinomas: long-term results of Southwest Oncology Group Trial 9416 (Intergroup Trial 0160). J Clin Oncol. 2007;25:313-8.

10. Anraku M, Waddell TK, de Perrot M, et al. Induction chemoradiotherapy facilitates radical resection of T4 non-small cell lung cancer invading the spine. J Thorac Cardiovasc Surg 2009;137:441–447.e1.

11. Sartori F, Rea F, Calabro F, et al. Carcinoma of the superior pulmonary sulcus. Results of irradiation and radical resection. J Thorac Cardiovasc Surg 1992;104:679–83.
12. York JE, Walsh GL, Lang FF, Putnam JB, McCutcheon IE, Swisher SG, et al: Combined chest wall resection with vertebrec- tomy and spinal reconstruction for the treatment of Pancoast tumors. J Neurosurg 91 (1 Suppl):74–80, 1999
13. Boriani S, Weinstein JN, Biagini R, Primary bone tumors of the spine: Terminology and Surgical Staging. Spine. 1997 ;22(9):1036-1044
14. Fisher CG, Keynan O, Boyd MC, Dvorak MF, The surgical management of primary tumors of the spine. Spine 2005 ; 30:1899–1908
15. Jain S, Sommers E, Setzer M, Vrionis F. Posterior midline approach for single-stage en bloc resection and circumferential spinal stabilization for locally advanced Pancoast tumors: technical note. J Neurosurg Spine 2008;9:71-82.
16. Collaud S, Waddell TK, Yasufuku K, Pierre AF, MD, Darling GE, Cypel M, Rampersaud YR, Lewis SJ, Shepherd FA, Leighl NB, Cho J, Bezjak A, Sound Tsao M, Keshavjee S, de Perrot M, Long-Term Outcome after En Bloc Resection of Non–Small-Cell Lung Cancer Invading the Pulmonary Sulcus and Spine J Thorac Oncol. 2013;8: 1538–1544
17. Rami-Porta R, Bolejack V, Giroux DJ, Chansky K, Crowley J, Asamura H, et al; International Association for the Study of Lung Cancer Staging and Prognostic Factors Committee, Advisory Board Members and Participating Institutions. The IASLC Lung

Cancer Staging Project: the new database to inform the eighth edition of the TNM classification of lung cancer. J Thorac Oncol. 2014;9:1618-24.

18. Schirren J, Donges T, Melzer M, Schönmayr R, Eberlein M, Bölükbas S. En bloc resection of non-small-cell lung cancer invading the spine. Eur J Cardiothorac Surg 2011;40:647–654.

19. Stamatis G. Risks of neoadjuvant chemotherapy and radiation therapy. Thorac Surg Clin 2008;18:71–80.

20. Fadel E, Missenard G, Court C, et al. Long-term outcomes of en bloc resection of non-small cell lung cancer invading the thoracic inlet and spine. Ann Thorac Surg 2011;92:1024–1030.

21. Bolton WD, Rice DC, Goodyear A, et al. Superior sulcus tumors with vertebral body involvement: a multimodality approach. J Thorac Cardiovasc Surg 2009;137:1379–1387.

22. Bilsky MH, Vitaz TW, Boland PJ, Bains MS, Rajaraman V, Rusch VW: Surgical treatment of superior sulcus tumors with spinal and brachial plexus involvement. J Neurosurg 97 (3 Suppl): 301–309, 2002

23. Stoker GE, Buchowski JM, Kelly MP, et al. Video-assisted thoracoscopic surgery with posterior spinal reconstruction for the resection of upper lobe lung tumors involving the spine. Spine J 2013;13:68-76.

24. Tomita K,Kawahara N,Baba H,Tsuchiya H,Fujita T,Toribatake Y: Total en bloc spondylectomy. A new surgical technique for primary malignant vertebral tumors. Spine 22:324–333, 1997

25. Yokomise H, Gotoh M, Okamoto T, Yamamoto Y, Ishikawa S, Liu D, et

al. En bloc partial vertebrectomy for lung cancer invading the spine after induction chemoradiotherapy. Eur J Cardiothorac Surg. 2007;31:788-90.

26. Gokaslan ZL, Walsh GL: “Trap door” exposure of the cervicothoracic junction, in Rengachary SS: Neurosurgical Operative Color Atlas, Vol 8. Lebanon, NH: AANS Publications, 1999, pp 253–260

27. Zairi F, Sunna T, Liberman M, Boubez G, Wang Z, Shedid D. Single Posterior Approach for En-Bloc Resection and Stabilization for Locally Advanced Pancoast Tumors Involving the Spine: Single Centre Experience. Asian Spine J. 2016 Dec;10(6):1047-1057

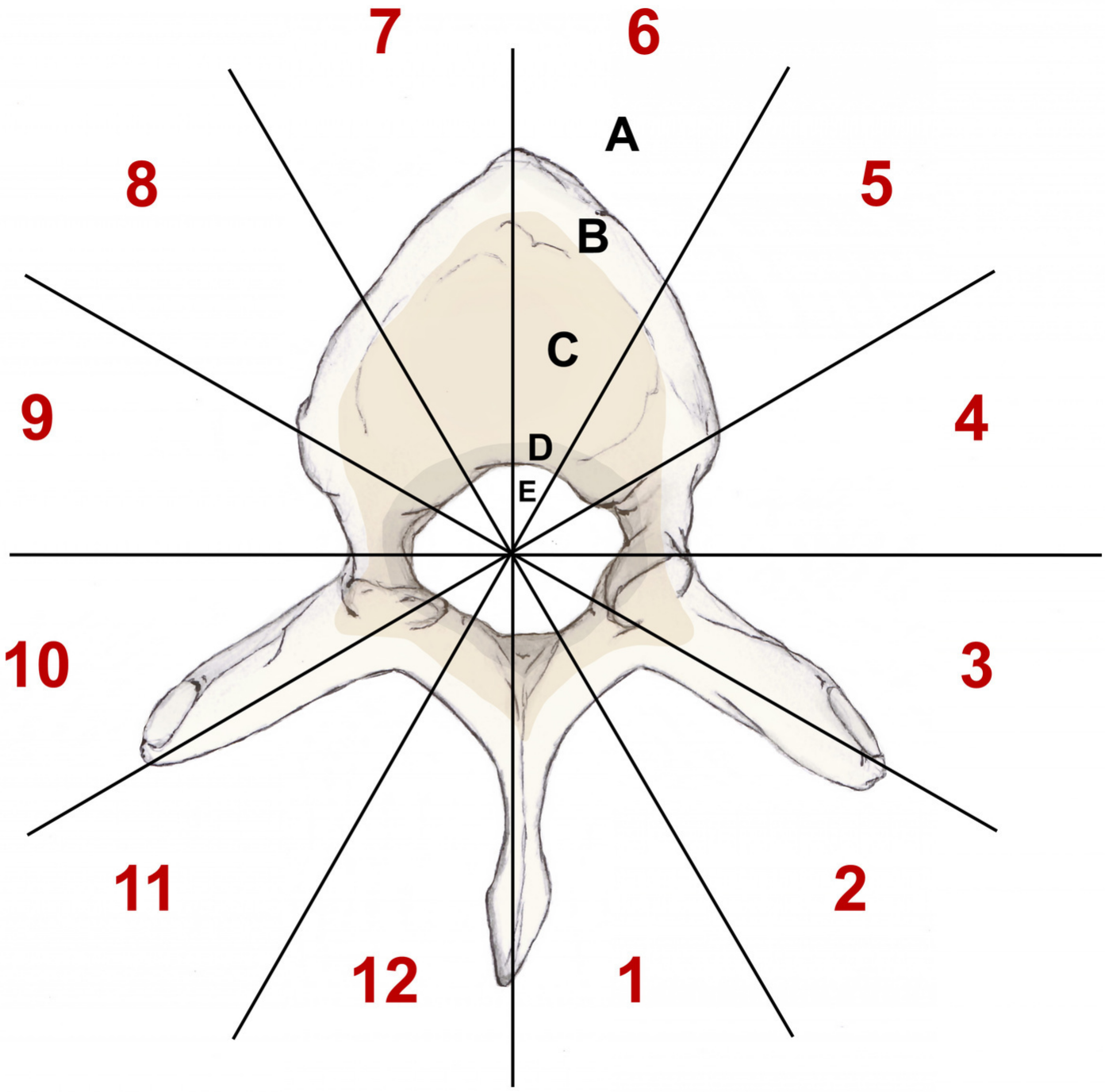
7
6
A
8
5
B
C
9
4
D
E
10
3
11
2
12
1

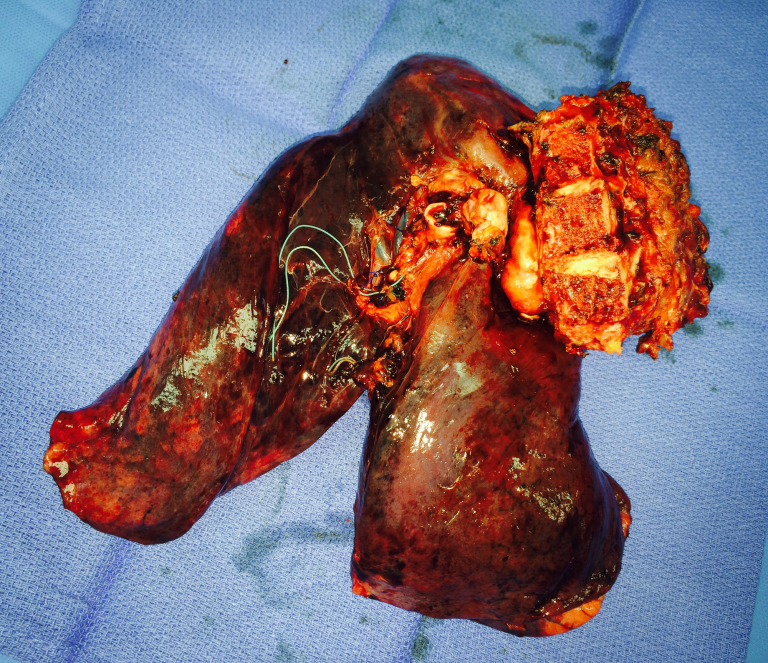

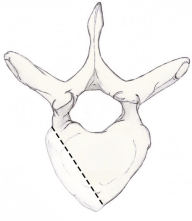

TYPE A

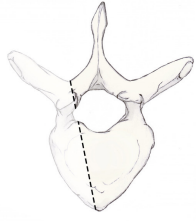

TYPE B

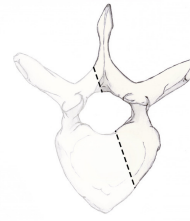

TYPE C

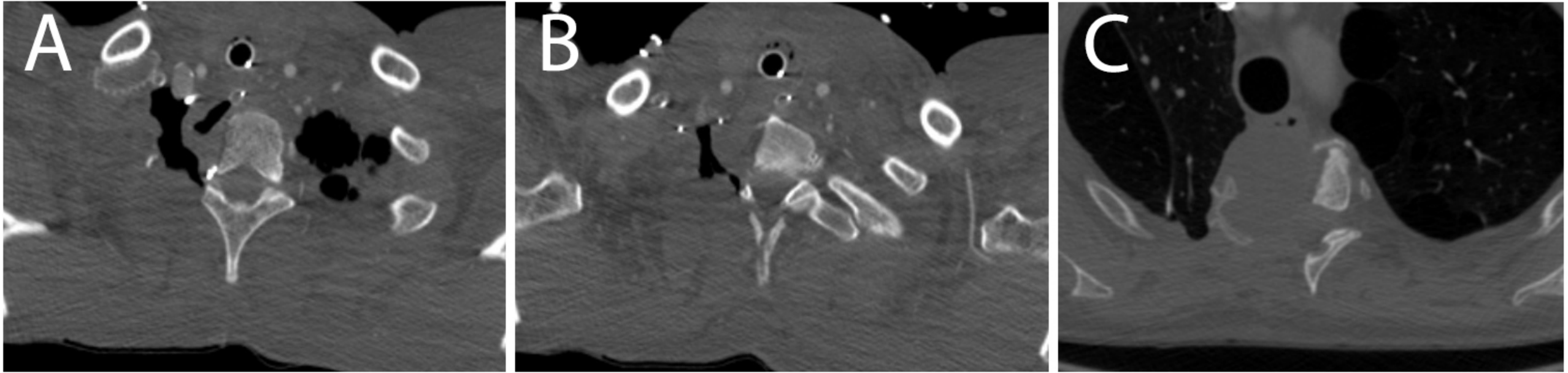
A
B
C

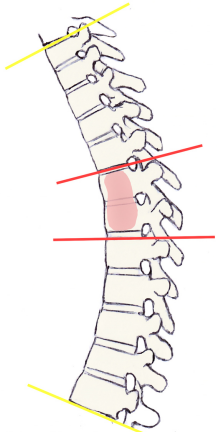

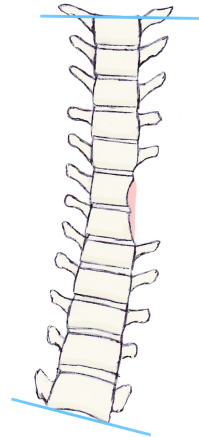

Element of SINS	Score
Location	
Junctional (occiput -C2, C7-T2, T11-L1, L5-S1)	3
Mobile spine (C3-C6, L2-L4)	2
Semi-rigid (T3-T10)	1
Rigid (S2-S5)	0
Pain relief with recumbency and/or pain with movement	
Yes	3
No (occasional pain but not mechanical)	1
Pain free lesion	0
Bone lesion	
Lytic	2
Mixed (lytic/blastic)	1
Blastic	0
Radiographic spinal alignment	
Subluxation/translation present	4
De novo deformity (kyphosis/scoliosis)	2
Normal alignment	0
Vertebral body collapse	
>50% collapse	3
<50% collapse	2
No collapse with >50% body involved	1
None of above	0
Posterolateral involvement of the spinal elements	
Bilateral	3
Unilateral	1
None of the above	0

Table 1: The Spine Instability Neoplastic Score (SINS).

Variables		n (%)
Gender	Female Male	4 (22) 14 (78)
Histology	Adenocarcinoma Squamous cell carcinoma other	11 (61) 5 (28) 2 (11)
Type of vertebral resection	Type A Type B Type C	3 (17) 14 (78) 1 (5)
Number of vertebral resection	One Two Three Four Five	0 9 6 2 1
Level of vertebral resection	T1 T2 T3 T4 T5 T6 T7 T8 T9	4 9 11 9 5 4 2 3 2
Residual margin	R0 R1	16 (89) 2 (11)
Blood loss	Median (ml) Standard deviation (ml) >1000ml 1000-2000ml >2000ml	1400 1157 5 7 6
Hospital length of stay	Median (days) Standard deviation (days) <10 days 10-20 days >20 days	11 7,7 7 (39) 9 (50) 2 (11)
Survival	Survival Death 12-months survival rate (%)	15 (83) 3 (17) 86
Second surgery for spinal instrumentation	Second surgery No second surgery	4 (22) 14 (78)

Table 2: Characteristics of the surgical cohort

Case	Weinstein, Boriani, Biagnini (WBB) classification		Spine Instability Neoplastic Score (SINS)
	WBB Sector	WBB Level	
1	7-8	A-B	7
2	5-6	A-C	4
3	5-7	A-B	7
4	7-10	A-C	11
5	4-6	A-B	7
6	8-10	A-C	8
7	8-11	A-B	9
8	8-10	A-D	9
9	8-10	A-C	9
10	7-9	A-C	7
11	4-7	A-C	9
12	8-10	A-C	7
13	3-7	A-C	9
14	7-10	A-D	9
15	3-5	A-C	9
16	3-4	A-C	7
17	6-9	A-B	7
18	6-11	A-D	10

Table 3: Preoperative spinal invasion assessment: Weinstein, Boriani, Biagini (WBB) classification and Spine Instability Neoplastic Score (SINS).

Case	Vertebral Resection Type	Difference between immediate and late CCA (°)	Difference between immediate and late SCA_{EOR} (°)	Difference between immediate and late SCA_{T1-T12} (°)	Later instrumented stabilization
1	A	0	0	2	no
2	A	0	0	3	no
3	A	3	1	2	no
4	B	8	21	23	yes
5	B	2	1	2	no
6	B	0	6	10	no
7	B	16	23	26	yes
8	B	4	16	16	no
9	B	3	3	6	no
10	B	1	0	2	no
11	B	7	3	4	no
12	B	3	0	3	no
13	B	0	26	30	no
14	B	15	52	58	yes
15	B	6	3	4	no
16	B	3	1	2	no
17	B	0	0	0	no
18	C	16	17	25	yes

Table 4: Difference between immediate and late CCA, SCA_{EOR}, SCA_{T1-T12} by specimen.

Vertebral resection subgroups	Difference between immediate and late CCA (°)	Difference between immediate and late SCA_{EOR} (°)	Difference between immediate and late SCA_{T1-T12} (°)
Group A *mean* *median*	1 0	0 0	2 2
Group B *mean* *median*	5 3	11 4	13 5
Group $B_{n<3}$ *mean* *median*	3 3	1 0	2 3
Group $B_{n>=3}$ *mean* *median*	6 4	16 16	19 16

Table 5: Difference between immediate and late CCA, SCA_{EOR}, SCA_{T1-T12} by subgroups.

Variables	n	p-value	95% Confidence interval
Group A vs Group B Coronal deformity: CCA Sagittal deformity: SCA_{EOR} Sagittal deformity: SCA_{T1-T12}	3 vs 14	0.225 0.235 0.286	-10.300 ; 2.629 -29.857 ; 7.953 -31.439 ; 9.962
Group $B_{n<3}$ vs Group Bn>=3 Coronal deformity: CCA Sagittal deformity: SCA_{EOR} Sagittal deformity: SCA_{T1-T12}	5 vs 9	0.628 0.061 0.066	-7.557 ; 4.749 -32.192 ; 0.903 -34.520 ; 1.320
Low-risk group vs High-risk group Coronal deformity: CCA Sagittal deformity: SCA_{EOR} Sagittal deformity: SCA_{T1-T12}	8 vs 10	0.092 **0.010** **0.007**	-9.566 ; 0.816 -28.726 ; -4.523 -31.982 ; -5.934

Table 6: Comparison of spine deformity depending on type of vertebral resection

Variables	n	SCA_{EOR} (p-values)*	SCA_{T1-T12}(p-values)*
Kyphosis progression over 5° in sagittal plane			
Group Bn<3 versus Group Bn>=3	5 vs 9	**0.031**	**0.031**
Low-risk group vs High-risk group	8 vs 10	**0.025**	**0.004**
Kyphosis progression over 10° in sagittal plane			
Group Bn<3 versus Group Bn>=3	5 vs 9	0.086	**0.031**
Low-risk group vs High-risk group	8 vs 10	**0.013**	**0.004**

**Fisher exact test*

Table 7: Comparison of effectives with variation of the sagittal kyphosis over 5° and over 10°.