



**HAL**  
open science

## Breast tomosynthesis: What do we know and where do we stand?

C. Mandoul, C. Verheyden, Ingrid Millet, Céline Orliac, E. Pages, I. Thomassin, Patrice Taourel

### ► To cite this version:

C. Mandoul, C. Verheyden, Ingrid Millet, Céline Orliac, E. Pages, et al.. Breast tomosynthesis: What do we know and where do we stand?. *Diagnostic and Interventional Imaging*, 2019, 100 (10), pp.537-551. 10.1016/j.diii.2019.07.012 . hal-02565056

**HAL Id: hal-02565056**

**<https://hal.umontpellier.fr/hal-02565056>**

Submitted on 20 Jul 2022

**HAL** is a multi-disciplinary open access archive for the deposit and dissemination of scientific research documents, whether they are published or not. The documents may come from teaching and research institutions in France or abroad, or from public or private research centers.

L'archive ouverte pluridisciplinaire **HAL**, est destinée au dépôt et à la diffusion de documents scientifiques de niveau recherche, publiés ou non, émanant des établissements d'enseignement et de recherche français ou étrangers, des laboratoires publics ou privés.



Distributed under a Creative Commons Attribution - NonCommercial 4.0 International License

# Breast tomosynthesis: what do we know and where do we stand?

Short title:

## Breast tomosynthesis

C. Mandoul<sup>1</sup>, C Verheyden<sup>1</sup>, I Millet<sup>1</sup>, C Orliac<sup>1</sup>, E Pages<sup>1</sup>, I Thomassin<sup>2</sup>, P Taourel<sup>1\*</sup>

<sup>1</sup> Department of Medical Imaging, CHU Montpellier, Hospital Lapeyronie, 34295 Montpellier, France

<sup>2</sup> Department of Imaging, Hospital Tenon-APHP, 75020 Paris, France

**\*Corresponding author:** p-taourel@chu-montpellier.fr

Department of Medical Imaging, CHU Lapeyronie, 371 avenue du Doyen Gaston Giraud, 34295 Montpellier, France.

## **Abstract**

Digital breast tomosynthesis (DBT) is a new imaging technology that addresses the limitation caused by overlapping structures in conventional two-dimensional digital mammography owing to the acquisition of a series of low-dose projection images. This unique technique provides a dual benefit to patients screened for breast cancer. First, DBT increases the cancer detection rate mostly by highlighting architectural distortions and allowing better assessment of masses shape and margins. Second, DBT helps reduce recall rate by discarding asymmetries related to overlapping tissue. However, DBT is not included in the majority of cancer screening programs worldwide. Several issues still need to be addressed such as overdiagnosis and overtreatment, lack of reduction of interval breast cancer, quality control and storage, and radiation dose. In the diagnostic setting, DBT increases the diagnostic accuracy and reduces the number of indeterminate lesions in symptomatic women. Its aforementioned performances regarding asymmetries, masses and architectural distortions allow reducing the number of additional views while working-up a screening-detected lesion. Tumor size is also better assessed at DBT as well as multicentricity, two significant benefits in the staging of breast cancer. Finally, DBT allows a better analysis of scars and helps reduce the rate of indeterminate findings after surgery. Although somewhat limited by high breast density, DBT globally outperforms digital mammography in both screening and diagnostic breast imaging. Additional research is however needed, particularly on relevant screening outcomes. This review describes the main performances of breast DBT in breast cancer screening and diagnosis and the resulting consequences in both settings.

Keywords: Digital breast tomosynthesis; Mammography; Diagnosis; Mass screening; Breast neoplasms.

## **Introduction**

Conventional two-dimensional (2D) mammography is widely acknowledged as the most effective method for detecting breast cancer and improving the outcome of the disease. A meta-analysis of 11 randomized trials concluded that mammography screening leads to a reduction of 20% in breast cancer mortality (1). The main limitation of this technique is a potential tissue overlap that decreases sensitivity and specificity especially in dense breasts. Indeed, detection of the digital signal depends on the total attenuation of the x-ray beam by the intervening tissue. Overlapping tissue can consequently obscure an area of interest and lead to false-negatives, explaining the 15-30% undetected cancers by standard screening. In addition, the overlap of normal structures in the breast can create a pseudolesion, often named summation artifact, which prompts a false-positive result. This leads to further investigations, unnecessary follow-up or biopsy, all responsible for anxiety and non-attendance for next routine breast screening tests (2, 3).

Digital breast tomosynthesis (DBT) is a new imaging technology that addresses this limitation by acquiring a series of low-dose projection images. DBT images are acquired as the x-ray tube travels across a limited arc above the breast and multiple low-dose x-ray exposures are obtained. Reconstruction algorithms allow producing a set of parallel images

planes through the whole breast, typically with 1-mm spacing. Digital mammography (DM) and DBT images can be acquired using the same breast compression (4).

The purpose of this review is to describe the state of the art in terms of performances of breast DBT in breast cancer screening and diagnosis (what do we know ?) and the consequences that have been drawn from these performances (where do we stand ?). Lastly, we shortly address the advanced applications of DBT including DBT-guided biopsy, computer-aided detection (CAD) applied to DBT, contrast-enhanced DBT, and multimodality imaging combining DBT with other imaging techniques.

## Screening

### *What do we know?*

The first studies demonstrating the good performances of DBT in breast cancer screening were retrospective with multiple readers (5,6). They were significantly enriched with patients with breast cancer since the prevalence of malignancy varied between 15 and 50%, so from 30 to 100 times larger than in the usual screening setting. In most of those studies, a large part of the population underwent DBT on the basis of an abnormal mammogram, constituting a selection bias in favor of DM in terms of sensitivity. By contrast, specificity of DBT was also potentially artificially increased since the potential false-positives recruited by DBT were not included. Those enriched retrospective multireader studies showed at least noninferiority of DBT compared to DM, and superiority of DBT when area under curve (AUC) was used for assessment and when two-view DBT + two-view DM were compared to two-view DM. Among those studies, the TOMMY trial was particularly relevant in a population of more than 8000 women with 7684/8869 recruited following a screening mammography recall: AUC DBT + DM was significantly better than DM alone ( $P < 0.001$ ) mostly related to an increased specificity ( $p < .001$ ) in the DBT arms (7). There was a marginal improvement in sensitivity ( $P > 0.07$ ) in the DBT arms except for invasive tumors of size 11–20 mm for which it was significant ( $P < 0.006$ ).

The actual potential improvement in screening may not have been demonstrated due to selection bias in the enriched studies. Studies in real screening conditions can give more realistic data. There were two different designs of studies according to their origin. Most of the studies performed in European centers (8-12) except from one (13) were prospective and paired studies in which patients were their own control (*i.e.*, each woman was imaged at screening with both DM and DBT) whereas studies from the United States (14,15) and one from Italy (13) were retrospective and compared the results of different periods of screening with a different number of patients since some screening centers in both countries have been switching from screening with DM to screening with DBT. Although different in their designs, these studies led to consistent results. A summarize of all studies from Europe and of the two largest multicenter studies from the United States is presented in Tables 1 and 2.

### **Cancer detection**

All studies shown in Table 1 reported on DBT (interpreted with DM or SM) compared with DM alone, except for one study which compared a single DBT stand-alone view with 2 DM



views (12). The effect of DBT on breast cancer detection rates (in absolute terms per 1000 screening examinations) mostly led to a significant increase in breast cancer detection rate ranging from 1.3‰ to 4‰. The only study showing a non-significant 0.5‰ increase was the only randomized and controlled trial ever published on the matter (11). However, as part of the plausible explanations for this discrepancy, this study was performed using a first-generation DBT and synthetic digital mammography unit, possibly perfectible (16). When comparing the radiological appearance of the detected cancers, there was a higher proportion of architectural distortions in DBT compared to DM screening (13, 17).

### **Screening recall**

The effect of DBT on recall rates, in absolute terms, ranged from a statistically significant increase in recall of 1.1% to a statistically significant decrease in recall of 1.8%. The only study showing an increase was also the only one comparing the standard 2 DM views with a single DBT stand-alone view (12) instead of DM + DBT. Even though there is no consensual result about the effect of DBT screening on recall, the large majority of the studies, including the only randomized controlled one, reported a decrease in recall rate. Focal asymmetry was the most affected mammographic finding by the addition of DBT, with a decrease in asymmetry recalls of 58% (18). Indeed, DBT allows discarding focal asymmetries by showing that they are created by crossing Cooper ligaments and fibroglandular tissue.

### **Impact of DBT according to the experience of the readers**

In several studies, implementation of DBT in screening programs showed varying impacts depending on the reader's experience. The increase in sensitivity was significantly greater for junior readers than for senior ones. However, the recall rate decreased with the improvement of specificity, regardless of the reader's experience (19). Moreover, early performance improvements after digital DBT adoption were sustained regardless of DBT volume, radiologist subspecialty, or breast density (20). These results prompt reconsidering our screening practice by including DBT and encourage trials that investigate new mammography strategies (21). It would question the benefit of second reading recommended by European Guidelines for quality assurance in breast cancer screening, given that this practice is an economic burden for every screening program.

### **Value of DBT in women with dense breast**

A known limitation of conventional 2D mammography is tissue overlap, favored by high breast density, which may contribute to obscuring actual breast lesions (*i.e.*, masking effect) and also creating pseudolesions (*i. e.*, summation artifact). Because DBT can reduce tissue superimposition, it could reveal lesions that would otherwise have been missed and reduce false-positive findings by discarding summation artifacts (22). However, to be efficient in that matter, DBT needs interface between tumoral fibroglandular tissue and fat, which may miss in extremely dense breasts, making DBT poorly efficient in detecting additional cancer in BIRADS D patients (23). The value of DBT in women with dense breast is therefore questionable. A meta-analysis including 11 screening studies has shown that DBT + DM increased cancer detection rate in women with dense breasts (24). On the opposite, recall rates were significantly reduced in retrospective studies comparing two groups of participants but not in prospective paired studies (24). Of interest, a recent multicenter study comparing DM

and DBT in two different populations has shown that the benefit brought by DBT for detection of breast cancer was superior in non-dense breast than in dense breast (Odds ratio: 1.55 vs. 1.39, respectively) (25).

To summarize, DBT increases cancer detection rate compared to DM alone, with a variable improvement of up to 4 ‰, more evident in prospective studies than in retrospective ones. The effect of DBT + DM on recall is not as consistent as that for cancer detection. However a majority of studies reported a reduction in recall. Furthermore, although present, the benefit of DBT is lower in patients with dense breast. However, despite its advantages, DBT is not included in any European breast cancer screening recommendation. There are still several issues in that matter which will be discussed in the next section.

### *Where do we stand : the issues that need to be addressed regarding the implementation of DBT as a screening tool*

#### **Over-diagnosis and over-treatment**

DBT can reveal smaller or more subtle cancers than DM. A large fraction of the invasive cancers detected only by DBT present as spiculated masses (Fig. 1) or architectural distortions; the latter in particular being known as a mammographic feature of good prognosis in cancers. Whether detection of those additional cancers will be of benefit in terms of mortality is still debated. A meta-analysis including eleven eligible studies comparing DBT + DM to DM alone showed a significant improvement in detection of invasive cancers, stage T1 and nodal negative cancers, and all histologic grades but more preferentially grade 1 breast cancer (26). However, adding DBT did not increase detection of ductal carcinoma in situ (DCIS), stage  $\geq$  T2 invasive cancers, or nodal-positive cancers (26). The preferential ratio of invasive-to-in situ carcinoma may alleviate some concerns regarding over-diagnosis related to DBT. However, DBT screening leads to a higher proportion of good prognosis cases such as grade 1 cancers and specific favorable histological types like tubular invasive breast cancers (13). It can therefore be suggested that in the absence of DBT screening, some of these cancers would have been detected at subsequent DM screening rounds without consequence on prognosis.

#### **Lack of reduction of interval breast cancer**

This is the main constraint in recommending systematic use of DBT in the screening setting. Published data are very limited but do not demonstrate any significant decrease in interval breast cancer. In a retrospective multicenter study from the United States, the interval breast cancer rate was 0.7 ‰ with DBT and 0.5 ‰ with DM, a non-significant difference (27). However, in this study, medical records were possibly inadequate (27). On the opposite, in a prospective Norwegian trial, clinical follow-up of the patients included was reliable (28). The interval cancer rate post DBT was 2.1 ‰, similar to the one after DM rounds (28). Furthermore, post-DBT interval cancers had similar prognostic criteria compared to the ones in prior DM rounds in terms of size, grade and node status (28).

## **Benign lesions discovered by architectural distortion**

Although the overall recall rate decreased or remained unchanged after DBT, the specific architectural distortion (AD) recall rate increased with DBT (18). The great majority of architectural distortions detected by DBT does not correspond to malignancy and DBT-detected suspicious ADs have a lower malignancy outcome compared with 2D mammography-detected ones, although still high enough to warrant biopsy. In a study assessing the outcome of architectural distortions with no associated mass, one third of the 181 ADs was detected only by DBT with a 10% risk of malignancy, significantly inferior to the 43% risk in 2D-detected AD (29). Furthermore, the radial scar detection rate has dramatically increased from 0.04% to 10% with DBT imaging in a recent study comparing, before and after introduction of DBT, on the one hand the rate of radial scars diagnosed by core biopsy and on the other the rate of upgrading to malignancy or high-risk lesions (30). However malignancy and high risk lesion rates (respectively about 3% and superior to 10%) remained high, maintaining excisional biopsy still necessary (30). Basically, AD is a feature corresponding generally to a benign lesion when discovered by DBT but that still needs at least imaging-guided biopsy and in some cases excisional biopsy. This explains why in some screening programs such as the Verona screening program (31), the recall rate with invasive assessment almost doubled with DBT although the overall recall rate was unchanged.

## **Supplemental screening by breast Ultrasound remains necessary**

Results from the prospective ASTOUND 2 multicenter trial have shown that among patients with dense breasts and a negative 2D mammography, the rate of ultrasound-detected cancers (4.9 ‰) was superior to the DBT-detected one (2.83‰) (32). However, DBT yielded significantly fewer false positive recalls (0.3%) than ultrasound (1%). This important study highlights two points. First, DBT may reveal supplementary cancers in dense breast by comparison to DM, but despite the development of DBT, ultrasound will continue to play a role in dense breast patients screening

## **Quality control and storage**

DBT has raised specific issues regarding quality control and storage. One DBT view takes up the same amount of storage space than one computed tomography (CT) examination. However, the increase of data storage systems capacity and the development of protocols for quality control of the Physical and Technical Aspects of DBT available since march 2018 (Euref tomo protocol version 1-03) have resolved the main problems. Nevertheless, some countries insist on drawing up their specificities for quality control of DBT units.

## **Additional reading time**

Reading time is almost doubled with DBT compared to DM, increasing by 40 to 60 seconds depending on the series (33). Theoretically, this would have negative effects on costs and patients flow. However, the impact varies according to the screening policy used. When screening includes clinical exam, eventual additional views and ultrasound in dense breasts, this additional time does not weigh significantly.

## **Radiation dose**

The risk/benefit ratio of screening programs must take into account radiation dose. Adding DBT to DM more than doubles this dose. When considering the previous issues, this could appear as a major limitation for introducing DBT in breast screening. However synthesized mammography (SM) generated from the DBT data set obviates the additional radiation dose of the conventional 2D exposure; the DBT data set is collapsed into a single slice, similar to the maximum intensity projection (MIP) image in magnetic resonance imaging. Comparative screening studies (10, 34-36) have provided consistent evidence that cancer detection rate do not differ between integrated DM + DBT (range, 5.45-8.5%) and SM + DBT (range, 5.03-8.8%). Also, although the recall measures were relatively heterogeneous among the included studies, little difference was found between the two modalities (24). In two European programs, cancer detection rate with SM + DBT even reached 9.3 and 9.4 % (27, 37). It is therefore clear that transitioning to DBT screening should aim to use synthetic mammography.

In summary, there are still two key issues before recommending DBT in breast cancer screening. First, although including a lot of patients and reporting rather converging results, published trials have some limitations and only one of them, aforementioned, was randomized and controlled. Then, the current literature about DBT overall focuses on traditional performance metrics such as cancer detection rate but does not address clinical outcomes such as disease-free survival or recurrence. However, trials with mortality as endpoint are not relevant given the long time separating diagnosis to death in women with breast cancer. Hence, trials using meaningful improved outcomes such as cancer stage at time of diagnosis and interval breast cancer could inform breast screening practices for the near future. As discussed above, DBT permits diagnosing more cancers of good prognosis. The interpretation of this data is equivocal: detecting smaller cancers could permit a reduction of metastatic cancer and of mortality, but conversely it is unclear whether some of these low-grade and low-stage cancers might have become clinically significant before the next screening round. Data are therefore expected from randomized controlled trials about the real impact of DBT on interval cancers, the most suitable outcome.

## **Diagnosis, staging and follow-up**

### *Diagnosis*

#### **Assessment of symptomatic women**

Little has been published about the role of DBT in symptomatic women (*i. e.*, those with palpable lump, skin retraction or nipple discharge). One study that compared retrospectively DM and DM + DBT in symptomatic patients who had subtle imaging signs concluded that adding DBT to DM in that setting increased diagnostic accuracy and reduced the amount of indeterminate lesions, reclassifying them accurately as either suspicious of malignancy or benign (38). Another study compared the diagnostic efficacy of DM + DBT and DM combined with MRI in symptomatic women (39). Diagnostic performance of DBT and MRI combined with DM was superior to that of DM alone in symptomatic women; MRI + DM were slightly better than DBT + DM, but this difference was not statistically significant (39).

However, in a symptomatic woman, ultrasound should be the first line examination and the contribution of DBT is limited to patients with subtle and/or equivocal findings at DM and ultrasound (38).

### **Work up of screening-detected suspicious finding**

In this setting, the potential benefit of DBT is double: to enable a second look in equivocal cases where no discrete lesion is identified for biopsy, and to analyze the characteristics of a confirmed abnormality shown by DM.

Numerous equivocal findings correspond to asymmetries. The strength of DBT is to decrease the recall rate and the BI-RADS 3 grading, resulting in fewer follow-up diagnostic studies (40). Indeed, this technique allows dismissing an asymmetry when tissue superimposition is shown (Fig 2) or conversely confirming a true asymmetry and sometimes reclassify it as a mass.

Masses are characterized by their shape, margins, density and content. The shape of a lesion is often better defined at DBT (Fig. 3). This can result in reclassification of an irregular shape to a lobular shape, but the lobular feature refers to both benign and malignant lesions (41). The main asset of DBT is to unveil spiculated margins that were previously obscured on DM. This better visualization leads to an increased degree of suspicion, and consequently an increased BIRADS classification (37, 42, 43). On the other hand, DBT loses information about the density of a mass and equal or high density masses on DM may appear low dense on a DBT section (44). Fortunately, this information is given by the synthetic reconstruction. The internal composition of a mass can also be analyzed by DBT. Fat-containing lesions, including lymph nodes, lipomas, hamartomas, and galactoceles are generally considered as benign. However, breast cancers can engulf surrounding adipose tissue as they grow and fat within a mass is not specific for benignity. Thus, masses seen at DBT should be evaluated according to their shape and margins rather than the presence of fat (45). Architectural distortion is a common manifestation of cancers noted at DBT and 50% of cancers that manifested as architectural distortion at DBT were occult at DM. DBT highlights the radiating lines that converge to a point in true architectural distortions or reveals an underlying mass that may have been obscured or occult at DM. In this latter case, the suspicion of malignancy is increased (45).

There has been no definitive consensus in the recent literature regarding characterization of microcalcifications with DBT. Published studies have produced varying results (33). Different techniques used for image acquisition and reconstruction may partly account for this variability. The main limitation of DBT for characterizing microcalcifications is the lower ability to correctly analyze cluster distribution. This limitation may be solved in some systems by the addition of synthetic mammography. A recent study has shown that SM + DBT and DM had similar sensitivity and specificity for the detection of microcalcifications previously identified for recall at screening mammography (46). But it must be kept in mind that DBT with SM does not improve or alter the results of DM in the characterization of microcalcifications. So, in the particular setting of microcalcifications, spot magnification views remain mandatory for appropriate characterization.

An important clinical question is the replacement of additional views by DBT for assessment of screening-detected abnormalities. In clinical practice, this change is already

achieved. In a recent multicenter, retrospective study of 194,437 DBT screenings compared with 131,292 DM screening, women screened with DBT were more likely to proceed directly to ultrasound without additional mammography views compared with women screened with DM (47). However, the body of evidence on DBT by comparison to additional mammography views is limited (48). As shown in Table 3, published data are sparse and conclude to the non-inferiority of DBT by comparison to additional views (49-52). As noted by Li et al., the lack of robust published studies may be explained by the fact that introducing DBT as an imaging work-up tool for screening-recalled abnormalities (following DM screening) seems counter-intuitive when DBT is now being assessed as a primary screening modality (48).

### **Targeted evaluation after MRI**

Second-look ultrasound and MG are fully used to help characterizing an enhancing lesion. Ultrasound allows identification of 50 to 70% of the enhancing lesions. Two studies have focused on the DBT ability to characterize MRI lesions unidentified at targeted ultrasound in patients with newly diagnosed breast cancer (53, 54). They have shown that DBT could help identify 50 to 60% of the lesions unidentified at ultrasound (53, 54).

### *Staging of breast cancer*

#### **Size of the index lesion**

The accuracy of tumor size measured by DBT has been evaluated and compared to that of DM in several studies (55-57). These studies assessed correlation between DBT or DM size and pathological size by choosing a criterion of  $\pm 10$  mm or  $\pm 5$ mm as threshold (55-57). They all concluded that DBT had a better accuracy than DM in measuring tumor size (55-57).

#### **Multifocality and multicentricity**

Little is known about the role of DBT as an adjunct to DM in the staging of women with known breast cancer, and particularly about its ability to diagnose multifocal, multicentric or bilateral disease. In two published studies performed with a lesion-by-lesion analysis, the sensitivity of DM + DBT was about 90% (58, 59). However, these studies pooled index and additional lesions, and no specific data was reported regarding the value of DM + DBT and the contribution of DBT for the diagnosis of multifocal or bilateral cancer. Our group has conducted a prospective study to compare the diagnostic accuracy of DM and DBT combined with DM in the identification of additional ipsilateral and contralateral cancer in women newly diagnosed with breast cancer (60). This study included 166 patients, of which 24 women (14%) exhibited multifocal lesions, 20 (12%) multicentric lesions, 39 (23%) additional ipsilateral and 18 (11%) bilateral lesions (60). We have showed that in terms of sensitivity or of AUC, DM + DBT was superior to DM for the diagnosis of multicentric, additional ipsilateral or contralateral lesions with a gain in sensitivity of about 10% (Fig. 4) (60). However, the performance remained relatively mild with sensitivities varying between 50 and 60% according to the assessed criteria (60). Moreover, the added value of DBT was limited to women with non-dense breasts. In conclusion, DBT could not replace a breast examination obtained using a contrast agent such as MRI (61) in local breast cancer staging when needed.

### *Follow-up after breast conservative surgery*

Similar to screening mammography, DBT also helps differentiate between post treatment changes such as scars or asymmetries due to parenchymal edema and true recurrence. In the only published study on the role of DBT after breast surgery, the addition of DBT to DM reduced the rate of indeterminate findings in surveillance of patients after breast cancer treatment (62). DBT could better identify the fat density within a scar often associated with benign calcifications and differentiate it from a mass indicating tumor recurrence (63).

## **Advanced applications**

### *DBT-guided vacuum assisted breast biopsy*

The development of DBT-guided procedures is not a work in progress since they are performed in daily clinical practice in numerous breast units. Such procedures have two major advantages: making biopsy possible when stereotactic guidance is challenging or when the finding is only seen at DBT such as ADs, and making the procedure faster and easier than traditional stereotactic biopsy thanks to faster acquisition of images and easier and more precise targeting of the abnormality by pseudo-3D scrolling and by avoiding 15 degree stereo pair images. A recent study has shown that DBT-guided biopsy had a higher rate of technical success than does stereotactic vacuum-assisted biopsy and can be performed in less than half the time and with one-fourth of the exposure (64). Given its high technical success rate and its simplicity, DBT-guided VABB, when available, is recommended to be used for suspicious DBT lesions with no ultrasound correlate, even if they are seen at DM (Fig 5).

### *CAD*

CAD can be used in breast imaging (65). Regarding DM, it is used in more than 80% of all screening DM to assist radiologists in detecting breast cancer in the United States (66). On the opposite, it is hardly used in DBT screening. In particular, the use of CAD in the detection of microcalcifications on DBT and SM, a relative weakness of DBT, must be considered as an important development pathway. A radiologist reader study evaluated the use of concurrent computer-aided detection in an enriched sample of DBT cases including calcified and non-calcified lesions (63). Radiologists used concurrent DBT CAD to review CAD-enhanced synthetic images and to navigate to DBT planes to confirm or dismiss potential lesions seen on CAD-enhanced synthetic images. Concurrent use of CAD with DBT resulted in almost 30% faster reading time, while maintaining reader interpretation performance (67). To date, artificial intelligence devices are developing in the field of DBT to reduce oversights errors, improve categorization of lesion seen on DBT and increase confidence in decisions.

### *Contrast-media-enhanced DBT*

Contrast-media-enhanced DBT is technically feasible. There is certainly an interest in associating DBT and contrast-enhanced mammography, particularly in the setting of staging breast cancer for which contrast agent is useful. However, studies are needed to address clinical diagnostic benefit of contrast-media-enhanced DBT.

## *Fusion imaging*

Since DBT provides pseudo-three-dimensional (3D) images of the breast, the development of multimodality systems combining DBT with other 3D modalities such as 3D automated breast ultrasound, radionuclide imaging or even MRI is a promising research approach (68). More advanced prototypes combine 3D-automated breast ultrasound and DBT in a single device: in a recent study, image acquisition and processing by the prototype has been shown to be fast and accurate, with some limitations in ultrasound coverage and image quality (69). However these multimodality systems are still work in progress and may take several years before being used in clinical practice.

## **Conclusion**

In summary, DBT clearly outperforms DM in both screening and diagnostic breast imaging. Although these data are promising, additional research is needed to better assess the effect of DBT in screening outcomes and particularly on the rate of interval cancer. Indeed, a decrease of interval breast cancer in population screened by DBT is needed to recommend DBT in national policies of screening.

## **Acknowledgement**

The authors have no acknowledgement.

The authors state that this work has not received any funding.

## **Conflicts of interest**

The authors declare no conflicts of interest.



## References

1. Independent UK Panel on Breast Cancer Screening. The benefits and harms of breast cancer screening: an independent review. *Lancet* 2012;380:1778-86.
2. McCann J, Stockton D, Godward S. Impact of false-positive mammography on subsequent screening attendance and risk of cancer. *Breast Cancer Res* 2002;4:11.
3. Ong G, Austoker J, Brett J. Breast screening: adverse psychological consequences one month after placing women on early recall because of a diagnostic uncertainty: a multicentre study. *J Med Screen* 1997;4:158-68.
4. Tirada N, Li G, Dreizin D, Robinson L, Khorjekar G, Dromi S et al. Digital breast tomosynthesis: physics, artifacts, and quality control considerations. *Radiographics* 2019;39:413–26.
5. Vedantham S, Karellas A, Vijayaraghavan GR, Kopans DB. Digital breast tomosynthesis: state of the art. *Radiology* 2015; 277:663-84.
6. Michell MJ, Iqbal A, Wasan RK, Evans DR, Peacock C, Lawinski CP et al. A comparison of the accuracy of film-screen mammography, full-field digital mammography, and digital breast tomosynthesis. *Clin Radiol* 2012;67:976–81.
7. Gilbert FJ, Tucker L, Gillan MG, Willsher P, Cooke J, Duncan KA et al. Accuracy of digital breast tomosynthesis for depicting breast cancer subgroups in a UK retrospective reading study (TOMMY Trial). *Radiology* 2015;277:697–706.
8. Skaane P, Bandos AI, Gullien R, Eben EB, Ekseth U, Haakenaasen U et al. Comparison of digital mammography alone and digital mammography plus tomosynthesis in a population-based screening program. *Radiology* 2013; 267:47-56.
9. Ciatto S, Houssami N, Bernardi D, Caumo F, Pellegrini M, Brunelli S et al. Integration of 3D digital mammography with tomosynthesis for population breast-cancer screening (STORM): a prospective comparison study. *Lancet Oncol* 2013;14:583-9.
10. Bernardi D, Macaskill P, Pellegrini M, Valentini M, Fantò C, Ostillio L et al. Breast cancer screening with tomosynthesis (3D mammography) with acquired or synthetic 2D mammography compared with 2D mammography alone (STORM-2): a population-based prospective study. *Lancet Oncol* 2016;17:1105-13.
11. Hofvind S, Holen ÅS, Aase HS, Houssami N, Sebuødegård S, Moger TA, et al. Two-view digital breast tomosynthesis versus digital mammography in a population-based breast cancer screening programme (To-Be): a randomised, controlled trial. *Lancet Oncol* 2019;20:795-805.
12. Zackrisson S, Lång K, Rosso A, Johnson K, Dustler M, Förnvik D, et al. One-view breast tomosynthesis versus two-view mammography in the Malmö Breast Tomosynthesis Screening Trial (MBTST): a prospective, population-based, diagnostic accuracy study. *Lancet Oncol* 2018;19:1493-503.
13. Caumo F, Romanucci G, Hunter K, Zorzi M, Brunelli S, Macaskill P, et al. Comparison of breast cancers detected in the Verona screening program following transition

to digital breast tomosynthesis screening with cancers detected at digital mammography screening. *Breast Cancer Res Treat* 2018;170:391-7.

14. Friedewald SM, Rafferty EA, Rose SL, Durand MA, Plecha DM, Greenberg JS et al. Breast cancer screening using tomosynthesis in combination with digital mammography. *JAMA* 2014; 311:2499-507.

15. Conant EF, Beaber EF, Sprague BL, Herschorn SD, Weaver DL, Onega T et al. Breast cancer screening using tomosynthesis in combination with digital mammography compared to digital mammography alone: a cohort study within the PROSPR consortium. *Breast Cancer Res Treat* 2016;156: 109-16.

16. Zackrisson S. Tomosynthesis in breast screening: great expectations? *Lancet Oncol* 2019;20:745-6.

17. Houssami N, Lång K, Bernardi D, Tagliafico A, Zackrisson S, Skaane P. Digital breast tomosynthesis (3D-mammography) screening: a pictorial review of screen-detected cancers and false recalls attributed to tomosynthesis in prospective screening trials. *Breast* 2016;26:119-34.

18. Lourenco AP, Barry-Brooks M, Baird GL, Tuttle A, Mainiero MB. Changes in recall type and patient treatment following implementation of screening digital breast tomosynthesis. *Radiology* 2015;274:337-42.

19. Thomassin-Naggara I, Perrot N, Dechoux S, Ribeiro C, Chopier J, De Bazelaire C. Added value of one-view breast tomosynthesis combined with digital mammography according to reader experience. *Eur J Radiol* 2015;84:235-41.

20. Miglioretti DL, Abraham L, Lee CI, Buist DSM, Herschorn SD, Sprague BL et al. Digital breast tomosynthesis: radiologist learning curve. *Radiology* 2019;291:34-42.

21. Houssami N, Macaskill P, Bernardi D. Breast screening using 2D-mammography or integrating digital breast tomosynthesis (3D-mammography) for single-reading or double-reading – Evidence to guide future screening strategies. *Eur J Cancer* 2014;50:1799-807.

22. Destounis SV, Morgan R, Arieno A. Screening for dense breasts: digital breast tomosynthesis. *AJR Am J Roentgenol* 2015;204:261-4.

23. Rafferty EA, Durand MA, Conant EF, Copit DS, Friedewald SM, Plecha DM et al. Breast cancer screening using tomosynthesis and digital mammography in dense and nondense breasts. *JAMA* 2016;16:1784-6.

24. Phi XA, Tagliafico A, Houssami N, Greuter MJW, De Bock GH. Digital breast tomosynthesis for breast cancer screening and diagnosis in women with dense breast: a systematic review and meta-analysis. *BMC Cancer* 2018;18:380

25. Conant EF, Barlow WE, Herschorn SD, Weaver DL, Beaber EF, Tosteson ANA et al. Association of digital breast tomosynthesis vs digital mammography with cancer detection and recall rates by age and areast density. *JAMA Oncol* 2019; doi: 10.1001/jamaoncol.2018.7078

26. Yun SJ, Ryu CW, Rhee SJ, et al. Benefit of adding digital breast tomosynthesis to digital mammography for breast cancer screening: a meta-analysis. *Cancer Res* 2017;164:557-69.
27. Mc Donald ES, Oustimov A, Weinstein SP, Synnestvedt MB, Schnall M, Conant EF et al. Effectiveness of digital breast tomosynthesis compared with digital mammography: outcomes analysis from 3 years of breast cancer screening. *JAMA Oncol* 2016;6: 737-43.
28. Skaane P, Sebuødegård S, Bandos AI, et al. Performance of breast cancer screening using digital breast tomosynthesis: results from the prospective population-based Oslo Tomosynthesis Screening Trial. *Cancer Res* 2018;169:489–96.
29. Alshafeiy TI, Nguyen JV, Rochman CM, Nicholson BT, Patrie JT, Harvey JA. Outcome of architectural distortion detected only at breast tomosynthesis versus 2D mammography. *Radiology* 2018;288:38–46.
30. Phantana A, Forster M, Warren Y et al. Rate of radial scars by core biopsy and upgrading to malignancy or high-risk lesions before and after introduction of digital breast tomosynthesis. *Cancer Res* 2019;173: 23-9.
31. Caumo F, Zorzi M, Brunelli S, Romanucci G, Rella R, Cugola L et al. Digital breast tomosynthesis with synthesized two-dimensional images versus full-field digital mammography for population screening: outcomes from the Verona screening program. *Radiology* 2018;287:37–46.
32. Tagliafico AS, Mariscotti G, Valdora F, Durando M, Nori J, La Forgia D, et al. A prospective comparative trial of adjunct screening with tomosynthesis or ultrasound in women with mammography-negative dense breasts (ASTOUND-2). *Eur J Cancer* 2018;104:39-46.
33. Gilbert FJ, Tucker L, Young KC. Digital breast tomosynthesis (DBT): a review of the evidence for use as a screening tool. *Clin Radiol* 2016;71:141-50.
34. Skaane P, Bandos AI, Eben EB, Jepsen IN, Krager M, Haakenaasen et al. Two-view digital breast tomosynthesis screening with synthetically reconstructed projection images: Comparison with digital breast tomosynthesis with full-field digital mammographic images. *Radiology* 2014: 271:655-63.
35. Zuckerman SP, Conant EF, Keller BM, Maidment AD, Barufaldi B, Weinstein SP et al. Implementation of synthesized two-dimensional mammography in a population-based digital breast tomosynthesis screening program. *Radiology* 2016;281:730-6.
36. Aujero MP, Gavenonis SC, Benjamin R, Zhang Z, Holt JS. Clinical performance of synthesized two-dimensional mammography combined with tomosynthesis in a large screening population *Radiology* 2017;28:70-6.
37. Hofvind S, Hovda T, Holen ÅS, Lee CI, Albertsen J, Bjørndal H et al. Digital breast tomosynthesis and synthetic 2D mammography versus digital mammography: evaluation in a population-based screening program. *Radiology* 2018;287:787–94.
38. Bansal GJ, Young P. Digital breast tomosynthesis within a symptomatic "one-stop breast clinic" for characterization of subtle findings. *Br J Radiol* 2015;88:1053.

39. Tang W, Hu X, Zhu H, Wang QF, Gu YJ, Peng WJ. Digital breast tomosynthesis plus mammography, magnetic resonance imaging plus mammography and mammography alone: a comparison of diagnostic performance. *Clin Hem Micro* 2017;66:105-16.
40. Raghu M, Durand MA, Andrejeva L et al. Tomosynthesis in the diagnostic setting: changing rates of BI-RADS final assessment over time. *Radiology* 2016;281:54–61
41. Zuley ML, Bandos AI, Ganott MA, Sumkin JH, Kelly AE, Catullo VJ et al. Digital breast tomosynthesis versus supplemental diagnostic mammographic views for evaluation of noncalcified breast lesions. *Radiology* 2013;266:89–95.
42. Spak DA, Plaxco JS, Santiago L, Dryden MJ, Dogan BE. BI-RADS® fifth edition: A summary of changes. *Diagn Interv Imaging* 2017;98:179-90.
43. Kinkel K. The never-ending success story of BI-RADS. *Diagn Interv Imaging* 2017;98:177-8.
44. Peppard HR, Nicholson BE, Rochman CM, Merchant JK, Mayo RC 3rd, Harvey JA. Digital breast tomosynthesis in the diagnostic setting: indications and clinical applications. *Radiographics* 2015;35:975–90.
45. Freer PE, Wang JL, Rafferty EA. Digital breast tomosynthesis in the analysis of fat-containing lesions. *Radiographics* 2014;34:343–58.
46. Lai YC, Ray KM, Lee AY, Hayward JH, Freimanis RI, Lobach IV et al. Microcalcifications detected at screening mammography: synthetic mammography and digital breast tomosynthesis versus digital mammography. *Radiology* 2018;289:630–8.
47. Alsheik NH, Dabbous F, Pohlman SK, et al. Comparison of resource utilization and clinical outcomes following screening with digital breast tomosynthesis versus digital mammography: findings from a learning health system. *Acad Radiol* 2019;26:597–605.
48. Li T, Marinov LM, Houssami N. Digital breast tomosynthesis (3D mammography) for breast cancer screening and for assessment of screen-recalled findings. *Expert Rev Ther* 2017;18:785-91.
49. Heywang-Kobrunner S, Jaensch A, Hacker A et al. Value of digital breast tomosynthesis versus additional views for the assessment of screen-detected abnormalities - a first analysis. *Breast Care* 2017;12: 91-6.
50. Whelehan P, Heywang-Köbrunner SH, Vinnicombe SJ et al. Clinical performance of Siemens digital breast tomosynthesis versus standard supplementary mammography for the assessment of screen-detected soft-tissue abnormalities: a multi-reader study. *Clini Radiol* 2017;72: 95.e9-15.
51. Brandt KR, Craid DA, Hoskins TL et al. Can digital breast tomosynthesis replace conventional diagnostic mammography views for screening recalls without calcifications? A comparison study in a simulated clinical setting. *AJR Am J Roentgenol* 2013;200: 291-8.
52. Tagliafico A, Astengo D, Cavagnetto F, Rosasco R, Rescinito G, Monetti F et al. One-to-one comparison between digital spot compression view and digital breast tomosynthesis. *Eur Radiol* 2012;22:539-44.

53. Clauser P, Carbonaro LA, Pancot M, Girometti R, Bazzocchi M, Zuiani C, et al. Additional findings at preoperative breast MRI: the value of second-look digital breast tomosynthesis. *Eur Radiol* 2015;25:2830-9
54. Mariscotti G, Houssami N, Durando M, Campanino PP, Regini E, Fornari A, et al. Digital breast tomosynthesis (DBT) to characterize MRI-detected additional lesions unidentified at targeted ultrasound in newly diagnosed breast cancer patients. *Eur Radiol* 2015;25:2673-81.
55. Förnvik D, Zackrisson S, Ljungberg O, Svahn T, Timberg P, Tingberg A et al. Breast tomosynthesis: accuracy of tumor measurement compared with digital mammography and ultrasonography. *Acta Radiol* 2010;51:240-7.
56. Mun HS, Kim HH, Shin HJ, Cha JH, Ruppel PL, Oh HY et al. Assessment of extent of breast cancer: comparison between digital breast tomosynthesis and full-field digital mammography. *Clin Radiol* 2013;68:1254-9.
57. Luparia A, Mariscotti G, Durando M, Ciatto S, Bosco D, Campanino PP et al. Accuracy of tumor size assessment in the preoperative staging of breast cancer: comparison of digital mammography, tomosynthesis, ultrasound and MRI. *Radiol Med* 2013;118:1119-36.
58. Mariscotti G, Durando M, Houssami N, et al. Comparison of synthetic mammography, reconstructed from digital breast tomosynthesis, and digital mammography: evaluation of lesion conspicuity and BI-RADS assessment categories. *Breast Cancer Res* 2017;166:765-73.
59. Kim WH, Chang JM, Moon HG et al. Comparison of the diagnostic performance of digital breast tomosynthesis and magnetic resonance imaging added to digital mammography in women with known breast cancers. *Eur Radiol* 2016;26:1556-64.
60. Fontaine M, Tourasse C, Pages E, Laurent N, Laffargue G, Millet I et al. Local tumor staging of breast cancer: digital mammography versus digital mammography plus tomosynthesis. *Radiology* 2019;291:594-603.
61. Thakran S, Gupta PK, Kabra V, Saha I, Jain P, Gupta RK et al. Characterization of breast lesion using T1-perfusion magnetic resonance imaging: qualitative vs. quantitative analysis. *Diagn Interv Imaging* 2018;99:633-42.
62. Sia J, Moodie K, Bressel M, Lau E, Gyorki D, Skandarajah A et al. A prospective study comparing digital breast tomosynthesis with digital mammography in surveillance after breast cancer treatment. *Eur J Cancer* 2016; 61: 122-7.
63. Ramani SK, Rastogi A, Mahajan A, Nair N, Shet T, Thakur MH. Imaging of the treated breast post breast conservation surgery/oncoplasty: pictorial review. *World J Radiol* 2017;9:321-9.
64. Bahl M, Maunglay M, D'Alessandro HA, Lehman CD. Comparison of upright digital breast tomosynthesis-guided versus prone stereotactic vacuum-assisted breast biopsy. *Radiology* 2019;290:298-304.
65. Chamming's F, Ueno Y, Aldis A, Seidler M, Mesurolle B, Omeroglu A, et al. Enhancement of breast cancer on pre-treatment dynamic contrast-enhanced MRI using

computer-aided detection is associated with response to neo-adjuvant chemotherapy. *Diagn Interv Imaging* 2018;99:773-81.

66. Lehman CD, Wellman RD, Buist DS, Kerlikowske K, Tosteson AN, Miglioretti DL. Diagnostic accuracy of digital screening mammography with and without computer-aided detection. *JAMA Intern Med* 2015; 175:1828-37.

67. Benedikt RA, Boatsman JE, Swann CA, Kirkpatrick AD, Toledano AY. Concurrent computer-aided detection improves reading time of digital breast tomosynthesis and maintains interpretation performance in a multicase study. *AJR Am J Roentgenol* 2018;210: 685–94.

68. Vourtsis A. Three-dimensional automated breast ultrasound: technical aspects and first results. *Diagn Interv Imaging* 2019; doi: 10.1016/j.diii.2019.03.012.

69. Schaeffgen B, Heil J, Barr RG, Radicke M, Harcos A, Gomez C et al. Initial results of the FUSION-X-US prototype combining 3D automated breast ultrasound and digital breast tomosynthesis. *Eur Radiol* 2018;28:2499-506.

## Figures captions

Figure 1: 77-year-old woman with invasive breast carcinoma. Two-dimensional cranio-caudal (a) and mediolateral oblique (b) mammography of the right breast shows no abnormality. Cranio-caudal digital breast tomosynthesis (c) of the same breast unveils an irregular mass with spiculated margins (arrow). Invasive carcinoma was confirmed after histopathological analysis of biopsy specimen.

Figure 2: 53-year-old woman who underwent breast screening. Two-dimensional cranio-caudal mammography of the left breast (a) shows an asymmetry (arrow) Cranio-caudal digital breast tomosynthesis of the same breast (b) discards it by showing no underlying mass but overlapping structures.

Figure 3: 43-year-old woman with breast fibroadenoma. Two-dimensional cranio-caudal (a) and mediolateral oblique (b) mammography of the left breast shows an oval mass with poorly defined margins (arrows). Cranio-caudal digital breast tomosynthesis of the same breast (c) and zoomed on the area of interest (d) allows better visualization of the microlobulated margins (arrow). Histopathological analysis revealed fibroadenoma.

Figure 4: 73-year-old woman who underwent breast screening. Two-dimensional cranio-caudal mammography of the right (a) and left breast (b) shows architectural distortion in the right breast (arrow) and no significant finding in the left breast. Cranio-caudal digital breast tomosynthesis of the right breast (c) and of the left breast (d) confirms the architectural distortion (arrow in c) and highlights two spiculated masses in the contralateral breast (arrows in d). Biopsy revealed invasive ductal carcinoma of the right breast and invasive lobular carcinoma of the left breast.

Figure 5: 77-year-old woman who underwent breast screening. Two-dimensional cranio-caudal (a) and mediolateral oblique (b) mammography of the right breast shows no abnormality. Cranio-caudal digital breast tomosynthesis (DBT) of the same breast (c) highlights a small mass with spiculated margins (arrow) whereas no lesion was visible at ultrasound. DBT-guided biopsy of the right breast using a cranio-caudal approach (d) revealed an invasive carcinoma (arrow).

**Table 1.** Results of digital breast tomosynthesis in breast screening: Cancer detection rate  
Note.-. DM: Digital mammography; DBT: Digital breast tomosynthesis; SM: Synthetic mammography; MLO: mediolateral oblique; vs: versus

\*Except for Zackrisson's study (DBT stand-alone)

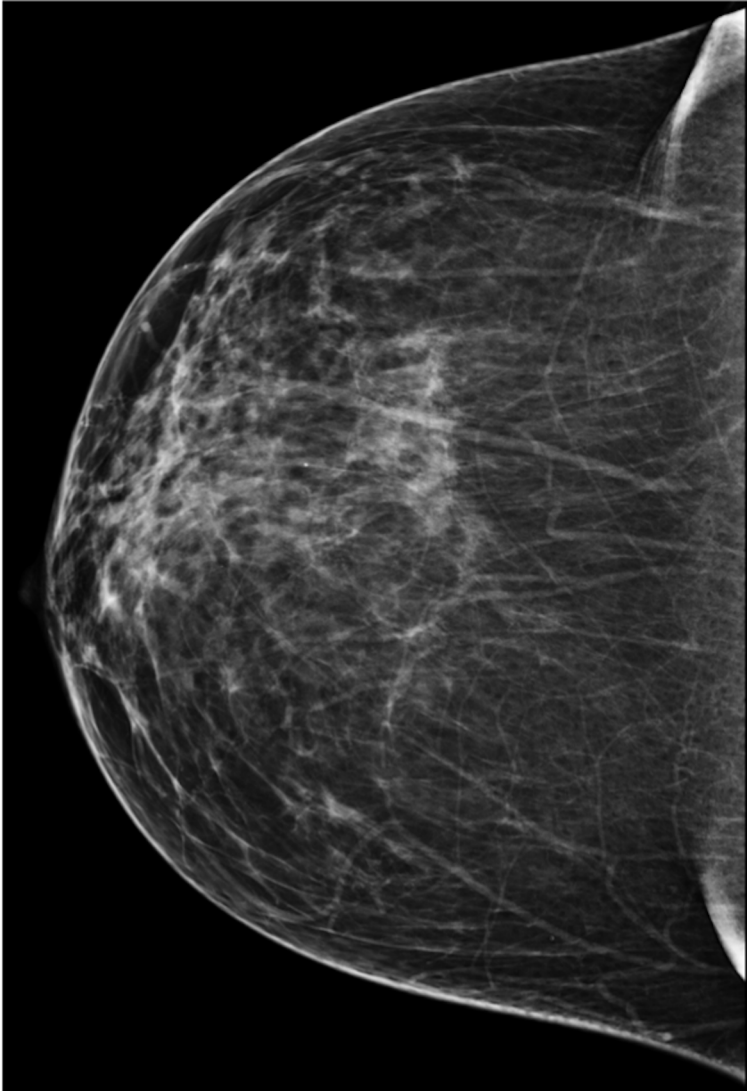**Table 2:** Results of digital breast tomosynthesis in breast screening: Recall rate

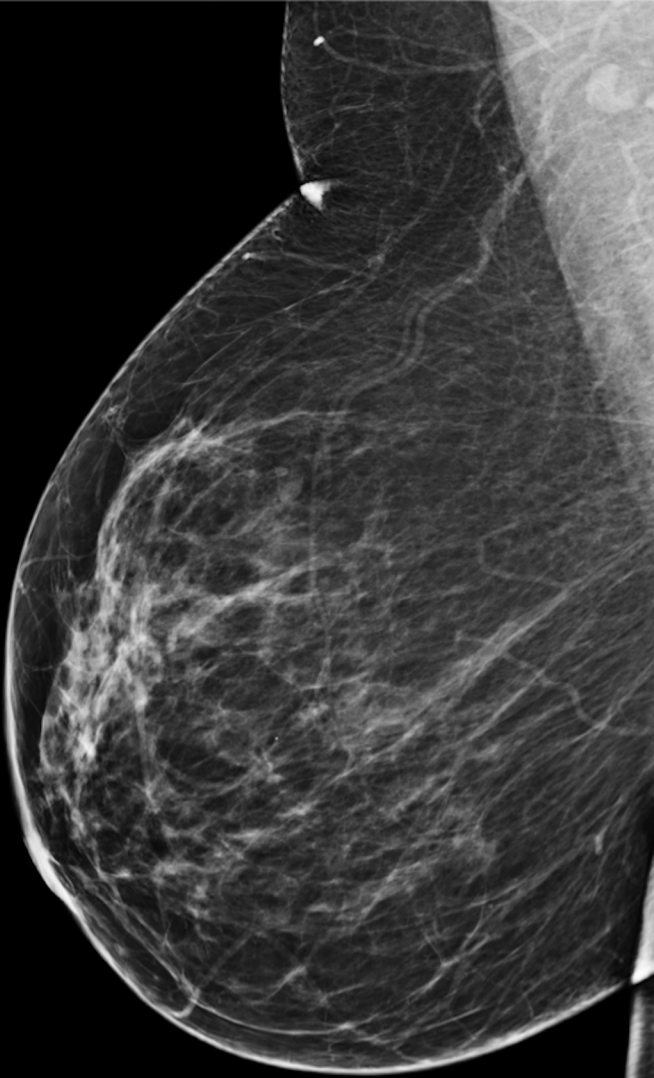
Note.-. DM: Digital mammography; DBT: Digital breast tomosynthesis; SM: Synthetic mammography; MLO: mediolateral oblique; vs: versus

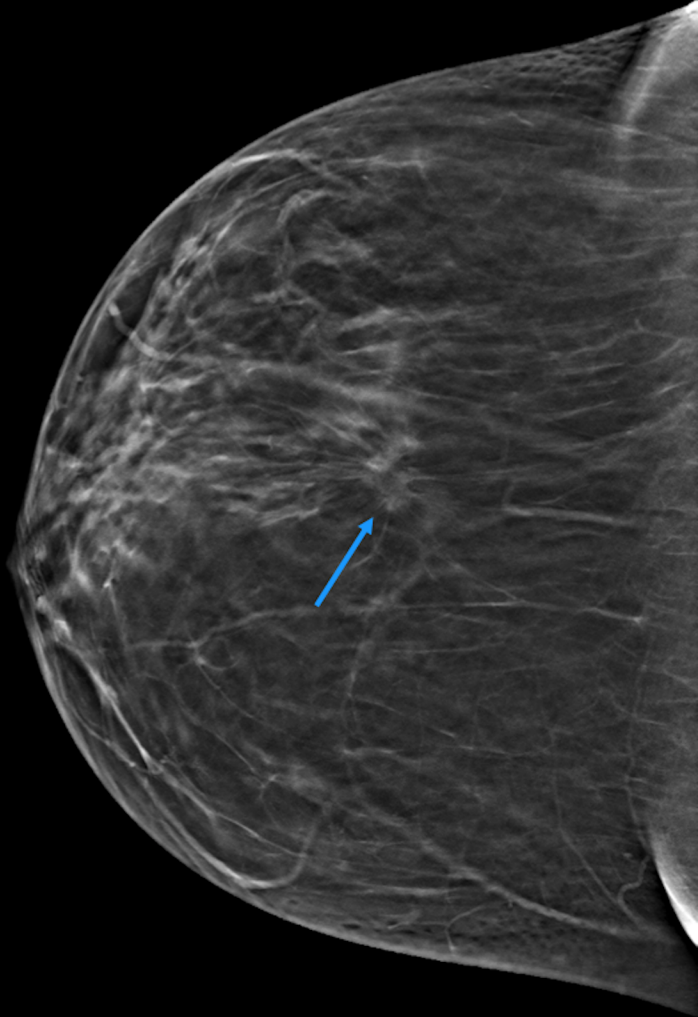
**Table 3:** Diagnostic performances of digital breast tomosynthesis versus additional conventional mammography views for assessment of screen-detected abnormalities

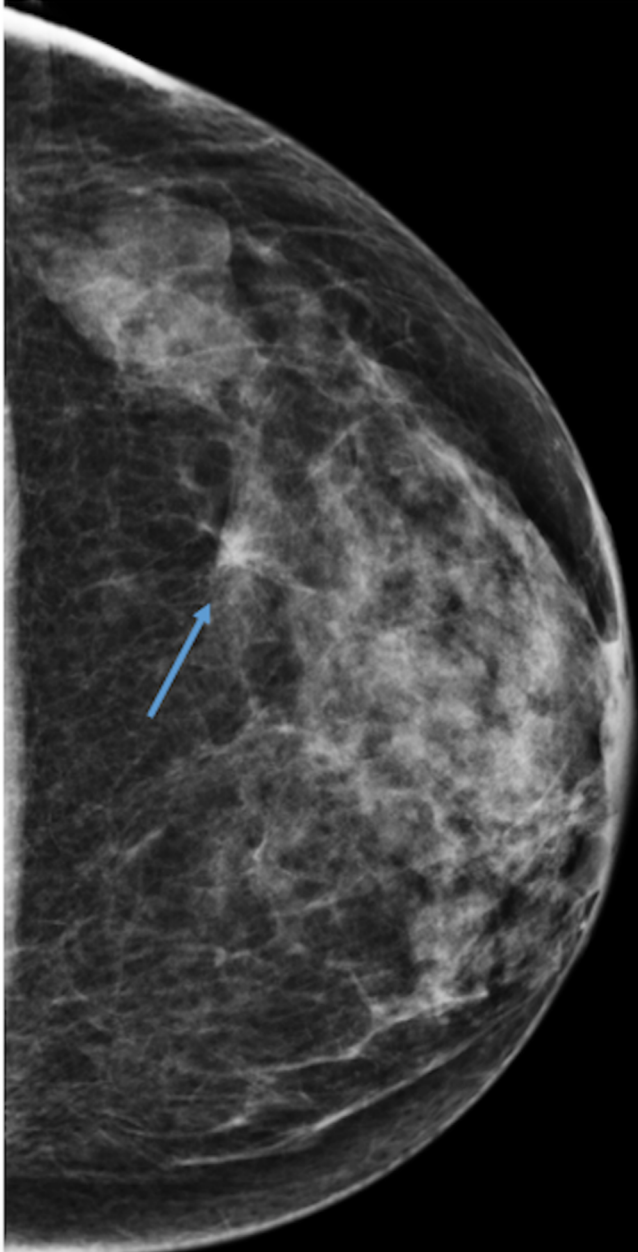
Note.-. BC: Breast cancer; DBT: Digital breast tomosynthesis; DM: Digital mammography; Se: Sensitivity; AV: Additional views; N.S.: Non-significant; Sp: Specificity

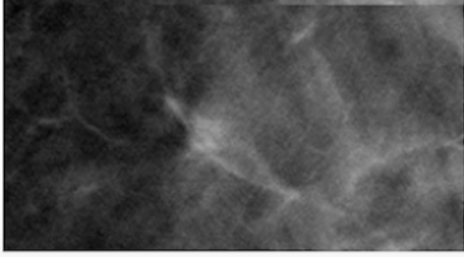
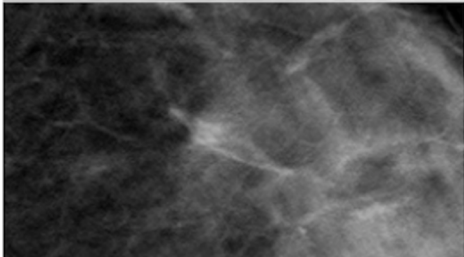
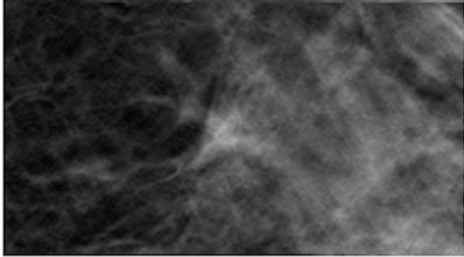
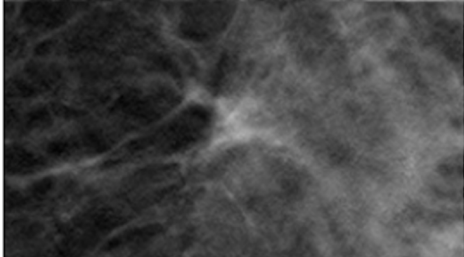
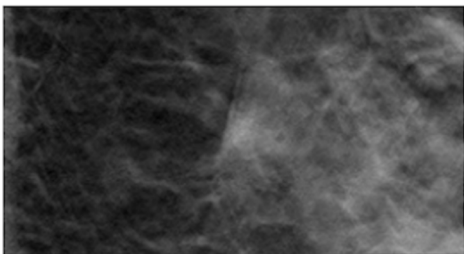


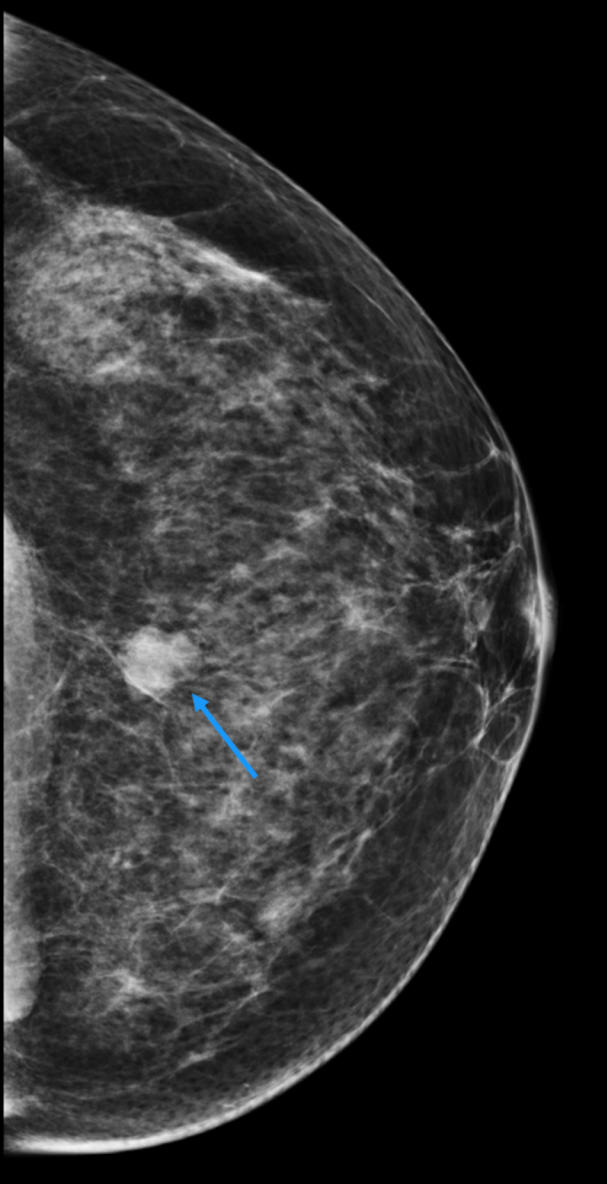


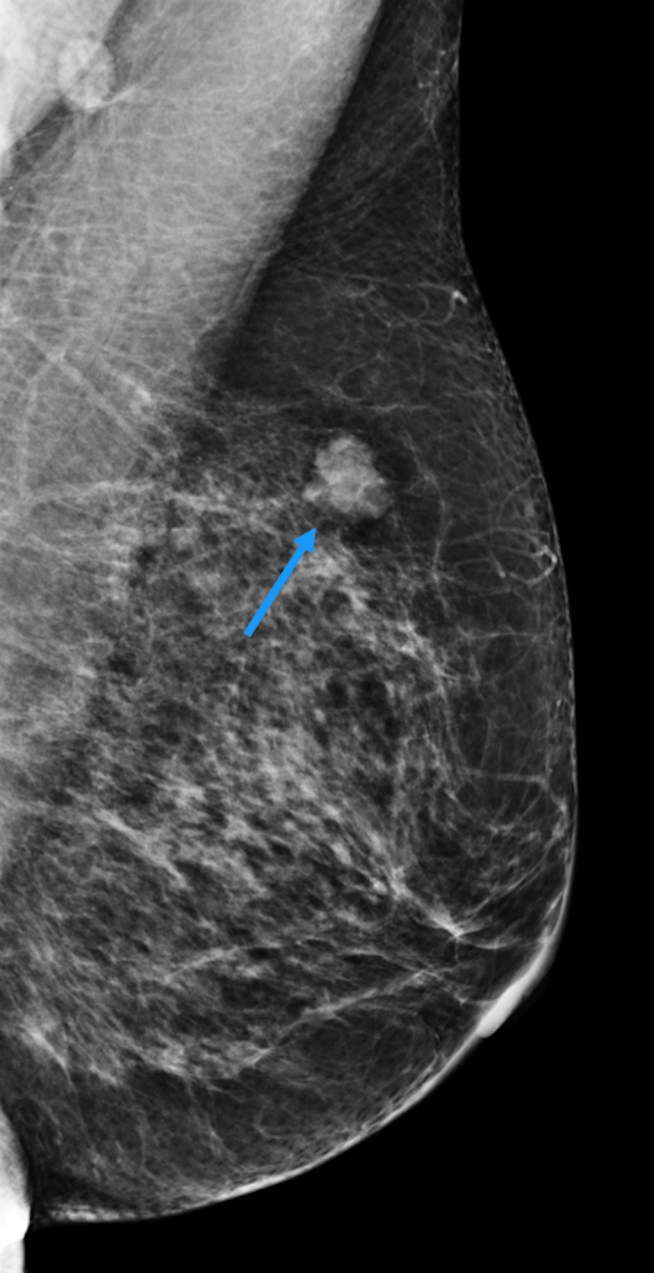


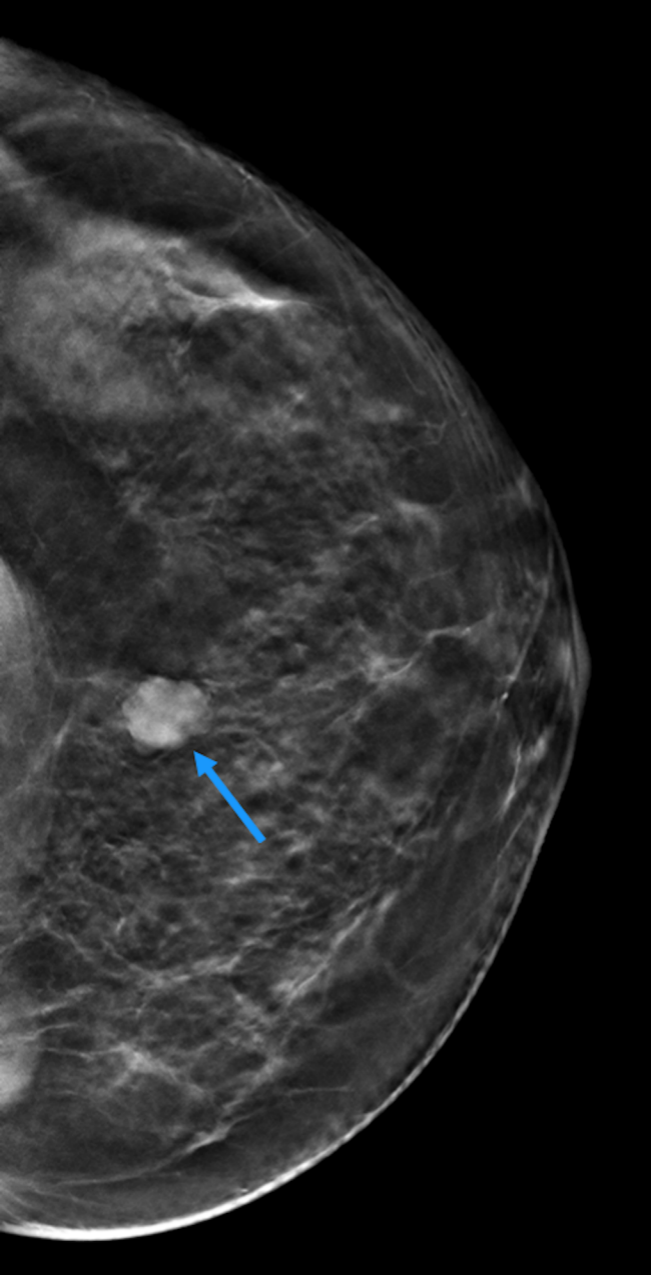




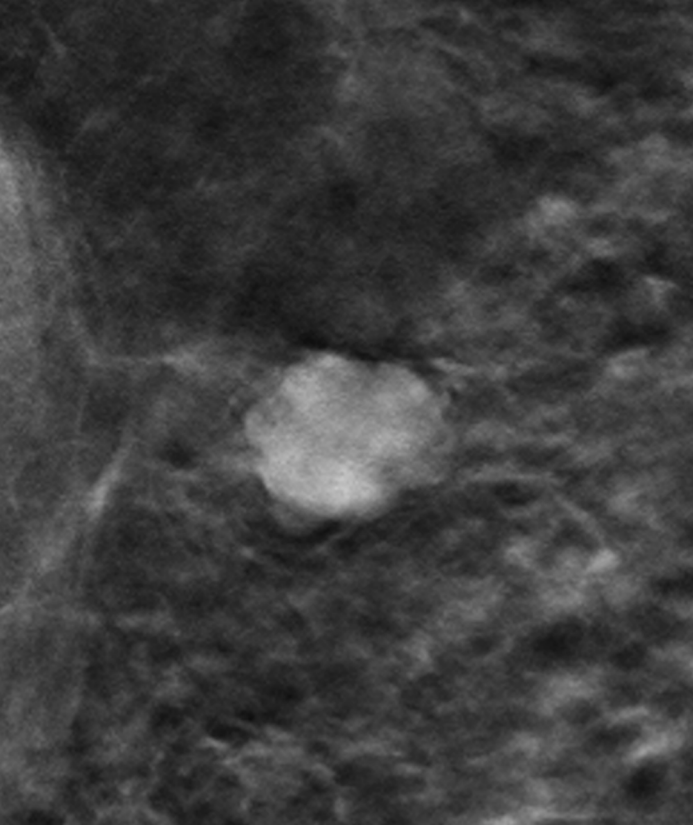


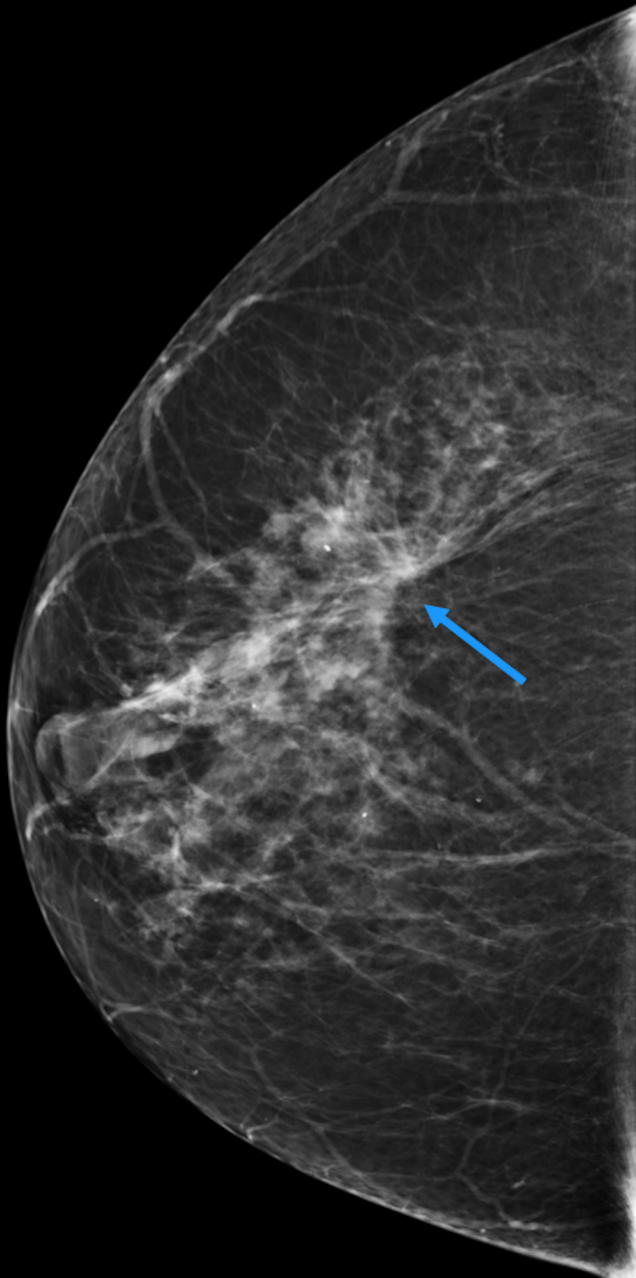


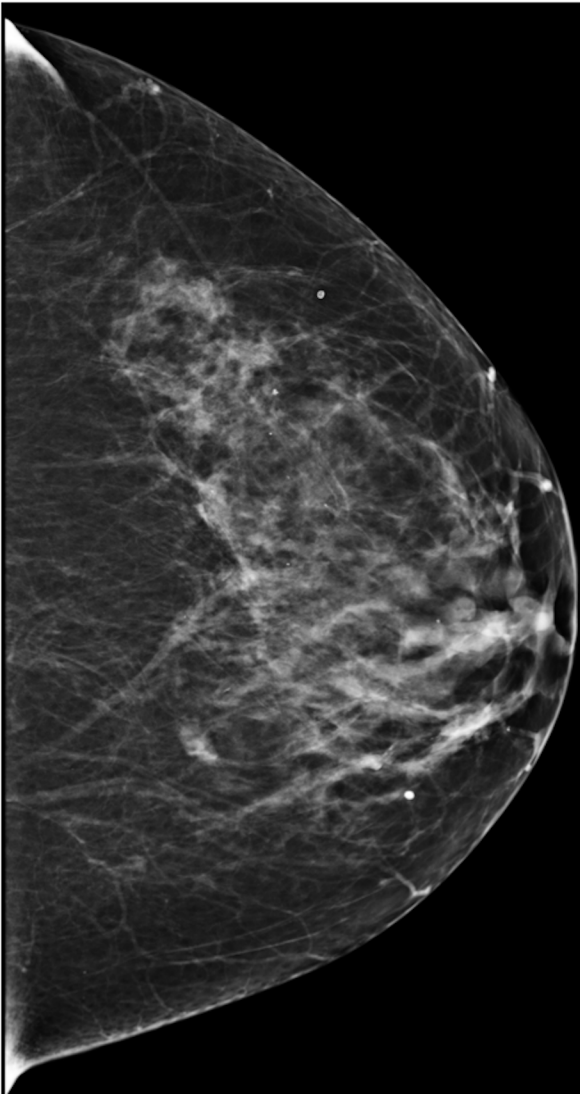


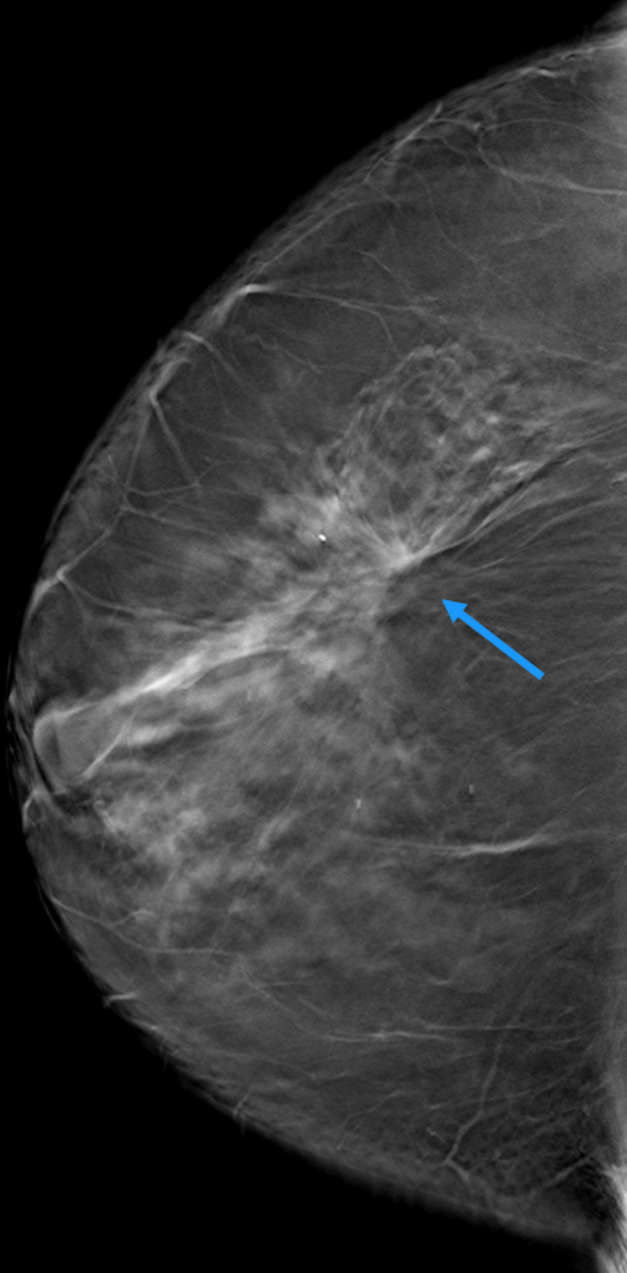


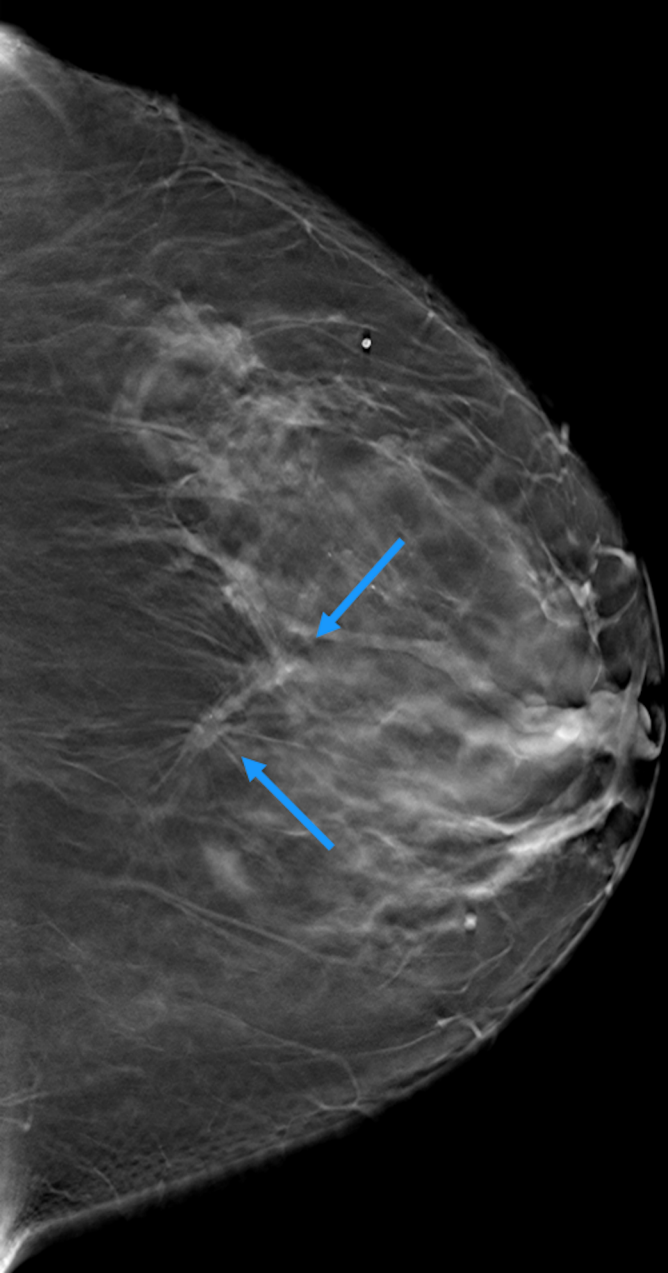


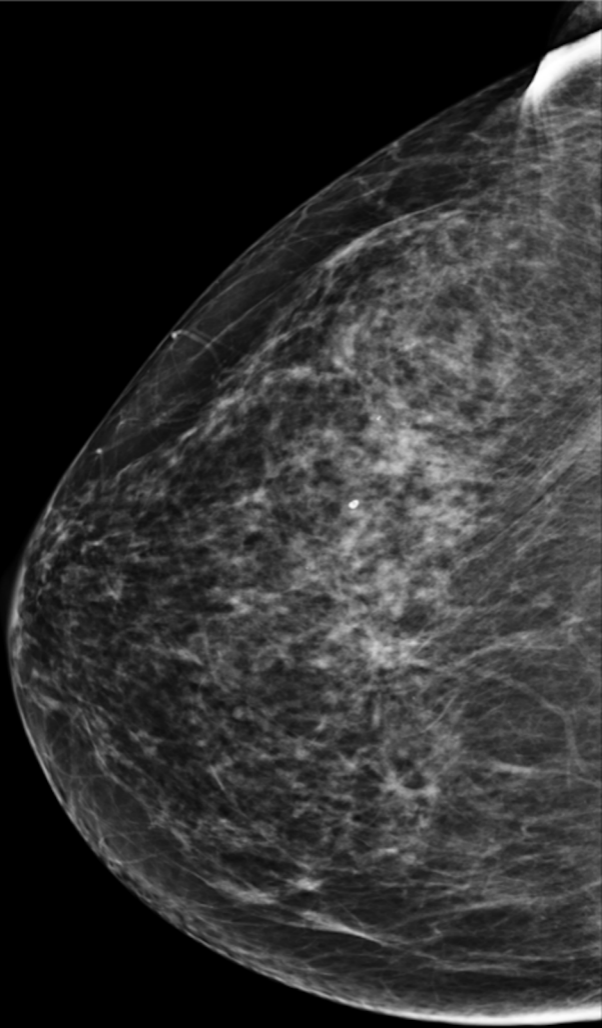


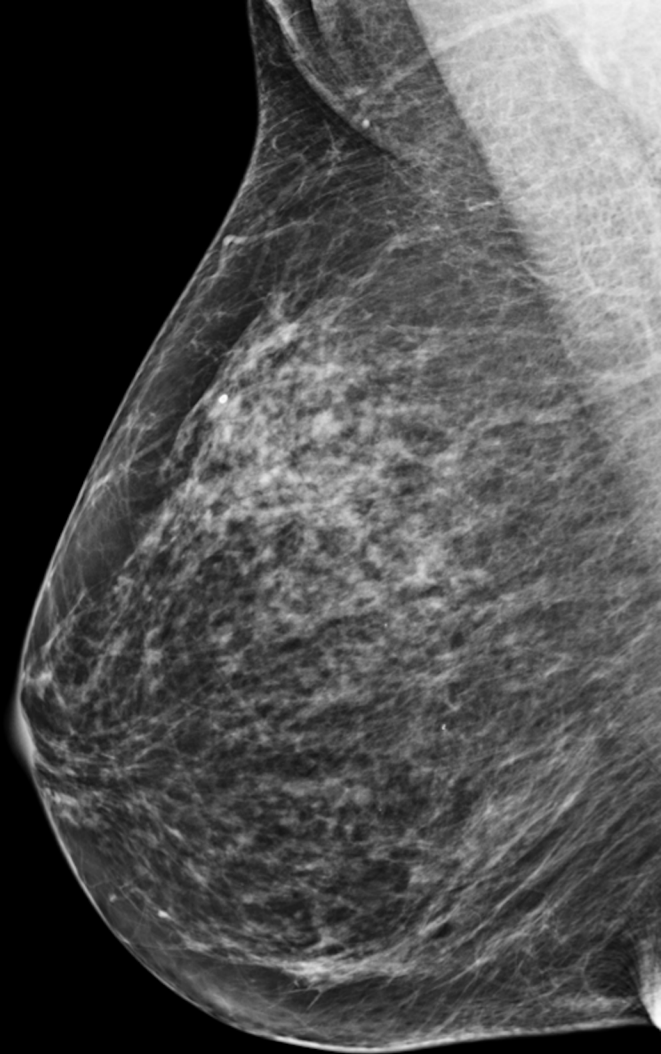


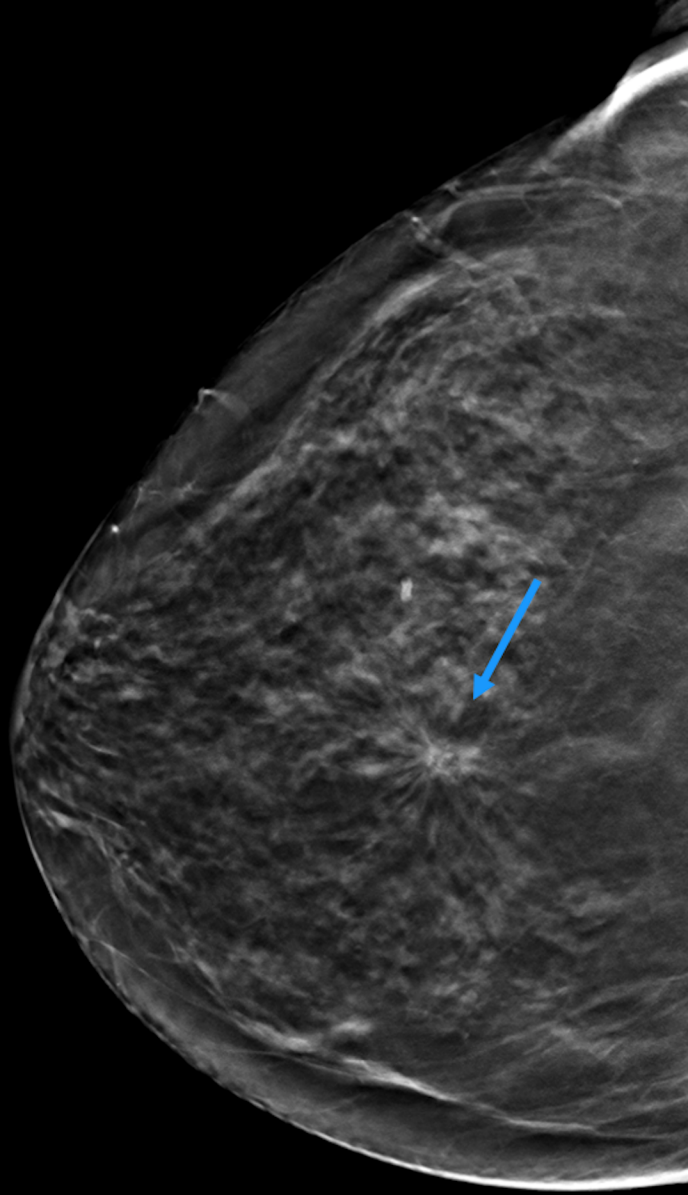




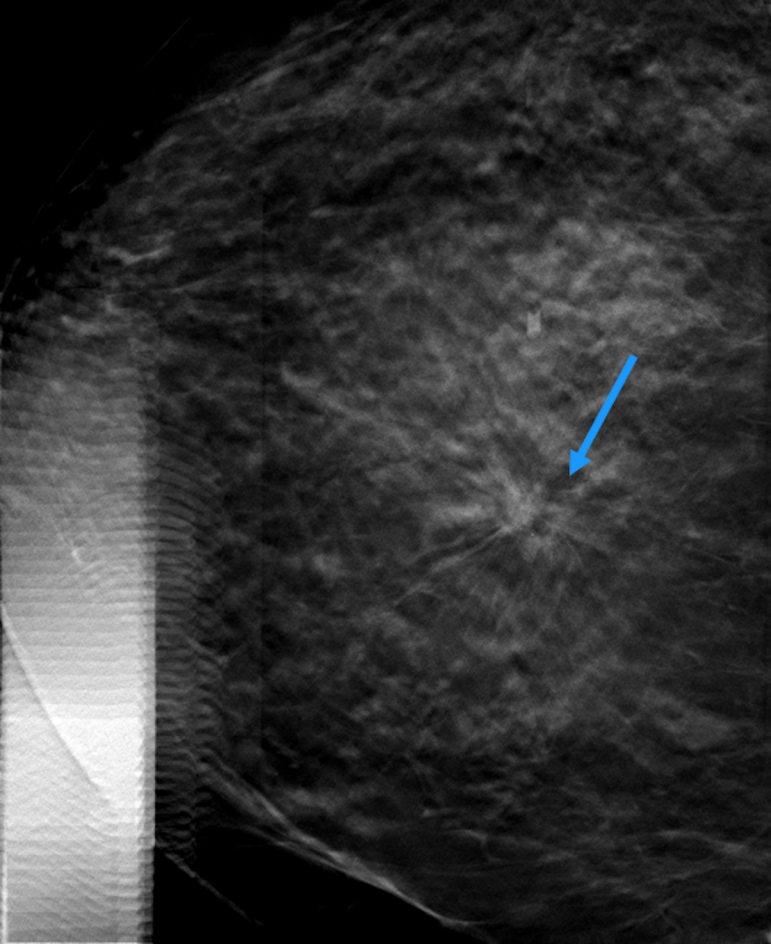












Origin	Design	Modalities	Equipment	Population	DM	DM + DBT *	Increase in CDR due to DBT	Multiplying factor	Reference (year)
Europe	Prospective Single center	DM 2 views vs. DM + DBT 2 views	Hologic	12631	7.1 ‰	9.4 ‰	2.3 ‰	1.31	Skaane et al. (2013) [8]
Europe	Prospective Single center	DM 2 views vs. DM + DBT 2 views	Hologic	7293	5.3 ‰	8.1 ‰	2.8 ‰	1.51	Ciatto et al. (2013) [9]
Europe	Prospective Single center	DM 2 views vs. DM + DBT 2 views	Hologic	9672	6.1 ‰	8.5 ‰	2.4 ‰	1.28	Bernardi et al. (2016) [10]
Europe	Prospective Single center	DM 2 views vs. DBT 1 MLO view*	Siemens	14581	6.5 ‰	8.7 ‰	2.2 ‰	1.34	Zackrisson et al. (2019) [12]*
Europe	Prospective Multicenter Randomized	DM 2 views vs. SM + DBT 2 views	GE Healthcare	14369 (DM) 14380 (SM + DBT)	6.1 ‰	6.6 ‰	0.5 ‰	1.08	Hofvind et al. (2019) [11]
Europe	Retrospective Single center	DM 2 views vs. SM + DBT 2 views	Hologic	29360 (DM) 34071 (SM +DBT)	5.2 ‰	9.2 ‰	4 ‰	1.77	Caumo et al. (2018) [13]
USA	Retrospective Multicenter	DM 2 views vs. DM + DBT 2 views	Hologic	181187 (DM) 173663 (DM+DBT)	2.9 ‰	4.2 ‰	1.3 ‰	1.41	Friedewald et al. (2014) [14]
USA	Retrospective Multicenter	DM 2 views vs. DM + DBT 2 views	Hologic	142883 (DM) 55998 (DM+DBT)	4.4 ‰	5.9 ‰	1.5 ‰	1.45	Conant et al. (2016) [15]

**Note .\_. DM: Digital mammography; DBT: Digital breast tomosynthesis, SM: Synthetic mammography; MLO: mediolateral oblique; Vs.: versus.**

\*Except for Zackrisson's study (DBT stand-alone)

Origin	Design	Modalities	Equipment	Population (n)	RR DM	RR DBT	Decrease in RR due to DBT	Multiplying factor	Reference (year)
Europe	Prospective Single center	DM 2 views vs. DM + DBT 2 views	Hologic	12631	10.3 %	8.5 %	1.8 %	0.83	Skaane et al. (2013) [8]
Europe	Prospective Single center	DM 2 views vs. DM + DBT 2 views	Hologic	7293	4.5 %	3.5 %	1 %	0.77	Ciatto et al. (2013) [9]
Europe	Prospective Single center	DM 2 views vs. DM + DBT 2 views	Hologic	9672	4.9 %	4.4 %	0.5 %	0.9	Bernardi et al. (2016) [10]
Europe	Prospective Single center	DM 2 views vs. DBT 1 MLO view	Siemens	14581	2.5%	3.6%	- 1.1%	1.44	Zackrisson et al. (2019) [12]
Europe	Prospective Multicenter Randomized	DM 2 views vs. SM + DBT 2 views	GE Healthcare	14369 (DM) 14380 (SM +DBT)	4%	3.1%	0.9%	0.78	Hofvind et al. (2019) [11]
Europe	Retrospective Single center	DM 2 views vs. SM + DBT 2 views	Hologic	166666 (DM) 14423 (SM +DBT)	4.2%	4%	0.2%	0.95	Caumo et al. (2018) [13]
USA	Retrospective Multicenter	DM 2 views vs. DM + DBT 2 views	Hologic	181187 (DM) 173663(DM+DBT )	10.7 %	9.1 %	1.6 %	0.85	Friedewald et al. (2014) [14]
USA	Retrospective Multicenter	DM 2 views vs. DM + DBT 2 views	Hologic	142883 (DM) 55998 (DM+DBT)	10.4 %	8.7 %	1.7 %	0.84	Conant et al. (2016) [15]

**Note.-.** DM: Digital mammography; DBT: Digital breast tomosynthesis; SM: Synthetic mammography; MLO: mediolateral oblique; vs: versus.

Number of patients	Type of lesions	Prevalence BC	Se AV	Se DBT	<i>P</i> value	Sp AV	Sp DBT	<i>P</i> value	Reference (year)
288	Consecutive abnormalities in a BC population screening Microcalcifications excluded	55/288	90.9%	96.4%	NS	42.2%	56.6%	<0.001	Heywang et al. (2017) [49]
238	Consecutive abnormalities in a BC population screening Microcalcifications excluded	35/238	86%	90%	NS	64%	59%	<0.001	Whelehan et al. (2017) [50]
131	Abnormalities seen in DM	8/131	100%	88-100%	NS	94%	89-94%	N.S.	Brandt et al. (2013) [51]
52	Consecutive abnormalities in a BC population screening Microcalcifications excluded	9/52	100%	100%	NS	94%	100%	N.S.	Tagliafico et al. (2012) [52]

**Note. -.** BC: Breast cancer; DBT: Digital breast tomosynthesis; DM: Digital mammography; Se: Sensitivity; AV: Additional Views; NS: Non Significant; Sp: Specificity