

# Utility of 18F-FDG PET with a Semi-Quantitative Index in the Detection of Sarcomatous Transformation in Patients with Neurofibromatosis Type 1

Patrick Combemale, Laurence Valeyrie-Allanore, Francesco Giammarile, Stéphane Pinson, Bernard Guillot, Denis Mariano-Goulart, Pierre Wolkenstein, Jean Blay, Thomas Mognetti

► **To cite this version:**

Patrick Combemale, Laurence Valeyrie-Allanore, Francesco Giammarile, Stéphane Pinson, Bernard Guillot, et al.. Utility of 18F-FDG PET with a Semi-Quantitative Index in the Detection of Sarcomatous Transformation in Patients with Neurofibromatosis Type 1. PLoS ONE, Public Library of Science, 2014, 9 (2), pp.e85954. hal-02547621

**HAL Id: hal-02547621**

**<https://hal.umontpellier.fr/hal-02547621>**

Submitted on 20 Apr 2020

**HAL** is a multi-disciplinary open access archive for the deposit and dissemination of scientific research documents, whether they are published or not. The documents may come from teaching and research institutions in France or abroad, or from public or private research centers.

L'archive ouverte pluridisciplinaire **HAL**, est destinée au dépôt et à la diffusion de documents scientifiques de niveau recherche, publiés ou non, émanant des établissements d'enseignement et de recherche français ou étrangers, des laboratoires publics ou privés.

# Utility of 18F-FDG PET with a Semi-Quantitative Index in the Detection of Sarcomatous Transformation in Patients with Neurofibromatosis Type 1

Patrick Combemale<sup>1\*</sup>, Laurence Valeyrie-Allanore<sup>2</sup>, Francesco Giammarile<sup>3</sup>, Stephane Pinson<sup>1</sup>, Bernard Guillot<sup>4</sup>, Denis Mariano Goulart<sup>5</sup>, Pierre Wolkenstein<sup>2</sup>, Jean Yves Blay<sup>1,6</sup>, Thomas Mognetti<sup>3</sup>

**1** Rhône-Alpes multidisciplinary Center for the treatment of Neurofibromatosis type 1, Léon Bérard Comprehensive Cancer Center, Lyon, France, **2** National reference center for neurofibromatosis type 1, Department of Dermatology, Henri Mondor Hospital, UPEC, Créteil, France, **3** Department of Nuclear Medicine, Léon Bérard Comprehensive Cancer Center, Lyon, France, **4** Languedoc multidisciplinary Center for the treatment of Neurofibromatosis type 1, Saint Eloi University Hospital, Montpellier, France, **5** Department of Nuclear Medicine, Saint Eloi University Hospital, Montpellier, France, **6** National reference center for sarcoma, Léon Bérard Comprehensive Cancer Center, Lyon, France

## Abstract

**Background:** Malignant peripheral nerve sheath tumors (MPNSTs) are a serious complications of neurofibromatosis type 1 associated with poor prognosis and deeper lesions can be difficult to diagnose. 18-FDG PET improves the detection of malignancies. However, the criteria for malignancy, notably the SUVmax threshold, are not standardized. Therefore, the aim of the study was to evaluate a semi-quantitative index for the reproducible detection of MPNST with FDG PET.

**Methods:** It is a multicenter retrospective study conducted between 2000 to 2012. All patients with NF1 referred for suspected MPNST underwent PET. Since SUVmax was not available until 2004 in our centers, we had to settle for the semi-quantitative method used at that time, the uptake ratio between the tumor and the normal liver (T/L ratio) with 1.5 as the cut-off for malignancy. When dedicated PET with SUVmax became available, the semi-quantitative analysis of PET images remained, along with SUVmax.

**Results:** 113 patients with 145 tumors were included. PET assessment revealed 65 suspected lesions with T/L >1.5 and among these, 40 were MPNSTs. 80 tumors were classified as non-suspicious, and 79 were benign. The 1.5 T/L cut-off had a negative predictive value (NPV) of 98,8% and a positive predictive value of 61,5%. The positive likelihood ratio (LR) was 4,059, the negative LR was 0,032 with 97% sensitivity and 76% specificity.

**Conclusions:** This study, which is among the largest published, confirms the utility of PET for detecting NF1-associated MPNSTs. A semi-quantitative index, the T/L ratio with a cut-off of 1.5, allowed sensitive and specific differentiation of malignant from benign tumors better than SUVmax. When T/L was <1.5, MPNSTs were ruled out with 98,8% NPV. When T/L was >1.5, there was a strong suspicion of malignancy. This semi-quantitative analytical method is as simple as SUVmax, but is more sensitive, more reproducible and non-user-dependent.

**Citation:** Combemale P, Valeyrie-Allanore L, Giammarile F, Pinson S, Guillot B, et al. (2014) Utility of 18F-FDG PET with a Semi-Quantitative Index in the Detection of Sarcomatous Transformation in Patients with Neurofibromatosis Type 1. PLoS ONE 9(2): e85954. doi:10.1371/journal.pone.0085954

**Editor:** Aldo Scarpa, University of Verona, Italy

**Received:** August 27, 2013; **Accepted:** December 4, 2013; **Published:** February 6, 2014

**Copyright:** © 2014 Combemale et al. This is an open-access article distributed under the terms of the Creative Commons Attribution License, which permits unrestricted use, distribution, and reproduction in any medium, provided the original author and source are credited.

**Funding:** The authors have no support or funding to report.

**Competing Interests:** The authors have declared that no competing interests exist.

\* E-mail: patrick.combemale@lyon.unicancer.fr

## Introduction

Neurofibromatosis type 1 (NF1) is one of the most common autosomal dominant genetic disorders, with an incidence of 1/2500 live births [1]. One of its most serious complications is the development of malignant peripheral nerve sheath tumors (MPNST), which are also known as neurofibrosarcomas. The estimated risk of developing MPNST is 1.6/1000 NF1 cases annually and 8 to 13% across a lifetime [2]. MPNST is one of the most frequent causes of death in NF1 patients, together with brain cancer and vascular disease [3]. Late diagnosis of MPNST is associated with poor prognosis [4]. Surgical biopsy or excision is recommended for patients with superficial involvement. For those

with deeper lesions, the surgical approach is sometimes difficult, as the suspected tumor is embedded among other non-malignant neurofibroma masses and is not easily recognizable. Therefore, techniques that allow non-invasive exploration of the lesion can justify and/or guide surgery or micro-biopsy. The current standard imaging modality is magnetic resonance imaging (MRI), which has limited specificity and sensitivity in sarcoma. Over the past few years, tumor evaluation by <sup>18</sup>F-FDG positron emission tomography (FDG PET/CT) has significantly improved the detection and monitoring of malignancies, including soft tissue sarcomas. Elevated SUV<sub>max</sub> values are significantly correlated with malignancy [5]; however, the use of SUV<sub>max</sub> as a gold standard is controversial because the threshold for malignancy is not

standardized and significant technical variations have been observed among different medical teams and even among patients [6–8].

Therefore, the aim of the present study was to test the value of another index, the T/L SUV<sub>max</sub> ratio, and its reproducibility for the detection of MPNST with PET/CT [9,10].

**Materials and Methods**

**Study population**

The study population was composed of all patients referred to four NF1 reference centers (Rhône-Alpes, Languedoc Roussillon, West of France and Paris) with suspected malignant transformation. A total of 113 patients (63 men, 50 women, ratio 1.26) were retrospectively included. The median age was 31.3±17.1 years (range 2–77 years). Diagnosis was made using the National Institutes of Health (NIH) criteria [11]. NF1 was confirmed when patients met two or more of the seven criteria described by the NIH (Table 1).

This study includes 38 patients from a preliminary publication in 2007 [12].

**Study design**

This retrospective study was conducted between October 2000 and July 2012. All consecutive patients with one or more of the following criteria for suspicion of malignant involvement [13] were eligible for the study: presence of a growing and/or cystic mass (neurofibroma or plexiform NF) with or without pain, severe prolonged pain unresponsive to standard treatment, occurrence or aggravation of neurological symptoms (neurological pain, sensory-motor deficit, dysphonia, dysphagia), general physical deterioration, standard radiological results (osteolysis), and imaging-based evidence of malignancy (by MRI, CT or ultrasound). The study was performed according to French laws at the time of the initiation of the study and followed the principles laid down in the Declaration of Helsinki. Oral consent was obtained after a complete explanation by the patients or legal representatives for minors, and it was reported in the patient’s medical record. Formal approval as a written consent was not specifically needed, as it was waived by the IRB of the institution (Centre Leon Berard), which approved this retrospective study.

**18F-FDG PET/CT**

All referred patients underwent FDG-PET because FDG was indicated for tumor detection, although not specifically for MPNST detection.

Dedicated PET/CTs were not commonplace in 2000 when our first patients underwent imaging. Coincidence Detection Emission

Tomography (CDET) was more widely available. Later, PET equipment evolved and we collected PET studies performed on a variety of cameras: a Marconi Irix (a CDET camera) until 2004, and then a Philips Gemini Dual, a Philips Gemini GXL, a Philips Gemini TF16 PET-CT, and a Siemens Biograph 4. Imaging procedures were very consistent among centers: patients were at rest for at least six hours prior to examination, plasma glucose levels were measured before scintigraphy, and images were acquired 60 minutes after injection of 200–500 MBq <sup>18</sup>F-FDG (IBA, France). Uptake of the tracer was assessed on axial, coronal and sagittal images.

Since SUV<sub>max</sub> cannot be measured on CDET cameras (because they do not correct attenuation), the nuclear medicine physicians had to use a semi-quantitative method, the uptake ratio between the tumor and the normal liver (T/L ratio) and a T/L ratio of 1.5 as the cut-off for malignancy. There was little alternative option for another uptake reference, hence the liver reference. It appears that they initially set the T/L ratio SUV<sub>max</sub> cut-off for risk of malignancy at 1, as described in the literature [14]. Then, as the number of false positives was high, with serious consequences for patients (systematic use of surgical resection or biopsy), it became obvious the threshold had to be revised and they raised it to 1.5. The rationale for this is not known but they consistently continued to use semi-quantitative analysis of PET images along with SUV<sub>max</sub> when imaging was performed on a dedicated PET.

**Patient management and follow-up assessment**

Thereafter, only tumors with T/L SUV<sub>max</sub> ≥1.5 were considered suspicious, and such patients were referred for surgery or biopsy. In contrast, patients with non-suspicious lesions (T/L SUV<sub>max</sub> <1.5) were assigned to clinical monitoring only, possibly including PET/CT, with visits every three months for at least 12 months. Surgical resections were performed in some cases of major functional impairment, multidisciplinary team recommendation, or at the patient’s request. At each investigating center, pathological material was reviewed by the same pathologist with expertise in sarcoma. Immunological analysis was performed using S100 protein, anti-CD34, anti-Ki67, and anti-claudin 1 antibodies. Tumors were graded according to the criteria established by the French Federation of Comprehensive Cancer Centers (FNCLCC).

**Statistical analysis**

PET/CT assessment and the standard procedure (surgical biopsy and clinical monitoring) were compared for sensitivity, specificity, positive and negative predictive values (PPV and NPV), and positive and negative likelihood ratios (PLR and NLR). The distribution of T/L ratios between benign and malignant tumors

**Table 1.** Consensus criteria for the diagnosis of neurofibromatosis type 1.

NIH criteria for the diagnosis of neurofibromatosis type 1	
1	Six or more cafe-au-lait skin macules >5 mm in prepubertal individuals and >15 mm in postpubertal individuals
2	Two or more neurofibromas of any type or one plexiform neurofibroma
3	Axillary or inguinal freckling
4	Two or more Lisch nodules
5	Optic glioma
6	Bone lesion with sphenoid dysplasia or thinning of the long bone cortex with or without pseudarthrosis
7	A first-degree relative (parent, sibling, or offspring) that meets NIH criteria

doi:10.1371/journal.pone.0085954.t001

was assessed using a non-parametric test (Mann-Whitney test). Only p-values <0.05 were considered statistically significant. All statistical analyses were performed with SPSS v.17 (IBM).

**Results**

A total of 113 patients with 145 lesions were included in the study (Table 2). None of the patients had a previous history of MPNST.

Symptoms for inclusion were pain (n=60, 41%), pain associated with tumor growth (n=40, 28%), pain with neurological deficit (n=12, 8.3%), asymptomatic growth of a neurofibroma mass (n=22, 15%), functional impairment such as cough or vascular compression (n=3, 2%), or asymptomatic tumor discovered while evaluating a symptomatic tumor (n=9, 6.2%).

Among the 145 tumors, 80 had a T/L ratio  $SUV_{max} < 1.5$ . Of these, 79 were confirmed as benign neurofibromas (by either pathology (n=55) or follow-up assessment from 3 to 10 years, (n=24)) and one was malignant, corresponding to a 98.8% NPV.

Concerning the 65 other lesions (with a T/L ratio  $\geq 1.5$ ), 40 were identified as MPNSTs and 25 as benign neurofibromas, corresponding to a 61.5% PPV. The PLR (equal to sensitivity/1-specificity) was 4,059 (1/[1-0.75]; 95% CI: 2,874-5,731), and the NLR (equal to 1-sensitivity/specificity) was 0.032 (CI 95%: 0,005-0,223) with 97% sensitivity and 76% specificity (figure 1). Threshold defined using a ROC curve for the specific sensibility, specificity values is 1.48.

Incidentally, we did not find any significant correlation between malignancy and absolute tumor  $SUV_{max}$  among the subset of patients studied with dedicated PET/CT.

**Discussion**

MPNSTs represent about 10% of all soft tissue sarcomas, and are associated with NF1 in 32 to 60% of cases [15,16]. Moreover, they are one of the major causes of death in NF1 patients. The

relative risk of MPNST in these patients is high (RR: 113) and is increased in patients receiving radiation therapy [17]. These tumors usually occur earlier in NF1 than in the general population (30 to 32.5 years vs. 60 years) [4]. Tumors are more frequently diagnosed in patients with deep NF involvement. In a series of 120 MPNSTs, Ducatman *et al.* found that 81% of cases had a history of neurofibroma [18], and particularly internal plexiform neurofibroma, with a relative risk of 20 for sarcoma [19]. The most common sites of MPNSTs are the roots of the limbs, the extremities and the retroperitoneal space [20], as observed in our study. Clinical symptoms suggestive of malignant transformation include neurological deficit, rapid enlargement of pre-existing tumors and increasing pain that is unresponsive to symptomatic treatment [13]. However, tumor enlargement is the indicator with the highest PPV (92%) and NPV (95%) values. Nevertheless, these symptoms may not be specific to malignant disease [20], as confirmed by the present study. In fact, among the 40 patients with the most specific association, pain and tumor swelling, malignant transformation was observed in 43% of cases. In comparison, presence of pain alone was associated with MPNST in 28% of cases. Nevertheless, the combination of pain and tumor enlargement remains significantly predictive of MPNST in 17/40 of our cases (43%), and should continue to be of interest in clinical practice.

MPNSTs associated with NF1 are of higher histological grade than those in the general population [21] and display poorer prognosis and earlier metastatic spread. The survival rate at five years is also lower (21% vs. 35%) compared with patients with sarcoma in the general population (68%) [21-23]. This poor prognosis could be partly explained by delayed diagnosis. Early diagnosis is essential in order to improve outcomes [17]. This can be achieved by histological analysis, which might be relatively easy for superficial tumors, but is more difficult in patients with deep involvement. Surgical access may be difficult or even risky when the tumor is deeply located (i.e., in the mediastinum or the pelvis). In this context, the estimated risk of generating uninformative results is approximately 5% [24].

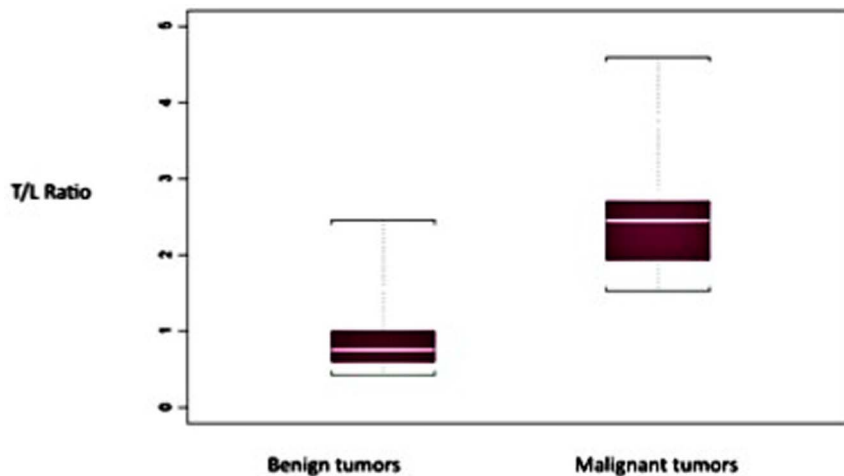
CT and MRI images can be useful to detect MPNSTs and many criteria have been proposed for these methods [25]. De Schepper *et al.* suggested that tumor diameter >66 mm, no abnormal signal intensity on T2-weighted images and the presence of a heterogeneous signal intensity on T1-weighted images, combined with neurovascular deficit and >50% tissue necrosis, are suggestive of malignant transformation [26]. Early contrast enhancement (<6 sec.) had 91% sensitivity and 72% specificity. More recently, Van Herendael *et al.* reported that intermuscular distribution, location on the course of a large nerve, nodular morphology, and overall non-homogeneity on T1- and T2-weighted images and on T1-weighted images after gadolinium contrast injection were all factors significantly associated with malignancy (p<0.05) [27]. However, the target sign (the central area of low signal intensity surrounded by a rim of high signal intensity) is not specific [28]. Therefore, although it provides some interesting information, MRI is not sensitive enough (50-80%) for the diagnosis of malignant tumors [29]. Moreover, the presence of multiple tumors on a given site makes MRI assessment even more difficult.

PET/CT can be used to assess the whole-body volumetric distribution of biological tracer molecules labeled with positron-emitting isotopes. The radiotracer <sup>18</sup>F-FDG has been validated for the measurement of local glucose uptake and is routinely used in the evaluation and follow-up of many tumor types. Thus, <sup>18</sup>F-FDG tissue distribution 60 minutes after injection reflects the rate of glycolysis, and malignant areas can be identified due to their

**Table 2.** Demographic and baseline characteristics of patients.

Variables	n (%)
Sex (n = 113)	
Male	63 (55.8)
Female	50 (44.2)
Lesions (n = 145)	
Lumbar pelvic area	48 (33.1)
Lower limb	35 (24.1)
Cervical and facial area	28 (19.3)
Upper limbs	19 (13.1)
Thorax	12 (8.3)
Missing	3 (2.1)
Symptoms (n = 146)	
Pain	60 (41.1)
Pain and tumor growth	40 (27.4)
Pain and neurological deficit	12 (8.2)
Asymptomatic growth	22 (15.1)
Functional impairment	3 (2.1)
Asymptomatic	9 (6.2)

doi:10.1371/journal.pone.0085954.t002



**Figure 1. Mean T/L ratio in benign and malignant lesions.**

doi:10.1371/journal.pone.0085954.g001

increased glycolytic activity and over-expression of glucose transporters [30–32].

SUV and its derived parameters (e.g.  $SUV_{max}$ ) are quantitative rather than semi-quantitative measurements.  $SUV_{max}$  determination involves measuring the absolute FDG concentration through PET, which is adjusted for weight and injected activity. SUV is a unitless value and can be calculated using the following equation:  $SUV = PET \text{ tissue concentration (MBq/kg)} / (\text{injected activity (MBq)} / \text{body weight (kg)})$ .

Analysis of PET-CT images is mostly based on simple visual analysis and  $SUV_{max}$ . Even though qualitative visual analyses are fast and reliable, the results are highly operator-dependent in borderline situations. Since many non-cancerous lesions have the potential to accumulate glucose,  $SUV_{max}$  does not constitute definitive proof of malignancy. Moreover, it is well known that  $SUV_{max}$  presents limitations and can be influenced by many individual (e.g., time between injection and PET, blood glucose concentration, body composition, kidney elimination) and physical (e.g., reconstruction algorithms, resolution recovery, spillover, image noise) variables. Due to these potentially complicating factors, which cannot be measured or normalized,  $SUV_{max}$  has often been criticized based on limited reproducibility [7,8,33].

PET/CT assessment has good diagnostic accuracy for many cancers [30–35]. Warbey *et al.* [36] showed that delayed acquisition (four hours after FDG administration) is beneficial when assessment is based on  $SUV_{max}$ , since FDG uptake continues to rise until that point. However, because of the 110 min half-life of this costly tracer and the pressure for patient throughput, a large majority of PET/CT centers routinely acquire images at one hour.

A meta-analysis of patients with soft tissue and bone sarcomas published in 2004 [6] reported 91% sensitivity, 85% specificity and 88% efficacy using the  $SUV_{max}$  based approach. Moreover, PET/CT can predict the histological grade of soft tissue sarcomas as a function of  $SUV_{max}$ . Several studies have explored the role of this method in the diagnosis of MPNSTs and have confirmed its interest for the detection of MPNST [38–42]. However, the very heterogeneity of their results makes it difficult to draw a single conclusion. For example, Cardona *et al.* [43] reported 100% sensitivity and 83% specificity in a population of 25 patients (of whom five had NF1) with an absolute  $SUV_{max}$  cut-off value for malignancy of 1.8. But other recent studies have demonstrated that an absolute  $SUV_{max} > 3$  is associated with poor prognosis and

is correlated with Ki67 levels [41,42,44]; Tsai [45] set the  $SUV_{max}$  malignancy threshold at 4. Karabatsou also reached a 4  $SUV_{max}$  cut-off, but this was in a very small set of 9 patients [46]. In 40 patients, including 16 MPNST, Benz [38], set the  $SUV_{max}$  cut-off at 6.1, with 94% sensitivity and 91% specificity. Finally, several works by Ferner's group [47,48] confirmed the diagnostic efficacy of PET/CT in the detection of MPNST but also the high variability of the  $SUV_{max}$  cut-off values proposed to distinguish between MPNST and benign tumors. In 2000, the authors set the malignancy threshold at 2.5 while noticing one false negative among 28 patients with 7 MPNST [47]. Then, in 2008, in a series of 105 patients (including 116 tumors, 29 MPNSTs), sensitivity in diagnosing NF1-associated MPNST was 89% and specificity 95% [48]. Their results showed that a high  $SUV_{max}$  level is significantly correlated with malignancy, with an absolute  $SUV_{max}$  cut-off of 3.5, but that there were no malignant tumors when the  $SUV_{max}$  was below  $< 2.5$ . Moreover, there is a wide overlap between these 2 values, which should be reviewed clinically. These results were confirmed by Warbey [36] one year later, but the same group obtained similar results (97% sensitivity and 87% specificity). The authors found a cutoff of malignancy of  $SUV_{max} > 2.35$  (60% specificity) with early imaging at 90 min and at 3.1 for delayed imaging at 240 min (100% sensitivity, 76.6% specificity). However, they concluded that using a cut-off of 3.5 on delayed imaging had the maximal sensitivity for malignancy and showed that there is a correlation between mean maximum  $SUV_{max}$  and tumor grade [36].

Nevertheless, false positives were also reported, and the method proved unable to accurately distinguish between malignant and benign lesions [48].

The heterogeneity of the proposed  $SUV_{max}$  cut-offs for the detection of MPNSTs suggests that absolute  $SUV_{max}$  based analysis has poor reliability. This is relevant given its known limitations regarding reproducibility [7,8,33]. In addition, different groups reported contradictory results, making comparisons difficult.

Therefore, other authors have performed semi-quantitative analysis, considering not  $SUV_{max}$  but a ratio between tumor and safe tissue  $SUV_{max}$  [31]. Miyamoto *et al.* [37] showed that semi-quantitative analysis was effective for the diagnosis of orbital tumors, with significantly higher tumor/controlateral normal tissue values in malignant than in benign lesions. Although little

used, semi-quantitative analysis has been suggested by various authors, with the most used reference being the liver [49]. Authors have compared  $SUV_{max}$  and tumor/liver (T/L) ratios in non-secreting adrenal tumours. In addition to a good correlation, they showed that a T/L ratio with a threshold of 1.8 could determine malignancy with a 100% PPV and a 91% NPV [9,10]. This threshold was identical in two different teams, suggesting good reproducibility among users [9,10]. In contrast, Mantaka used the T/L ratio  $SUV_{max}$  for detecting liver's tumors, and found a cut-off for malignancy of 1 [14].

In our department, the initial threshold was empirically set at 1, but apparently resulted in a number of false positives, and was therefore empirically raised to 1.5, with no more false positives (including retrospectively patients first evaluated with a cut-off for malignancy of 1) [12]. The T/L ratio was significantly higher (2.5) in proved malignancies than in benign samples ( $p < 0.002$ ). However, an elevated absolute  $SUV_{max}$  ( $> 2$ ) was not found to be statistically associated with malignancy.

To our knowledge, ours is the only study on the detection of MPNSTs with PET/CT that is not based only on absolute tumor  $SUV_{max}$  assessment. Our use of the T/L uptake ratio, although somewhat empirical, appears to be reliable, reproducible and less subject to  $SUV_{max}$  variability (possibly because semi-quantitative assessment bypasses some of the factors influencing FDG uptake) [49].

Significantly, this multicenter study demonstrates that this ratio is independent of the medical team and the PET/CT camera. This type of analysis is just as easy to perform and can even be done retrospectively if all DICOM images are archived.

We were able to determine that a 1.5 cut-off provides a 98.8% NPV and 61.5% PPV. Our only false-negative finding could not be explained by low tumor aggressiveness since the patient's tumor was grade 1. Shahid *et al.* also reported a false-negative patient with a grade 3 tumor [50]. Unfortunately, our data did not enable us to identify a correlation between false positivity and dysplasia in plexiform neurofibromas. Such tumors have a higher risk of malignant transformation, but a recent study showed that

plexiform neurofibromas have similar uptake, whether or not they are associated with dysplasia [51]. This point should be examined in future studies.

This retrospective, multicenter study is among the largest to explore the utility of PET/CT in NF1 patients. Our findings show that PET/CT can be used to identify deep MPNSTs. Moreover, we have identified simple, reproducible, non-user-dependent PET/CT criteria for ruling out malignancy, which is essential for the effective use of this technology. We show that a seldom used semi-quantitative analysis, with a T/L ratio cut-off of 1.5, has a NPV of 98.8%, with an acceptable PPV of 61.5%. To our knowledge, no study has provided such promising results based on absolute  $SUV_{max}$  values. These results are a strong argument in favor of this tool. Patients with a T/L ratio  $< 1.5$  can safely be assigned to a simple monitoring strategy, thus avoiding unnecessary risky or mutilating surgery. Patients with a T/L ratio  $\geq 1.5$  require pathologic sampling before surgery is decided upon. However, false positive results may be obtained, and medico-surgical confirmation is required before any potentially detrimental therapeutic decision is made.

Because our method can also be used retrospectively, we encourage other authors to match their existing series against it to confirm the reproducibility of our results.

## Acknowledgments

We would like to thank Pr. Chevrant Breton, from the Department of Dermatology of Pontchaillou University Hospital in Rennes, France, and Pr. Bernard Philippe, from the Department of Dermatology of Reims University Hospital, France.

## Author Contributions

Conceived and designed the experiments: PC TM. Performed the experiments: PC FG TM DMG. Analyzed the data: PC LA BG PW. Contributed reagents/materials/analysis tools: SP JYB. Wrote the paper: PC TM.

## References

- Pinson S, Creange A, Barbarot S, Stalder JF, Chaix Y, et al. (2001) Neurofibromatosis 1: recommendations for management. *Ann Dermatol Vénéréol* 128: 567–575.
- Evans DG, Baser ME, Mc Gaughan J, Sharif S, Howard E, et al. (2002) Malignant peripheral nerve sheath tumours in neurofibromatosis 1. *J Med Genet* 39: 311–314.
- Rasmussen SA, Yang Q, Friedman JM. (2010) Mortality in neurofibromatosis 1: an analysis using U.S. death certificates. *Am J Hum Genet* 68: 1110–1118.
- Doom PF, Molenaar WM, Buter J, Hoekstra HJ. (1995) Malignant peripheral nerve sheath tumors in patients with and without neurofibromatosis. *Eur J Surg Oncol* 21: 78–82.
- Ferner RE, Gutmann DH. (2002) International consensus statement on malignant peripheral nerve sheath tumors in neurofibromatosis. *Cancer Res* 62: 1573–1577.
- Bastiaannet E, Groen H, Jager PL, Cobben DC, van der Graaf WT, et al. (2004) The value of FDG-PET in the detection, grading and response to therapy of soft tissue and bone sarcomas; a systematic review and meta-analysis. *Cancer Treat Rev* 30: 83–101.
- Kumar V, Nath K, Berman CG, Kim J, Tanvetyanon T, et al. (2013) Variance of SUVs for FDG-PET/CT is greater in clinical practice than Under idéal study settings. *Clin Nucl Med* 38: 175–182.
- De Langen AJ, Vincent A, Velasquez LM, Van Tinteren HT, Boellaard R, et al. (2012) Repeatability of 18 F-FDG uptake measurements in tumors: a metaanalysis. *J Nucl Med* 53: 701–708.
- Tessonnier L, Sebag F, Palazzo FF, Colavolpe C, De Micco C, et al. (2008) Does (18)-FDG PET/CT add diagnostic accuracy in incidentally identified non secreting adrenal tumors? *Eur J Nucl Med Mol Imaging* 35: 2018–2025.
- Okada M, Shimono T, Komeya Y, Ando R, Kagawa Y, et al. (2009) Adrenal masses: the value of additional fluorodeoxyglucose-positron emission tomography/computed tomography (FDG-PET/CT) in differentiating between benign and malignant lesion. *Ann Nucl Med* 23: 349–354.
- Neurofibromatosis. Conference statement. (1998) National Institutes of Health Consensus Development Conference. *Arch Neurol* 45: 575–578.
- Bensaid B, Giammarile F, Mognetti T, galoisy-Guilbal L, Pinson S, et al. (2007) Intérêt de la scintigraphie au FDG 18 dans la détection des neurofibrosarcomes au cours de la neurofibromatose de type 1 *Ann Dermatol Vénéréol* 134: 735–742.
- Valeryie-Allanore L, Ismaili N, Bastuji-Garin S, Zeller J, Wechsler J, et al. (2005) Symptoms associated with malignancy of peripheral nerve sheath tumours: a retrospective study of 69 patients with neurofibromatosis 1. *Br J Dermatol* 153: 79–82.
- Mantaka P, Strauss AD, Strauss LG, Mochler M, Goldschmidt H, et al. (1999) Detection of treated liver metastases using fluorine-18-fluorodeoxyglucose (FDG) and positron emission tomography (PET). *Anticancer Res* 19: 4443–4450.
- Wick MR, Swanson PE, Scheithauer BW, Manivel JC. (1987) Malignant peripheral nerve sheath tumor. An immunohistochemical study of 62 cases. *Am J Clin Pathol* 87: 425–433.
- Stucky CC, Johnson KN, Gray RJ, Pockaj BA, Ocal IT et al. (2012) Malignant peripheral Nerve Sheath tumors (MPNST): The Mayo clinic experience. *Ann Surg Oncol* 19: 878–885.
- King AA, Debaun MR, Riccardi VM, Gutmann DH. (2000) Malignant peripheral nerve sheath tumors in neurofibromatosis 1. *Am J Med Genet* 93: 388–392.
- Ducatman BS, Scheithauer BW, Piepgras DG, Reiman HM, Ilstrup DM. (1986) Malignant peripheral nerve sheath tumors. A clinicopathologic study of 120 cases. *Cancer* 57: 2006–2021.
- Tucker T, Wolkenstein P, Revuz J, Zeller J, Friedman JM. (1999) Association between benign and malignant peripheral nerve sheath tumors in NF1. *Neurology* 65: 205–211.
- Ramanathan RC, Thomas JM. (1999) Malignant peripheral nerve sheath tumours associated with von Recklinghausen's neurofibromatosis. *Eur J Surg Oncol* 25: 190–193.

21. Woodruff JM. (1999) Pathology of tumors of the peripheral nerve sheath in type 1 neurofibromatosis. *Am J Med Genet* 89: 23–30.
22. Loree TR, North JH Jr, Werness BA, Nangia R, Mullins AP, et al. (2000) Malignant peripheral nerve sheath tumors of the head and neck: analysis of prognostic factors. *Otolaryngol Head Neck Surg* 122: 667–672.
23. Porter DE, Prasad V, Foster L, Dall GF, Birch R, et al. (2009) Survival in Malignant Peripheral Nerve Sheath Tumours: a comparison between Sporadic and Neurofibromatosis Type 1-Associated Tumours. *Sarcoma* 2009: 756395.
24. Le Pechoux C, Pautier P, Delannes M, Bui BN, Bonichon F, et al. (2006) Clinical practice guidelines: 2006 update of recommendations for the radiotherapeutic management of patients with soft tissue sarcoma (sarcoma of the extremity, uterine sarcoma and retroperitoneal sarcoma. *Cancer Radiother* 10: 185–207.
25. Demas BE, Heelan RT, Lane J, Marcove R, Hajdu S, et al. (1988) Soft-tissue sarcomas of the extremities: comparison of MR and CT in determining the extent of disease. *AJR Am J Roentgenol* 150: 615–620.
26. De Schepper AM, Ramon FA, Degryse HR. (1992) Magnetic resonance imaging of soft tissue tumors. *J Belge Radiol* 75: 286–296.
27. Van Herendael BH, Heyman SR, Vanhoenacker FM, De Temmerman G, Bloem JL, et al. (2006) The value of magnetic resonance imaging in the differentiation between malignant peripheral nerve-sheath tumors and non-neurogenic malignant soft-tissue tumors. *Skeletal Radiol* 35: 745–753.
28. Banks KP. (2005) The target sign: extremity. *Radiology* 234: 899–900.
29. Crim JR, Seeger LL, Yao L, Chandnani V, Eckardt JJ. (1992) Diagnosis of soft-tissue masses with MR imaging: can benign masses be differentiated from malignant ones? *Radiology* 185: 581–586.
30. Knight SB, Delbeke D, Stewart JR, Sandler MP. (1996) Evaluation of pulmonary lesions with FDG-PET. Comparison of findings in patients with and without a history of prior malignancy. *Chest* 109: 982–988.
31. Lowe VJ, Hoffman JM, DeLong DM, Patz EF, Coleman RE. (1994) Semiquantitative and visual analysis of FDG-PET images in pulmonary abnormalities. *J Nucl Med* 35: 1771–1776.
32. Schmidt M, Schmalenbach M, Jungehulsing M, Theissen P, Dietlein M, et al. (2004) 18F-FDG PET for detecting recurrent head and neck cancer, local lymph node involvement and distant metastases. Comparison of qualitative visual and semiquantitative analysis. *Nuklearmedizin* 43: 91–104.
33. Cheng D, Alavi A, Lim E, Werner T, Del Bello CV. (2013) Dynamic changes of FDG Uptake and clearance in normal tissues. *Mol Imaging Biol* 15: 345–352.
34. Frohlich A, Diederichs CG, Staib L, Vogel J, Beger HG, et al. (1999) Detection of liver metastases from pancreatic cancer using FDG PET. *J Nucl Med* 40: 250–255.
35. Hubner KF, Buonocore E, Gould HR, Thie J, Smith GT, et al. (1996) Differentiating benign from malignant lung lesions using “quantitative” parameters of FDG PET images. *Clin Nucl Med* 21: 941–949.
36. Warbey VS, Ferner RE, Dunn JT, Calonje E, O’Doherty MJ. (2009) [18F] FDG PET/CT in the diagnosis of malignant peripheral nerve sheath tumours in neurofibromatosis type-1. *Eur J Nucl Med Mol Imaging* 36: 751–757.
37. Miyamoto J, Tatsuzawa K, Owada K, Kawabe T, Sasjima H, et al. (2008) Usefulness and limitations of Fluorine-18- Fluorodeoxyglucose Positron Emission Tomography for detection of malignancy of orbital tumors. *Neurol Med Chir (Tokyo)* 48: 495–499.
38. Benz MR, Czernin J, Dry SM, Tap WD, Allen-Auerbach MS, et al. (2010) Quantitative F18-fluorodeoxyglucose positron emission tomography accurately characterizes peripheral nerve sheath tumors as malignant or benign. *Cancer* 116: 451–458.
39. Otsuka H, Graham MM, Kubo A, Nishitani H. (2005) FDG-PET/CT findings of sarcomatous transformation in neurofibromatosis: a case report. *Ann Nucl Med* 19: 55–58.
40. Santaella Y, Borrego I, Lopez J, Ortiz MJ, Vazquez R. (2005) 18-FDG-PET in a case of recurrent malignant schwannoma. *Rev Esp Med Nucl* 24: 127–130.
41. Chander S, Westphal SM, Zak IT, Bloom DA, Zingas AP, et al. (2004) Retroperitoneal malignant peripheral nerve sheath tumor: evaluation with serial FDG-PET. *Clin Nucl Med* 29: 415–418.
42. Solomon SB, Semih Dogan A, Nicol TL, Campbell JN, Pomper MG. (2001) Positron emission tomography in the detection and management of sarcomatous transformation in neurofibromatosis. *Clin Nucl Med* 26: 525–528.
43. Cardona S, Schwarzbach M, Hinz U, Dimitrakopoulou-Strauss A, Attigah N, et al. (2003) Evaluation of F18-deoxyglucose positron emission tomography (FDG-PET) to assess the nature of neurogenic tumours. *Eur J Surg Oncol* 29: 536–541.
44. Brenner W, Friedrich RE, Gawad KA, et al. (2006) Prognostic relevance of FDG PET in patients with neurofibromatosis type-1 and malignant peripheral nerve sheath tumours. *Eur J Nucl Med Mol Imaging* 33: 428–432.
45. Tsai LI, Drubach L, Fahey F, Irons M, Voss S, Ulrich NJ. (2012) (18)-Fluorodeoxyglucose positron emission tomography in children with neurofibromatosis type 1 and plexiform neurofibromas: correlation with malignant transformation. *J Neurooncol* 108: 469–475.
46. Karabatsou K, Kiehl TR, Wilson DM, Hendler A, Guha A. (2009) Potential role of (18)- Fluorodeoxyglucose positron emission tomography/computed tomography in differentiating benign neurofibroma from malignant peripheral nerve sheath tumor associated with neurofibromatosis 1. *Neurosurgery* 65: A160–A170.
47. Ferner RE, Lucas JD, O’Doherty MJ, Hughes RA, Smith MA, et al. (2000) Evaluation of (18) fluorodeoxyglucose positron emission tomography ((18) FDG PET) in the detection of malignant peripheral nerve sheath tumours arising from within plexiform neurofibromas in neurofibromatosis 1. *J Neurol Neurosurg Psychiatry* 68: 353–357.
48. Ferner RE, Golding JF, Smith M, Calonje E, Jan W, et al. (2008) (18F) 2-fluoro-2-deoxy-D-glucose positron emission tomography (FDG PET) as a diagnostic tool for neurofibromatosis 1 (NF1) associated malignant peripheral nerve sheath tumours (MPNSTs): a long-term clinical study. *Ann Oncol* 19: 390–394.
49. Laffon E, Adhoue X, de Clermont H, Marthan R. (2011) Is liver stable over time in 18 F-FDG PET imaging. *J Nucl Med Technol* 39: 258–263.
50. Shahid KR, Amrami KK, Esther RJ, Lowe VJ, Spinner RJ. (2011) False-negative fluorine-18 fluorodeoxyglucose positron emission tomography of a malignant peripheral nerve sheath tumor arising from a plexiform neurofibroma in the setting of a neurofibromatosis type 1. *J Surg Orthop Adv* 20: 132–135.
51. Meany H, Dombi E, Reynolds J, Whatley M, Kurwa A, et al. (2013) 18-Fluorodeoxyglucose positron emission tomography (FDG-PET) evaluation of nodular lesions in patients with neurofibromatosis type 1 and plexiform neurofibromas (PN) or malignant peripheral nerve sheath tumors (MPNST). *Pediatr Blood Cancer* 60: 59–64.