



**HAL**  
open science

## Homemade fenestrated stent-graft for thoracic endovascular aortic repair of zone 2 aortic lesions

Ludovic Canaud, Kiyofumi Morishita, Thomas Gandet, Julien Sfeir, Sebastien Bommart, Pierre Alric, Marcello Mandelli

### ► To cite this version:

Ludovic Canaud, Kiyofumi Morishita, Thomas Gandet, Julien Sfeir, Sebastien Bommart, et al.. Homemade fenestrated stent-graft for thoracic endovascular aortic repair of zone 2 aortic lesions. *Journal of Thoracic and Cardiovascular Surgery*, 2018, 155 (2), pp.488 - 493. 10.1016/j.jtcvs.2017.07.045 . hal-01830223

**HAL Id: hal-01830223**

**<https://hal.umontpellier.fr/hal-01830223>**

Submitted on 7 Jan 2020

**HAL** is a multi-disciplinary open access archive for the deposit and dissemination of scientific research documents, whether they are published or not. The documents may come from teaching and research institutions in France or abroad, or from public or private research centers.

L'archive ouverte pluridisciplinaire **HAL**, est destinée au dépôt et à la diffusion de documents scientifiques de niveau recherche, publiés ou non, émanant des établissements d'enseignement et de recherche français ou étrangers, des laboratoires publics ou privés.

# Homemade fenestrated stent-graft for thoracic endovascular aortic repair of zone 2 aortic lesions

Ludovic Canaud, MD, PhD,<sup>a</sup> Kiyofumi Morishita, MD,<sup>b</sup> Thomas Gandet, MD,<sup>a</sup> Julien Sfeir, MD,<sup>a</sup> Sebastien Bommart, MD,<sup>a</sup> Pierre Alric, MD, PhD,<sup>a</sup> and Marcello Mandelli, MD<sup>c</sup>

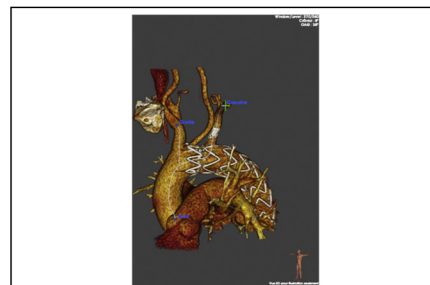## ABSTRACT

**Objective:** The aim of this retrospective analysis was to evaluate the outcomes of homemade fenestrated stent-grafts for thoracic endovascular aortic repair of zone 2 aortic lesions.

**Methods:** From November 2013 to January 2017, 24 patients underwent thoracic endovascular aortic repair with left subclavian artery revascularization using a homemade fenestrated stent-graft to preserve the patency of the left subclavian artery. Elective cases accounted for 54% (n = 13) of the sample. Indications included acute complicated type B aortic dissection (n = 9), degenerative aneurysm (n = 9), penetrating aortic ulcer (n = 5), and intramural hematoma (n = 1). Routine postoperative follow-up imaging with computed tomography angiography was performed to assess thoracic endovascular aortic repair and left subclavian artery fenestration patency and endoleak.

**Results:** Median duration for stent-graft modification was 16 minutes (range, 14-17 minutes). The technical success rate was 100%. One patient had a distal type I endoleak requiring additional stent-graft placement. One patient had partial coverage of the left common carotid artery requiring left common carotid artery stenting. One patient had a stroke without permanent sequelae (4.1%). Overall mortality was 0%. All left subclavian arteries were patent. Two type III endoleaks required additional left subclavian artery covered stent placement. One type II endoleak is currently observed. During a mean follow-up of  $13.2 \pm 2$  months, there were no conversions to open surgical repair, aortic rupture, paraplegia, or retrograde dissection.

**Conclusions:** The use of a homemade fenestrated stent-graft for thoracic endovascular aortic repair of zone 2 aortic lesions is both feasible and effective for left subclavian artery revascularization during thoracic endovascular aortic repair involving a spectrum of thoracic aortic pathology. Durability concerns will need to be assessed in additional studies with long-term follow-up.



Patients treated with a homemade fenestrated stent-graft for TEVAR of a complicated chronic type B dissection.

### Central Message

The use of a homemade fenestrated stent-graft for TEVAR of zone 2 aortic lesions is both feasible and effective for LSA revascularization during TEVAR.

### Perspective

The use of a homemade fenestrated stent-graft for TEVAR of zone 2 aortic lesions is both feasible and effective for LSA revascularization during TEVAR. Durability concerns will need to be assessed in additional studies with long-term follow-up.

Since the first report by Dake and colleagues,<sup>1</sup> endovascular repair has emerged during the past decades as a valuable treatment for descending thoracic aortic diseases. Left subclavian artery (LSA) coverage during thoracic endovascular

aortic repair (TEVAR) often is required to achieve a suitable proximal landing zone and is performed in up to 40% of procedures.<sup>2</sup> Intentional stent-graft coverage of the LSA initially was thought to be a viable alternative in this setting to extend the applicability of TEVAR. Experience with intentional LSA coverage without revascularization unfortunately has demonstrated a significant association with

From the <sup>a</sup>Department of Thoracic and Vascular Surgery, Arnaud de Villeneuve Hospital, Montpellier, France; <sup>b</sup>Department of Cardiovascular Surgery, Hakodate Municipal Hospital, Hakodate, Japan; and <sup>c</sup>Department of Vascular Surgery, Santa Helena Hospital, Florianópolis, Brazil.

Received for publication Feb 22, 2017; revisions received May 13, 2017; accepted for publication July 3, 2017.

Address for reprints: Ludovic Canaud, MD, PhD, Service de Chirurgie Vasculaire et Thoracique, Hôpital A de, Villeneuve, 191 av Doyen Gaston Giraud, Montpellier 34090, France (E-mail: [ludoviccanaud@hotmail.com](mailto:ludoviccanaud@hotmail.com)).

### Abbreviations and Acronyms

LCCA = left common carotid artery  
 LSA = left subclavian artery  
 TEVAR = thoracic endovascular aortic repair

spinal cord and left upper limb ischemia, as well as vertebral territory stroke.<sup>3,4</sup>

Reports of procedures that maintain the patency of the LSA include debranching before elective TEVAR,<sup>5</sup> the chimney technique of deployment of a LSA stent parallel to the thoracic stent-graft,<sup>6</sup> and retrograde laser fenestration.<sup>7</sup> Branched stent-grafts have been proposed that permit complete endovascular aortic arch repair.<sup>8</sup> This approach has several limitations. The time required to manufacture and deliver custom-made stent-grafts preclude their use for urgent cases. We have already reported the use of homemade proximal scalloped stent-grafts for TEVAR of zone 2 acute aortic syndromes.<sup>9</sup> However, patients are only considered suitable for a scalloped stent-graft if the minimum healthy aorta is at least 15 mm from the expected position of the edge of the scallop, both proximally and laterally. Therefore, several patients are not eligible for this approach, especially for lesions involving the outer curve of the aortic arch.

The purpose of the following retrospective analysis was to review our experience with a homemade fenestrated stent-graft for TEVAR of zone 2 aortic lesions.

## MATERIALS AND METHODS

### Patients

Protocol and informed consent were approved by the Institutional Review Boards. All patients gave written consent, and the local authorities approved the study. Patients treated using physician-modified thoracic stent-grafts for the treatment of aortic arch lesions in 3 tertiary referential center were included (A de Villeneuve Hospital, Montpellier, France; Hakodate Municipal Hospital, Hakodate, Japan; and Santa Helena Hospital, Florianopolis, Brazil). All patients were considered to be at high surgical risk because of serious comorbidities (American Society of Anesthesiologists score  $\geq$ III or emergency repair).

This experience with homemade fenestrated thoracic stent-grafts started in August 2013. Consecutive patients with zone 2 aortic lesions undergoing endovascular repair using homemade fenestrated stent-grafts were included. The homemade stent-grafts created at our institutions are individually designed to fit the aortic configuration of each patient. Patients with zone 2 aortic lesions with a proximal and distal aortic neck diameter of less than 40 mm were considered possible candidates for endovascular aortic repair using a fenestrated thoracic stent-graft. We only consider the use of fenestrated thoracic stent-grafts if the proximal neck is healthy (nondissected) and more than 15 mm in length. The distance between the LCCA and the proximal part of the lesion has to be 15 mm in length. If not, this lesion will be considered as a zone 1 aortic arch lesion.

All patients underwent high-resolution computed tomography angiography preoperatively. Demographic, anatomic, intraoperative, and postoperative data were recorded by means of a prospectively maintained database. Follow-up computed tomography angiography was performed at 1 week and 3 and 6 months and annually thereafter.

### Planning, Sizing, and Device Preparation

Procedure planning and device sizing were performed using a dedicated 3-dimensional vascular imaging workstation (Aquarius WS, Terarecon Inc, Mateo, Calif; or the OsiriX Imaging Software package, Geneva, Switzerland) with centerline luminal reconstructions.

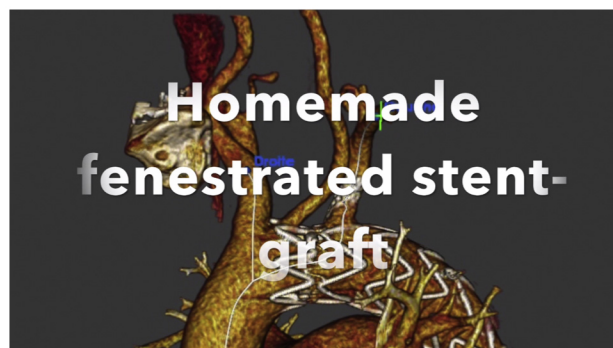
Centerline luminal reconstruction is used to determine the aortic diameter at the proximal and distal landing zone. Stent-grafts of sufficient length were selected to enable proximal and distal landing zones in healthy aorta of at least 15 mm. The stent-graft oversizing was less than 10% for acute aortic dissection and between 10% and 15% for other aortic arch pathologies. Centerline luminal reconstruction also is used to determine the distance between the proximal edge of the stent-graft and the center of the fenestration. The centerline length measurement between the top of the landing zone (or fabric) and the middle of the origin of each target vessel is recorded and used to determine the distance between the proximal edge of the stent-graft and center of the fenestration. Volume-rendering images are used to determine the optimal position of the C arm and to evaluate the aortic arch tortuosity.

Modification of the stent-graft was performed on a back table, commencing before the start of anesthesia (Video 1). A portion of the device is unsheathed. Our preference is to unsheathe the area to be modified plus 1 additional stent. The fenestration is premarked in the main stent-graft according to the measurements obtained from centerline analysis.

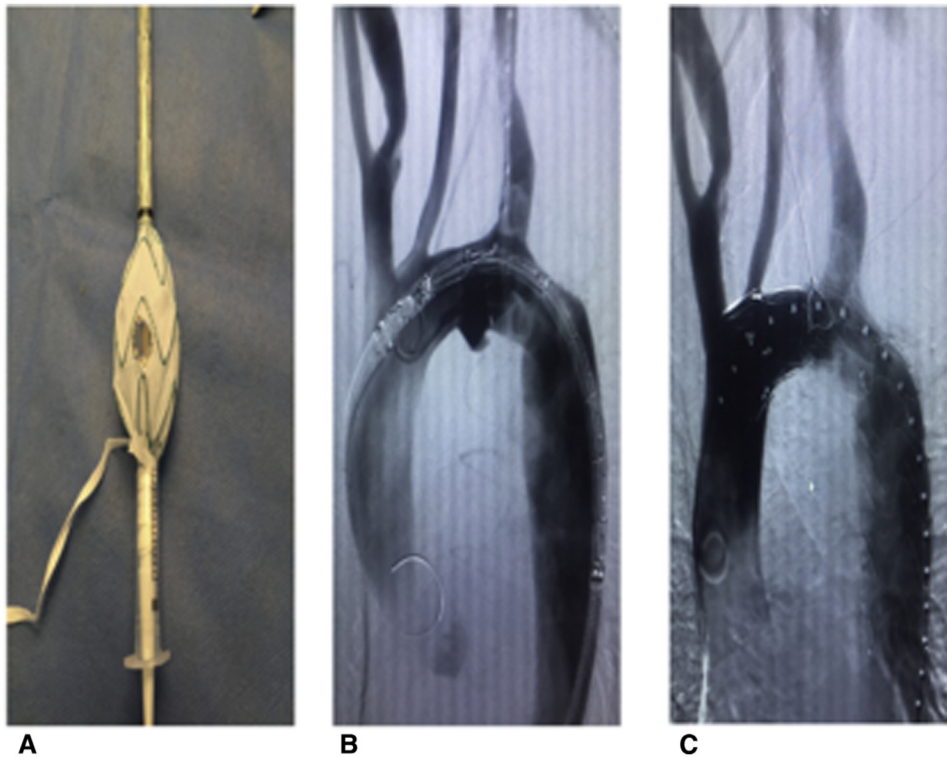
A single fenestration for the supra-aortic trunk target vessel of appropriate size and location is made between the stent-graft stent struts (Figure 1). Fenestrations are circular, do not have stent struts going across them, and are of comparable size to the target vessel. A sterile marking pen was used to mark the location of the fenestrations on the basis of length measurements determined using the reconstructed. Minor adjustments were made permitted to the site fenestrations to facilitate use of strut-free fenestrations. A cautery device was used to carefully burn the Dacron fabric to create the fenestration. Thereafter, to enforce sealing power around the fenestration (the covered stent may be dilated and locked against the nitinol ring to create a seal), a radiopaque nitinol wire is sewn onto the edge of the fenestration.

### Technique

All procedures were performed under general anesthesia, through a surgical cut-down of the common femoral artery. Procedures have been performed in an operating room equipped with a C-arm or in a hybrid room. Heparin (5000 IU) is administered as the thoracic stent-graft is introduced over an ultra-stiff guidewire. Angiographic runs are performed through a pigtail catheter, introduced percutaneously



**VIDEO 1.** Technique of creation of a homemade fenestrated stent-graft for TEVAR.



**FIGURE 1.** A, The Valiant (Medtronic Inc, Santa Rosa, Calif) thoracic stent-graft was partially unsheathed. The proximal fenestration was performed. Radio-opaque markers are positioned and delineated the fenestration. B, Intraoperative angiography used to align the radiopaque marker of the fenestration with the LSA. C, Completion angiography demonstrates the exclusion of the saccular aneurysm and patency of the LSA.

through the contralateral common femoral artery. Mean blood pressure at deployment is lowered to approximately 80 mm Hg to optimize accuracy.

Because the branch vessels originate from the arch's superior aspect, it is necessary to position the delivery system such that the stent-graft fenestration is oriented superiorly on entering the arch. The stent-graft fenestration markers are positioned on the outer curve of the thoracic aorta. We have to ascertain that the fenestration is oriented toward the LSA by aligning the radiopaque marker with LSA. If not aligned, the stent-graft was pulled back in the descending thoracic aorta. We rotated the stent-graft to adjust the position of fenestration. Thereafter, the stent-graft was reintroduced into the aortic arch. A 7F sheath was placed through the retrograde left brachial artery access at the ostium of the LSA.

The stent-graft is partially unsheathed. The optimal position of the C arm was determined preoperatively on 3-dimensional reconstruction. An left anterior oblique angiogram of the aortic arch is used to align the radiopaque marker with the target vessel. A perpendicular angiogram also is obtained to aid clock face alignment. After ascertaining that the fenestration is oriented toward the supra-aortic trunk target vessel, the stent-graft is partially deployed. Minor adjustments are possible to rotate the stent-graft to adjust the position of fenestrations once the first stents are deployed. A 0.035-inch guidewire from the brachial access was advanced through the fenestration into the stent-graft lumen. The 7F brachial sheath is then advanced through the fenestration into the stent-graft lumen. Then, the thoracic stent-graft is fully deployed. An 8- to 10-mm balloon expandable iCAST covered stent (Atrium, Hudson, NH) was deployed, 38 or 59 mm in length. The stent was deployed approximately one quarter into the stent-graft lumen and three quarters into the branch vessel. The intra stent-graft portion of the covered stent was flared using a 14- to 20-mm balloon introduced from the brachial access.

Follow-up surveillance was performed with serial computed tomography scans at 1 week; at 3, 6, and 12 months; and annually thereafter. A duplex scan was performed in case of clinical or computed tomography abnormality.

## RESULTS

From November 2013 to January 2017, 24 patients underwent TEVAR with LSA revascularization using a homemade fenestrated stent-graft to preserve the patency of the LSA. There were 17 men and 7 women (mean age,  $68.9 \pm 9$  years; range, 58-85 years) (Table 1).

Indications included acute complicated type B aortic dissection ( $n = 9$ ), degenerative aneurysm ( $n = 9$ ), penetrating aortic ulcer ( $n = 5$ ), and intramural hematoma ( $n = 1$ ). Elective cases accounted for 54% ( $n = 13$ ) of the sample.

The Valiant device (Medtronic Inc, Santa Rosa, Calif) was used in all the cases. An average of 1.6 stent-grafts (range, 1-2) were deployed. The mean proximal sealing length was  $19.9 \pm 4$  mm. LSA-covered stents were 8 to 10 mm in diameter.

### Thirty-Day Outcomes

Median duration for stent-graft modifications was 16 minutes (range, 14-17 minutes) (Table 2). The technical success rate was 100%. One patient had partial coverage of the left common carotid artery (LCCA) requiring LCCA

**TABLE 1. Patient demographics**

	N	%
Age (mean, y)	68.9 ± 9	
Gender (M/F)	17/7	
Pathology		
Degenerative aneurysm	9	37.5
Complicated acute type B dissection	9	37.5
Penetrating aortic ulcer	5	20.8
Intramural hematoma	1	4.2
Preoperative comorbidities		
Chronic cardiac failure	3	12.5
Coronary artery disease	5	20.8
Chronic renal failure	2	8.4
Chronic obstructive pulmonary disease	3	12.5
Hypertension	22	91.6
Diabetes mellitus	6	25
Previous cerebrovascular accident	3	12.5
Emergency repair	11	45.8

stenting to maintain the patency of the LCCA. One patient had femoral artery injury requiring femoro-femoral bypass. One patient had a stroke without permanent sequelae (4.1%) located in the left middle cerebral artery. One patient had a distal type I endoleak requiring additional stent-graft placement 1 week after the initial procedure. One patient had a type III endoleak requiring additional LSA covered stent deployment on postoperative day 7. Overall mortality was 0%. All LSAs were patent. One type II endoleak from a vertebral artery originating from the aortic arch was managed conservatively. No paraplegia or retrograde dissection was recorded in the immediate perioperative period.

### Follow-up

During a mean follow-up of  $13.2 \pm 2$  months, there were no conversions to open surgical repair. The overall mortality rate was 0%. Type I endoleak rate was 0%. All LSAs were patent. One patient had a secondary type III endoleak requiring additional LSA-covered stent deployment. No aortic rupture, paraplegia, or retrograde dissection was recorded during follow-up.

### DISCUSSION

This retrospective analysis reports our experience with homemade fenestrated stent-grafts for TEVAR of zone 2 aortic lesions. With a 0% aortic-related mortality, no cases of type I endoleak, and patency of all the revascularized LSAs, we can conclude that homemade fenestrated stent-grafts are feasible and provide encouraging results in the short term.

This approach is an effective option for maintaining LSA vascularization during TEVAR involving a spectrum of

**TABLE 2. Procedure details**

	N	%
Minimal sealing length (mean, mm)	19.9 ± 4	
Aortic coverage length (mean, mm)	196.7 ± 38	
Duration for stent-graft modifications (mean, min)	16	
Technical success rate	24	100
Endoleak		
Proximal type I endoleak	0	0
Type II endoleak	1	4.2
Type III endoleak	2	8.4
Stroke	1	4.1
Spinal cord ischemia	0	0
Stent-graft migration	0	0
Fenestration patency	24	100
Retrograde aortic dissection	0	0
30-d mortality	0	0
Overall mortality	0	0
Mean follow-up (mean, mo)		

acute thoracic aortic pathology and provides a rapid, reproducible method of fenestrating the endograft material.

There are special anatomic considerations when using this technique. A minimum distance between the LCCA and the LSA of less than 5 mm precluded this approach. Fenestrated TEVAR is based on the principle of implanting a stent-graft with fenestrations that will align perfectly to the target vessels to extend the proximal landing zone. The diameter and morphology of the aorta at the relevant segment also must allow the fenestration to be close to the target vessel. In patients with aneurysms involving the greater part of the arch or when the stent-graft cannot appose the aortic wall at the level of the target vessels, a branched endograft is more suitable to achieve seal. This is the main technical limitation of the use of physician-fenestrated thoracic stent-grafts. However, modified branched stent-grafts for thoracoabdominal aortic aneurysm are currently being investigated and could be proposed for the aortic arch.<sup>10</sup>

All of these systems are customized, requiring accurate preoperative planning. Ascertaining that the fenestration or the scallop is well oriented toward the supra-aortic trunk target vessel is crucial. Because of the homemade nature of these devices, graft rotation and misalignment of the fenestration/vessel ostium interface can still occur. Precise deployment of these fenestrated arch stent-grafts is important to correctly orient the fenestrations toward the branches for which they are intended. During stent-graft deployment, minor adjustments are possible to rotate the stent-graft to adjust the position of fenestrations once the first stents are deployed. In addition, the aorta may change configuration after insertion of the semi-rigid stent-graft

and thus alter alignment of the side branches. However, this was not observed in our experience.

The fragility of homemade stent-grafts is a crucial problem. The question of fabric durability still needs to be evaluated. Metal fatigue and material deterioration are known complications of stent-grafting. These alterations might have an impact on general ring stability of the graft. In our series, no stent fractures were detected by routine radiologic follow-up examinations. The long-term interactions between the stent-graft and the covered stent will need to be monitored closely over time because of the potential for stent collapse or stent breakage and the development of a late type III endoleak between the 2 components. Careful long-term monitoring of patients is required to avoid major complications resulting from inadequate durability of these devices.

The diameter and morphology of the aorta at the relevant segment also must allow the fenestration to be close to the target vessel. In patients with aneurysms involving the greater part of the arch or when the stent-graft cannot appose the aortic wall at the level of the target vessels, a branched endograft is more suitable to achieve seal. This is the main technical limitation of the use of physician-modified thoracic stent-grafts.

The disadvantages are the necessity for the physician to spend time modifying the endograft, lack of industrial quality control after device modification, and lack of a sizeable body of evidence supporting its use. Modification of commercially available devices by physicians may void any guarantee of safety by the manufacturer, and systematic evaluation of such devices is best done within a protocol approved at the institutional or regulatory level.

There are multiple endovascular options available to treat zone 2 aortic lesions. Intentional coverage of the LSA during TEVAR has been performed routinely by some and is thought to be associated with a low risk of clinically significant complications. However, evidence is mounting that LSA coverage is associated with a significant risk of spinal cord ischemia, vertebral territory stroke, and left upper limb ischemia.<sup>2-4</sup> In 2009, these findings led to the Society for Vascular Surgery Committee on Aortic Disease to suggest routine preoperative revascularization for planned coverage of the LSA during elective TEVAR.<sup>11</sup> These guidelines did make exceptions in the setting of emergency TEVAR or when other circumstances would preclude preoperative LSA revascularization.

Regarding the applicability of this approach for zone 0 and 1 aortic lesions, we know that correctly deploying and cannulating a double-fenestrated stent-graft can be challenging, especially if the aortic anatomy is unfavorable. Correct orientation of the fenestrations is the Achilles' heel of this approach if the fenestrations are slightly off target; it may be necessary to manipulate a semiconstrained or partially deployed arch stent-graft to orient fenestrations

correctly, which could increase the risk of cerebral embolization. In case of zone 0 or 1 aortic arch lesions, to decrease the risk of cerebral embolization or misalignment of 1 of the fenestrations, we prefer to use a thoracic stent-graft with a single proximal fenestration to preserve flow into the LCCA or the brachiocephalic trunk combined with cervical debranching for preserving patency of the LCCA and the LSA.

We used the Medtronic stent-graft because we have extensive experience with this device. Furthermore, it is currently the most conformable of the devices available. The tip capture facilitates accurate deployment. Other devices could be used for the same approach, namely, the Bolton (Bolton Medical, Sunrise, Fla) and the Cook Alpha (Cook Medical, Bloomington, Ind). The deployment system of the Gore device (WL Gore & Associates, Inc, Flagstaff, Ariz) prevents reloading of the stent-graft into the sheath.

There are several different alternatives to LSA coverage that allow an adequate proximal seal for thoracic stent-grafting. Open LSA revascularization (bypass to or transposition of the LSA) often requires longer operative times and the need for multiple surgical interventions with staged stent-grafting. Open revascularization also has potential risks for vocal cord paralysis and injury to the thoracic duct, brachial plexus, and phrenic nerve. Parallel grafts such as the chimney technique constitute an alternative. Encouraging short-term results have been reported in small series, but type Ia endoleaks through the gutters and uncertainty regarding the long-term patency of artery covered stents remain a concern.<sup>6</sup>

In situ retrograde laser fenestration is a feasible and effective option for LSA revascularization. Redlinger and colleagues<sup>7</sup> reported 22 patients. Technical success was 100%. No major in situ laser fenestration-related operative complications occurred. However, special attention must be paid to anatomic considerations. The judicious use of multiple C-arm projections before laser fenestrations ensures that the laser fiber is aligned appropriately. Furthermore, the angle of LSA take-off from the aortic arch has a considerable influence on the technical ease and success of laser fenestration.

Other off-the-shelf branch devices (Valiant Mona LSA; Medtronic, Inc) and the Gore single-side branch (WL Gore & Associates, Inc) consist of a main stent-graft and a branch stent-graft designed to maintain LSA patency while diverting circulation through the encroaching aneurysm.<sup>12</sup> This approach allows the preservation of the patency of the LSA during emergency TEVAR. However, these devices are not currently available on the market. Availability of branch device stent-grafts may limit the indications of physician-modified stent-grafts. The use of a side-branch (off-the-shelf) graft would allow treatment of a larger number of patients. However, the deployment of a side-branch graft is more challenging.

Until an “off-the-shelf” device is available, patients with rapidly expanding, symptomatic, or ruptured arch aneurysms who are poor candidates for open surgical repair have limited options other than immediate physician modification. More data are required to confirm the applicability of this approach and to establish durability. In the long-term, strict surveillance of these stent-grafts and modifications will be necessary to monitor and ensure durability of repair because of the potential for stent collapse or stent breakage.

## CONCLUSIONS

The use of homemade fenestrated thoracic stent-grafts for the treatment of zone 2 aortic arch lesions is both feasible and effective for LSA revascularization during TEVAR. Durability concerns will need to be assessed in additional studies with long-term follow-up.

## Conflict of Interest Statement

Authors have nothing to disclose with regard to commercial support.

## References

1. Dake MD, Miller DC, Semba CP, Mitchell RS, Walker PJ, Liddell RP. Transluminal placement of endovascular stent-grafts for the treatment of descending thoracic aortic aneurysms. *N Engl J Med*. 1994;331:1729-34.
2. Kotelis D, Geisbüsch P, Hinz U, Hyhlik-Dürr A, von Tengg-Kobligh H, Allenberg JR, et al. Short and midterm results after left subclavian artery coverage during endovascular repair of the thoracic aorta. *J Vasc Surg*. 2009; 50:1285-92.
3. Riesenman PJ, Farber MA, Mendes RR, Marston WA, Fulton JJ, Keagy BA. Coverage of the left subclavian artery during thoracic endovascular aortic repair. *J Vasc Surg*. 2007;45:90-4.
4. Patterson BO, Holt PJ, Nienaber C, Fairman RM, Heijmen RH, Thompson MM. Management of the left subclavian artery and neurologic complications after thoracic endovascular aortic repair. *J Vasc Surg*. 2014; 60:1491-7.
5. Canaud L, Ziza V, Ozdemir BA, Berthet JP, Marty-Ané CH, Alric P. Outcomes of left subclavian artery transposition for hybrid aortic arch debranching. *Ann Vasc Surg*. 2016;23:890-4.
6. Baldwin ZK, Chuter TA, Hiramoto JS, Reilly LM, Schneider DB. Double-barrel technique for preservation of aortic arch branches during thoracic endovascular aortic repair. *Ann Vasc Surg*. 2008;22:703-9.
7. Redlinger RE Jr, Ahanchi SS, Panneton JM. In situ laser fenestration during emergent thoracic endovascular aortic repair is an effective method for left subclavian artery revascularization. *J Vasc Surg*. 2013;58:1171-7.
8. Abraham CZ, Lioupis C. Treatment of aortic arch aneurysms with a modular transfemoral multibranch stent-graft: initial experience. *J Thorac Cardiovasc Surg*. 2013;145:110-7.
9. Canaud L, Gandet T, Khantalini I, Ozdemir BA, Marty-Ané CH, Alric P. Homemade proximal scalloped stent graft for thoracic endovascular aortic repair of zone 2 acute aortic syndrome. *J Thorac Cardiovasc Surg*. 2016;152: 1301-6.
10. Georgiadis GS, van Herwaarden JA, Antoniou GA, Hazenberg CE, Giannoukas AD, Lazarides MK, et al. Systematic review of off-the-shelf or physician modified fenestrated and branched endografts. *J Endovasc Ther*. 2016;23:98-109.
11. Matsumura JS, Lee WA, Mitchell RS, Farber MA, Murad MH, Lumsden AB, et al; Society for Vascular Surgery. The Society for Vascular Surgery Practice Guidelines: management of the left subclavian artery with thoracic endovascular aortic repair. *J Vasc Surg*. 2009;50:1155-8.
12. Roselli EE, Arko FR III, Thompson MM; Valiant Mona LSA Trial Investigators. Results of the Valiant Mona LSA early feasibility study for descending thoracic aneurysms. *J Vasc Surg*. 2015;62:1465-7.

**Key Words:** physician-modified thoracic stent-grafts, thoracic endovascular aortic repair