



HAL
open science

Infective endocarditis after device closure of atrial septal defects: Case report and review of the literature

Pascal Amedro, Camille Soulatges, Alain Fraisse

► To cite this version:

Pascal Amedro, Camille Soulatges, Alain Fraisse. Infective endocarditis after device closure of atrial septal defects: Case report and review of the literature. *Catheterization and Cardiovascular Interventions*, 2017, 89 (2), pp.324 - 334. 10.1002/ccd.26784 . hal-01823067

HAL Id: hal-01823067

<https://hal.umontpellier.fr/hal-01823067>

Submitted on 11 Dec 2019

HAL is a multi-disciplinary open access archive for the deposit and dissemination of scientific research documents, whether they are published or not. The documents may come from teaching and research institutions in France or abroad, or from public or private research centers.

L'archive ouverte pluridisciplinaire **HAL**, est destinée au dépôt et à la diffusion de documents scientifiques de niveau recherche, publiés ou non, émanant des établissements d'enseignement et de recherche français ou étrangers, des laboratoires publics ou privés.

Infective Endocarditis After Device Closure of Atrial Septal Defects: Case Report and Review of the Literature

Pascal Amedro,^{1,2*} MD, PhD, Camille Soulatges,¹ MD, and Alain Fraisse,³ MD, PhD

We report a case of late infective endocarditis in an 8-year-old boy 3 years after transcatheter closure of an atrial septal defect with the Amplatzer Atrial Septal Occluder Device. Echocardiography showed a very thick pannus lining the left atrial disc of the prosthesis, with some mobile elements. MRI showed several cerebral microemboli. The patient had dental caries and blood cultures found *Staphylococcus aureus*. Patient was treated with gentamicin and oxacillin before surgical removal of the prosthesis. Twenty-one cases of infective endocarditis after atrial defect device closure have been reported in the literature (13 ostium secundum ASD and 8 patent foramen ovale). Seven pediatric cases were reported. *S. aureus* was the most frequent bacterium. Antibiotics were administered in all cases and most patients ($n = 18$) underwent surgical removal of the device. Incomplete endothelialization of the prosthesis was a suggested mechanism. Two patients died after surgery.

Key words: Amplatzer Atrial Septal Occluder Device; ASD; atrial septal defect; infective endocarditis; pediatrics

INTRODUCTION

Infective endocarditis is a relatively rare complication associated with a significant morbidity and mortality [1]. Its prevention has not decreased its incidence (3–7 per 100,000 person-years) [2–4] probably as a consequence of medical progress [5].

In patients with congenital heart diseases (CHD), medical advances have modified the epidemiology of this population [6,7], considered at risk of developing infective endocarditis [8,9]. The incidence of infective endocarditis in adults with CHD has been estimated as between 15 and 140 times that of the general population and represents 0.42–4% of hospitalizations [10,11].

In recent guidelines, infective endocarditis prevention strategies have restrained antibiotic prophylaxis and reinforced nonspecific hygiene measures [8,12,13]. For CHD patients, antibiotic prophylaxis before dental procedure is now recommended in five situations: prosthetic valve, previous infective endocarditis, unrepaired cyanotic CHD (including palliative shunts and conduits), completely repaired congenital heart defect with prosthetic material or device (whether placed using

surgery or catheter intervention, during the first 6 months after the procedure), and repaired CHD with residual defects at the site or adjacent to the site of a prosthetic patch or prosthetic device [8,12].

Atrial septal defects (ASD) represent the second most frequent CHD (after ventricular septal defects),

¹Pediatric and Congenital Cardiology Department, M3C Regional Center, University Hospital, Montpellier, France

²Physiology and Experimental Biology of Heart and Muscles Laboratory - PHYMEDEXP, UMR CNRS 9214 - INSERM U1046, Montpellier, France

³Pediatric Cardiology Service, Royal Brompton and Harefield Hospital Trust, London, United Kingdom

*Correspondence to: Pascal Amedro; Pediatric and Congenital Cardiology Department, CHU Arnaud De Villeneuve, 371 avenue du Doyen Gaston Giraud, 34295 Montpellier Cedex 5, France. E-mail: p-amedro@chu-montpellier.fr

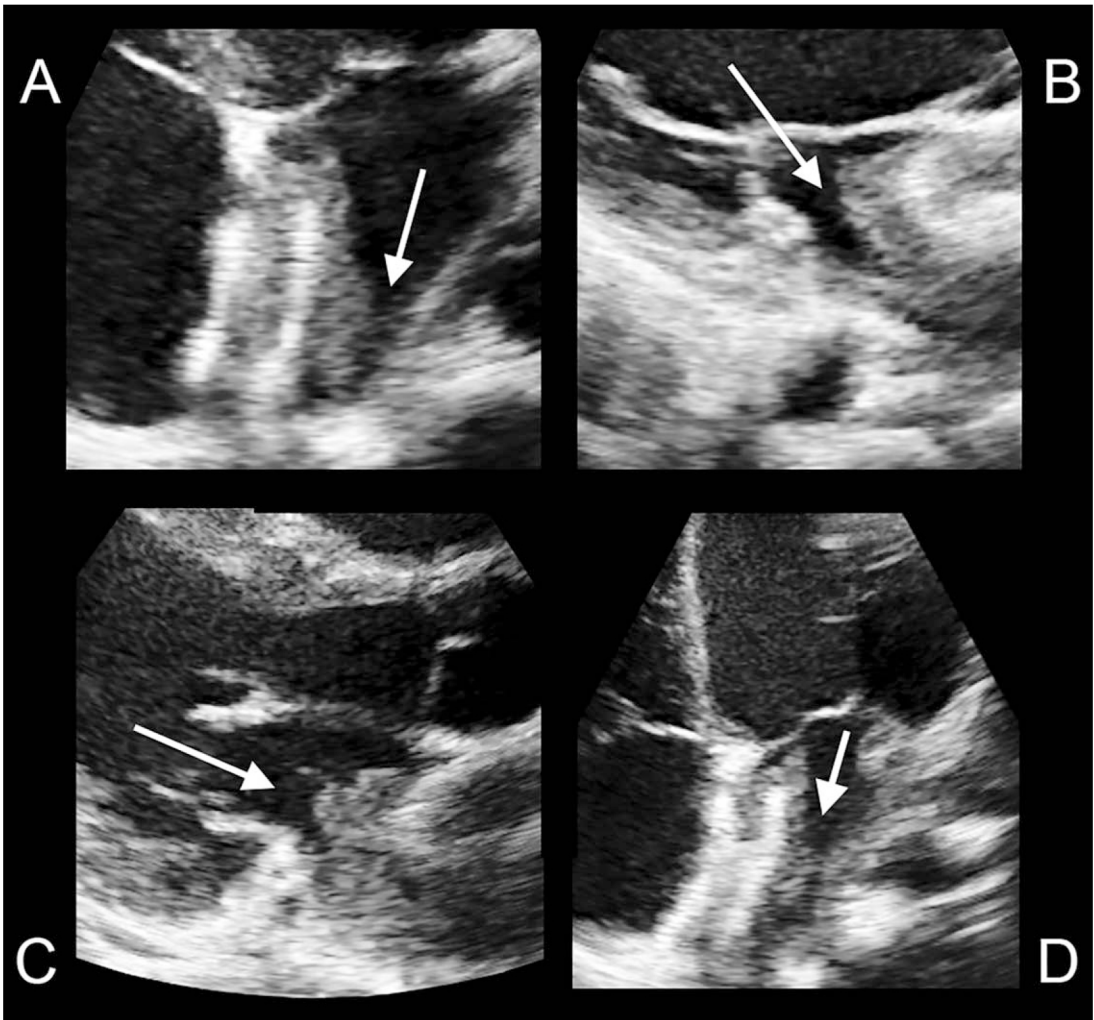


Fig. 1. Transthoracic echocardiographic images. Apical four chamber view shows thick panus on left side of ASO (arrow, A). Parasternal long-axis view shows hyperechogenic vegetation on left side of ASO (arrows, B and C). Decreasing in size of vegetation after 6 weeks antibiotic treatment (arrow, D).

with a worldwide reported birth prevalence of 2.62 per 1,000 live births [14]. Ostium secundum ASD are predominant (80%) and eligible for catheter closure when the left-to-right shunt is significant, depending on the size of atrial septal rims [15]. Patent foramen ovale (PFO) is a small interatrial shunt caused by incomplete apposition of the septum primum to the septum secundum. Catheter closure is usually performed on carefully selected patients, as we need more data from randomized clinical trials comparing oral anticoagulants, antiplatelet therapy, and catheter occlusion [16,17].

Prosthetic infective endocarditis after ASD transcatheter closure is extremely rare, especially beyond the first few months after the procedure. We report one recent pediatric case of late infective endocarditis that occurred in an 8-year-old boy. We also reviewed the

literature regarding infective endocarditis after atrial defect device closure.

METHOD

We searched three electronic databases on April 2016 (PubMed, EMBASE, and Web of Science) by using a combination of the terms “atrial septal defect” and “endocarditis.” We also used the terms “catheter device,” “device closure,” “patent foramen ovale,” “PFO,” “ASD,” “Amplatzer,” “ASO,” “STARFlex,” “CardioSEAL,” “infective endocarditis,” and “interventional catheterization” in combination. The selection criteria were as follows: follow-up after ASD device closure, catheter devices complications, prosthetic endocarditis, and articles written in English. We did not set any restriction to study

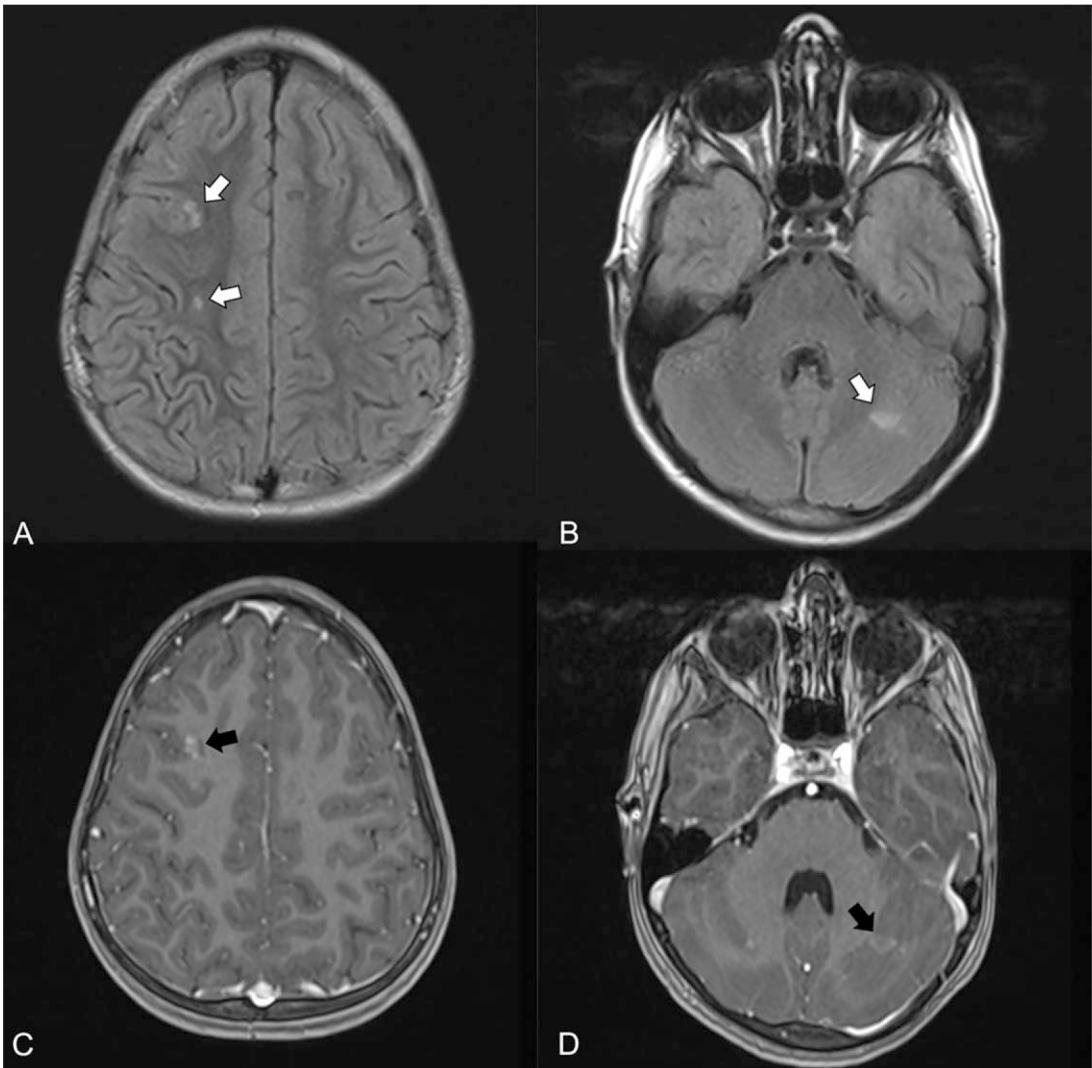


Fig. 2. Brain MRI. Axial-plane Flair T2-weighted sequences reveal multiple cortico-subcortical lesions in the right frontal area (white arrow, A) and in the left cerebellar hemisphere (white arrow, B), with slight gadolinium enhancement of some lesions in T1-weighted sequences (black arrows, C and D).

setting, era, or locale. Pediatric and adult patients were eligible. In title and abstract screening, two reviewers (P.A. and C.S.) independently reviewed articles identified by the search. Studies identified in title or abstract screening were included for full-text review.

CASE REPORT

At the age of five, our patient underwent transcatheter closure of ostium secundum ASD with the Amplatzer Atrial Septal Occluder Device (ASO; AGA Medical Corporation, Golden Valley, Minnesota). He was treated with antiplatelet therapy for 6 months post-implant (aspirin 5 mg/kg/day). Three years later, after a normal annual follow-up, he presented with pro-

longed fever, severe weight loss, and typical Janeway lesions on palms and soles. It is worthy noting that he had several untreated dental caries. Echocardiography showed a very thick pannus lining the left atrial disc of the prosthesis, with some mobile elements (Figure 1).

The patient presented no neurological symptoms but an MRI showed several cerebral microemboli (Figure 2). All blood cultures found Oxacillin-susceptible *Staphylococcus aureus*. The patient underwent intravenous antibiotic treatment with Gentamicin (2 weeks, 3 mg/kg/day) and Oxacillin (6 weeks, 200 mg/kg/day). Dental care was performed. Negative blood cultures were rapidly obtained. Echocardiography showed a decrease in the size of the pannus and the disappearance of mobile elements (Figure 1).

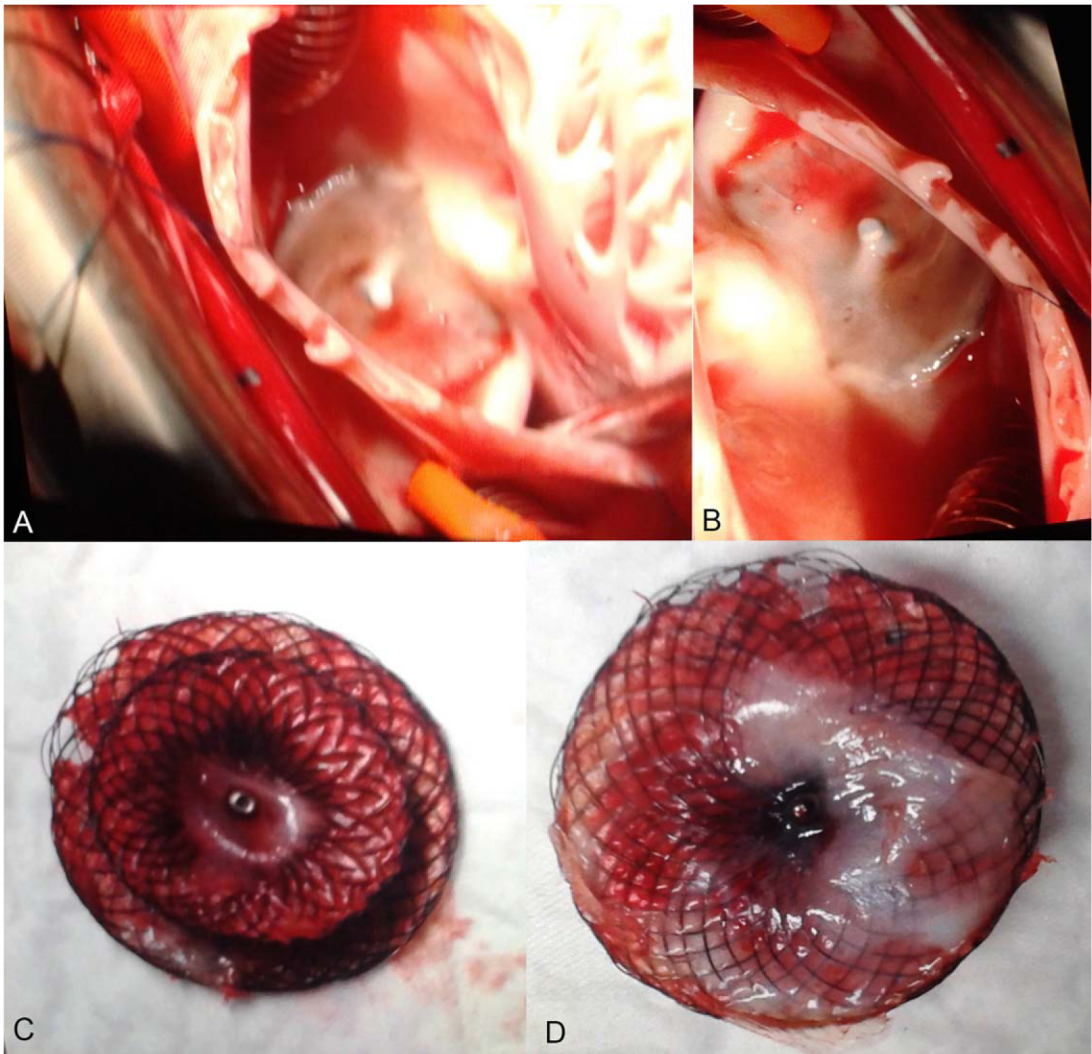


Fig. 3. Intraoperative photograph from right atrium view suggesting limited endothelialization of ASD (A,B). Removed ASD from right (C) and left (D) sides confirming limited endothelialization. [Color figure can be viewed at wileyonlinelibrary.com.]

After the end of medical treatment, a PET scan was performed and showed no activity. Cerebral lesions on the MRI remained stable. No immune deficiency was found. Three months after the end of antibiotic treatment, blood tests remained negative. After analyzing similar cases reported in the literature, we decided to remove the prosthesis surgically. After right atriotomy, under cardiopulmonary bypass and aortic cross-clamping, the cardiac surgeon noticed a slightly incomplete endothelialization on the right atrial disc. The prosthesis was carefully removed from the right to the left. The left side was approximately similar to the right but some slight and nonspecific thickening (Figure 3) was clearly present. The surgeon observed no vegetation or any other noticeable lesion and closed the ASD with a pericardial patch. The bacteriological

analysis of the prosthesis came back negative. After 2 years of follow-up, the patient's clinical course is favorable, including neurologically.

LITERATURE REVIEW

We selected seven ASD device follow-up studies [18–24], one meta-analysis of percutaneous and surgical ASD closure [25], and two FDA databases [26,27]. We identified twenty-one cases of infective endocarditis following atrial septal device closure [28–47] (Table I). Three studies did not meet the selection criteria (fungal endocarditis following ventricular septal defect hybrid procedure [48], atrial septal defect presenting with *Bruceella* endocarditis [49], and patch abscess after surgical closure of an atrial septal defect [50]).

TABLE I. Infective Endocarditis After Atrial Septal Device Closure: Review of the Literature															
Author	Year	Design	CHD	N	Age (Years)	Device	Residual shunt	Time interval ^a	Symptoms	Emboli	Diagnosis	Bacteria/germ	Management	Endothelialization	Vegetation
Sievert	1998	Follow-up cohort	OS, PFO	2/200	54	ASDOS	Yes	2 weeks	Pneumonia, death	No	TTE, BC	Coagulase negative staphylococcus	Surgical removal	N/S	N/S
Bullock	1999	Case report	OS	1	0.8	ASO 11 mm	No	43 days	Lung disease, pneumothorax after biopsy, infection on drain tube, fever	Yes	Culture of embolic material	<i>Staphylococcus aureus</i>	Surgical removal	N/S	N/S
										No	TTE, BC	<i>Staphylococcus aureus</i>	Vancomycin, gentamycin Surgical removal	Incomplete	RA
Goldstein	2002	Case report	PFO	1	42	CardioSEAL	No	2.5 months	Fever before procedure, Im-paired general condition,	No	TTE, TEE	<i>Bacillus pumilus</i>	Vancomycin, amoxicillin/clavulanic acid Surgical removal	N/S	LA
Calachanis	2004	Case report	PFO	1	72	CardiaStar	No	2 days	Fever before and after procedure	N/S	TEE, BC	Negative blood culture	Antibiotics	N/S	LA
Balasundaram	2005	Case report	OS	1	8	ASO 24 mm	No	3 months	Sepsis	No	TEE, BC	<i>Klebsiella pneumoniae</i> , acinetobacter	Vancomycin, cephalosporin, rifampicin Surgical removal	Yes	LA, RA
Divchev	2007	Case report	PFO	1	57	STARFlex	No	6 months	Palpitations	No	Abscess on device	N/S	Surgical removal	N/S	LA, RA
Slesnick	2008	Case report	OS	1	4	ASO 22 mm	N/S	12 months	Septic shock	Yes	TEE, BC	<i>Staphylococcus aureus</i> (methicillin sensitive)	Nafcillin Surgical removal	No	LA, RA
Zahr	2010	Case report	OS	1	66	ASO 32 mm	N/S	30 months	Urinary tract infection, foot ulcer	N/S	TEE	<i>Staphylococcus aureus</i>	Vancomycin Surgical removal	No	LA
Doguet	2011	Case report	PFO	1	59	ASO 25 mm	N/S	3 months	Urinary tract infection	N/S	TEE	Negative blood culture	Surgical removal, antibiotics	Yes	LA, RA
Verma	2011	Follow-up cohort	PFO	1/13736	NS	CardioSEAL	N/S	N/S	N/S	N/S	N/S	N/S	Surgical removal	N/S	N/S
Walpot	2011	Case report	PFO	1	49	Helix	No	9 years	Cerebral emboli, fever	Yes	TEE	Negative blood culture	Vancomycin Surgical removal	N/S	LA
Sadiq	2012	Follow-up cohort	OS	1/205	3	ASO	N/S	3 months	Prolonged fever	No	No vegetation	Negative blood culture	Antibiotics	N/S	N/S
Aruni	2013	Case report	OS	1	59	ASO	N/S	Late	Sepsis	N/S	TEE, BC	<i>Staphylococcus aureus</i> (methicillin resistant)	Vancomycine, daptomycin	N/S	LA
Krantz	2014	Case report	PFO	1	32	ASO	N/S	2 years	Chest pain, im-paired general condition	Yes	TEE, BC	<i>Staphylococcus aureus</i> (methicillin resistant)	Antibiotics Surgical removal	Yes	LA
Iezzi	2014	Case report	OS	1	76	ASO 30 mm	N/S	5 years	Fever	No	TEE, BC	Negative blood culture	Surgical removal	N/S	LA

TABLE I. Continued

Author	Year	Design	CHD	N	Age (Years)	Device	Residual shunt	Time interval ^a	Symptoms	Emboli	Diagnosis	Bacteria/germ	Management	Endothelialization	Vegetation
Bialkowski	2015	Case report	OS	1	19	ASO 24 mm	N/S	2 years	Meningitis	Yes	TTE, BC	<i>Staphylococcus aureus</i> (methicillin sensitive)	Oxacillin, imipenem Surgical removal	No	LA
Jha	2015	Case report	OS	1	10	ASO	N/S	6 years	Septic shock, pleural effusion, pericardial effusion, cellulitis	Yes	TTE, BC	<i>Streptococcus pyogenes</i>	Antibiotics Surgical removal	Incomplete	Inter-atrial septum
Kim	2015	Case report	OS	1	37	ASO 24 mm	No	4 years	Fever, muscular pain, Janeway lesions	N/S	TEE, BC	<i>Staphylococcus aureus</i> (methicillin sensitive)	Nafcillin, rifampicin Surgical removal	No	LA, RA
Thibodeau	2015	Case report	OS	1	71	ASO 28 mm	N/S	4 years	Cerebral emboli, fever	Yes	TEE, BC	<i>Streptococcus beta hemolytic</i>	Antibiotics Surgical removal	No	LA
Nguyen	2016	Case report	OS	1	4	ASO	N/S	12 years	Pharyngitis, petechiae, finger-nails hemorrhages	Yes	TEE, BC	<i>Staphylococcus aureus</i> (methicillin sensitive)	Oxacillin, gentamycin Surgical removal	Incomplete	LA
Amedro	2016	Case Report	OS	1	5	ASO	N/S	3 years	Fever, impaired general condition, Janeway lesions	Yes	TTE, BC	<i>Staphylococcus aureus</i>	Oxacillin, gentamycin Surgical removal	Incomplete	LA

^aTime interval between device implantation and endocarditis.

Abbreviations: ASDOS, atrial septal defect occlusion system (Sulzer Ospyka, Rheinfelden, Germany); ASO, Amplatzer septal occluder; BC, blood culture; CHD, congenital heart disease; LA, left atrium; N/S, not specified; OS, ostium secundum atrial septal defect; PFO, patent foramen ovale; RA, right atrium; TEE, transoesophageal echocardiography; TTE, transthoracic echocardiography.

TABLE II. Summary Table

Clinical data		N	References		
CHD	<i>Ostium secundum</i> ASD	13	[28,29,32,34,35,39,40,42–45,47,53]		
	PFO	8	[28,30,31,33,36–38,41]		
Device	ASO	14	[29,32,34–36,39–45,47,53]		
	ASDOS	2	[28]		
	CardioSEAL	2	[30,37]		
	STARFlex	1	[33]		
	Cardiastar	1	[31]		
	Helix	1	[38]		
	<6 months	7	[28–32,36,39]		
Time interval since procedure	6–24 months	5	[28,33,34,41,53]		
	> 24 months	7	[35,38,42–45,47]		
	Not specified	2	[37,40]		
Diagnosis	Blood culture	Staphylococcus Aureus	10	[28,29,34,35,40–42,44,47,53]	
			Coagulase negative	1	[28]
			<i>Bacillus pumilus</i>	1	[30]
			<i>Klebsiella pneumoniae</i> and acinetobacter	1	[32]
			Streptococcus Pyogenes	1	[43]
			Beta hemolytic	1	[45]
			Negative	4	[31,36,38,39]
			Not specified	2	[33,37]
		Symptoms	Fever	8	[29–31,38,39,42,44,45]
			Sepsis	5	[28,32,34,40,43]
	Urinary tract infection		2	[35,36]	
	Cerebral emboli		2	[38,45]	
	Cutaneous lesions		Cellulitis	1	[43]
			Foot ulcer	1	[35]
			Janeway lesions	1	[44]
	Palpitations		1	[33]	
	Pain		Chest pain	1	[41]
			Muscular pain	1	[44]
		Petechiae	1	[47]	
	Echocardiography	TEE	13	[30–32,34–36,38,40–42,44,45,47]	
TTE		5	[28–30,43,53]		
Vegetation	Left atrium	10	[30,31,35,38,40–42,45,47,53]		
	Right atrium	1	[29]		
	Left and right atrium	6	[32–34,36,43,44]		
	Not specified	4	[28,37,39]		
	Antibiotics only	3	[31,39,40]		
Treatment	Surgical removal of device	18	[28–30,32–38,41–45,47,53]		
	Endothelialization	5	[34,35,44,45,53]		
	Absent	3	[29,43,47]		
	Incomplete	3	[32,36,41]		
	Present	3	[32,36,41]		
	Not specified	10	[28,30,31,33,37–40,42]		

Infective endocarditis is commonly considered to be an exceptional event following percutaneous ASD device closure. No cases of endocarditis were reported in seven large series that included a total of 3568 patients who underwent ASD closure with mean follow-up ranging from 2 to 20 years [18–24]. In their review and meta-analysis of 1812 percutaneous versus 1270 surgical ASD closures, Butera et al. [25] only found one case of endocarditis in the “surgery” group. No case of endocarditis were reported in the FDA Maude database (United States Food and Drug Administration

manufacturer and user facility device experience) among approximately 12,000 devices from AGA Medical Corporation (Amplatzer) and 8,950 devices from NMT Medical (STARflex, CardioSEAL) [26,27].

Eight cases of infective endocarditis occurred after patent foramen ovale (PFO) percutaneous closure (1 ASDOS, 2 CardioSEAL, 2 ASO, 1 Helix, 1 CardioStar, 1 STARFlex). Twelve cases of ostium secundum ASD were closed with ASO devices (size 22–32 mm, size not specified for 7 patients). Including our pediatric patient, 7 cases of infective endocarditis occurred in

children, after ostium secundum ASD device closure (mean age at procedure of 5 years). The absence of postprocedure residual shunt was only reported in six patients, but mostly not specified. Mean age when endocarditis occurred in the adult group was 53 years old. Diagnosis was made from 2 days to 12 years after the procedure. Thirteen cases can be considered to be late infective endocarditis (6 months or more after procedure). Five patients developed early symptoms following device implantation: 2 days after intervention for one patient (procedure carried out under antibiotics following a recent infection), and 2–3 months after the procedure for 3 patients. In each case, a history of recent infection before the procedure was noted.

Various clinical presentations included persistent fever, impaired general condition, chest pain, cerebral emboli, urinary tract infection, meningitis, petechiae, palpitations, and septic shock. A history of dental caries was never mentioned (besides our pediatric case).

Diagnosis was made by transesophageal echocardiography (TEE) and positive blood cultures in most cases, sometimes by transthoracic echocardiography (TTE) especially in the pediatric cases. *Staphylococcus aureus* was found in most cases. Other reported germs were streptococcus, *Bacillus pumilus*, and *Klebsiella pneumoniae*. Negative blood cultures occurred in four cases.

Most patients ($n=18$) underwent surgical removal of the device, usually after at least 2–3 weeks of antibiotics. All the patients received antibiotics for at least 6 weeks. A few patients were treated with antibiotics only. Endothelialization of the device was reported by surgeon as absent or incomplete in 8 cases, complete in 3 cases and not specified in 10 cases. Two adult patients died after surgery [28] (Table II).

DISCUSSION

Mechanisms of infection after ASD device closure remain unclear. In many of these reported cases, it is difficult to know whether the introduction of bacteria occurred before, during, or after the catheter procedure. However, in some cases, patients with recent infections underwent a catheter procedure [30]. Even if preanesthetic blood tests are negative, we recommend postponing ASD closure when the patient presents with any recent clinical symptoms of infection.

In other reported cases of infective endocarditis, some invasive procedures were performed shortly after catheter occlusion, suggesting bacteremia following skin puncture. The risk for infective endocarditis might have therefore been underestimated [29].

Some authors suggested that infection might have occurred before the end of neo-endothelialization, with

seeding of microorganisms after the procedure, and development of thrombus and bacteremia. In animal studies, the neo-endothelium is supposed to completely recover the ASD prosthesis within a few weeks [51]. Therefore, the length of antiplatelet therapy and antibiotic prophylaxis of endocarditis has been arbitrarily recommended for 6 months after ASO implantation [12].

These cases of infective endocarditis might therefore challenge the duration of endocarditis prophylaxis after transcatheter ASD closure. Recent guidelines on prevention, diagnosis, and treatment of infective endocarditis recommend good oral hygiene and regular dental care to reduce the risk of infection [8,12]. However, in a recent survey, more than half of the pediatric cardiologists do not follow the American Heart Association 2007 guidelines in their practice [52]. Therefore, counseling for optimal oral health in patients at risk of infective endocarditis needs to be improved in current practice.

LIMITATIONS

This review is designed as a summary; therefore, no conclusions can be drawn.

CONCLUSION

Infective endocarditis is considered to be an exceptional event following percutaneous ASD device closure. However, 21 cases had previously been reported in the literature, besides our current pediatric case report. Specific infectious mechanisms remain unclear. Therefore, before ASD closure, recent infectious events should be investigated and, if suspected, catheter procedure should be postponed. As incomplete device endothelialization is impossible to detect in routine follow-up, it may be worth insisting on prevention of infection on a long-term, or even life-long, basis following ASD device closure. Moreover, oral health prevention probably needs to be reinforced.

ACKNOWLEDGMENT

We thank Doctor Pierre Meyer (Pediatric Neurology Department, University Hospital, Montpellier, France) and Sebastien Mounier (graphic designer) for their contribution to this work. Galien Health Publishing provided medical writing assistance.

REFERENCES

1. Murray CJ, Vos T, Lozano R, Naghavi M, Flaxman AD, Michaud C, Ezzati M, Shibuya K, Salomon JA, Abdalla S, Aboyans V, Abraham J, Ackerman I, Aggarwal R, Ahn SY, Ali

- MK, Alvarado M, Anderson HR, Anderson LM, Andrews KG, Atkinson C, Baddour LM, Bahalim AN, Barker-Collo S, Barrero LH, Bartels DH, Basanez MG, Baxter A, Bell ML, Benjamin EJ, Bennett D, Bernabe E, Bhalla K, Bhandari B, Bikbov B, Bin Abdulhak A, Birbeck G, Black JA, Blencowe H, Blore JD, Blyth F, Bolliger I, Bonaventure A, Boufous S, Bourne R, Boussinesq M, Braithwaite T, Brayne C, Bridgett L, Brooker S, Brooks P, Brugha TS, Bryan-Hancock C, Bucello C, Buchbinder R, Buckle G, Budke CM, Burch M, Burney P, Burstein R, Calabria B, Campbell B, Canter CE, Carabin H, Carapetis J, Carmona L, Cella C, Charlson F, Chen H, Cheng AT, Chou D, Chugh SS, Coffeng LE, Colan SD, Colquhoun S, Colson KE, Condon J, Connor MD, Cooper LT, Corriere M, Cortinovis M, de Vaccaro KC, Couser W, Cowie BC, Criqui MH, Cross M, Dabhadkar KC, Dahiya M, Dahodwala N, Damsere-Derry J, Danaei G, Davis A, De Leo D, Degenhardt L, Dellavalle R, Delossantos A, Denenberg J, Derrett S, Des Jarlais DC, Dharmaratne SD, Dherani M, Diaz-Torne C, Dolk H, Dorsey ER, Driscoll T, Duber H, Ebel B, Edmond K, Elbaz A, Ali SE, Erskine H, Erwin PJ, Espindola P, Ewoigbokhan SE, Farzadfar F, Feigin V, Felson DT, Ferrari A, Ferri CP, Fevre EM, Finucane MM, Flaxman S, Flood L, Foreman K, Forouzanfar MH, Fowkes FG, Fransen M, Freeman MK, Gabbe BJ, Gabriel SE, Gakidou E, Ganatra HA, Garcia B, Gaspari F, Gillum RF, Gmel G, Gonzalez-Medina D, Gosselin R, Grainger R, Grant B, Groeger J, Guillemin F, Gunnell D, Gupta R, Haagsma J, Hagan H, Halasa YA, Hall W, Haring D, Haro JM, Harrison JE, Havmoeller R, Hay RJ, Higashi H, Hill C, Hoen B, Hoffman H, Hotez PJ, Hoy D, Huang JJ, Ibeanusi SE, Jacobsen KH, James SL, Jarvis D, Jasrasaria R, Jayaraman S, Johns N, Jonas JB, Karthikeyan G, Kassebaum N, Kawakami N, Keren A, Khoo JP, King CH, Knowlton LM, Kobusingye O, Koranteng A, Krishnamurthi R, Laden F, Laloo R, Laslett LL, Lathlean T, Leasher JL, Lee YY, Leigh J, Levinson D, Lim SS, Limb E, Lin JK, Lipnick M, Lipshultz SE, Liu W, Loane M, Ohno SL, Lyons R, Mabweijano J, MacIntyre MF, Malekzadeh R, Mallinger L, Manivannan S, Marcenes W, March L, Margolis DJ, Marks GB, Marks R, Matsumori A, Matzopoulos R, Mayosi BM, McAnulty JH, McDermott MM, McGill N, McGrath J, Medina-Mora ME, Meltzer M, Mensah GA, Merriman TR, Meyer AC, Miglioli V, Miller M, Miller TR, Mitchell PB, Mock C, Mocumbi AO, Moffitt TE, Mokdad AA, Monasta L, Montico M, Moradi-Lakeh M, Moran A, Morawska L, Mori R, Murdoch ME, Mwaniki MK, Naidoo K, Nair MN, Naldi L, Narayan KM, Nelson PK, Nelson RG, Nevitt MC, Newton CR, Nolte S, Norman P, Norman R, O'Donnell M, O'Hanlon S, Olives C, Omer SB, Ortblad K, Osborne R, Ozgediz D, Page A, Pahari B, Pandian JD, Rivero AP, Patten SB, Pearce N, Padilla RP, Perez-Ruiz F, Perico N, Pesudovs K, Phillips D, Phillips MR, Pierce K, Pion S, Polanczyk GV, Polinder S, Pope CA, 3rd, Popova S, Porrini E, Pourmalek F, Prince M, Pullan RL, Ramaiah KD, Ranganathan D, Razavi H, Regan M, Rehm JT, Rein DB, Remuzzi G, Richardson K, Rivara FP, Roberts T, Robinson C, De Leon FR, Ronfani L, Room R, Rosenfeld LC, Rushton L, Sacco RL, Saha S, Sampson U, Sanchez-Liera L, Sanman E, Schwebel DC, Scott JG, Segui-Gomez M, Shahraz S, Shepard DS, Shin H, Shivakoti R, Singh D, Singh GM, Singh JA, Singleton J, Sleet DA, Sliwa K, Smith E, Smith JL, Stapelberg NJ, Steer A, Steiner T, Stolk WA, Stovner LJ, Sudfeld C, Syed S, Tamburlini G, Tavakkoli M, Taylor HR, Taylor JA, Taylor WJ, Thomas B, Thomson WM, Thurston GD, Tleyjeh IM, Tonelli M, Towbin JA, Truelsen T, Tsilimbaris MK, Ubeda C, Undurraga EA, van der Werf MJ, van Os J, Vavilala MS, Venketasubramanian N, Wang M, Wang W, Watt K, Weatherall DJ, Weinstock MA, Weintraub R, Weisskopf MG, Weissman MM, White RA, Whiteford H, Wiebe N, Wiersma ST, Wilkinson JD, Williams HC, Williams SR, Witt E, Wolfe F, Woolf AD, Wulf S, Yeh PH, Zaidi AK, Zheng ZJ, Zonies D, Lopez AD, AlMazroa MA and Memish ZA. Disability-adjusted life years (DALYs) for 291 diseases and injuries in 21 regions, 1990-2010: A systematic analysis for the Global Burden of Disease Study 2010. *Lancet*. 2012; 380:2197-2223.
2. Duval X, Delahaye F, Alla F, Tattevin P, Obadia JF, Le Moing V, Doco-Lecompte T, Celard M, Poyart C, Strady C, Chirouze C, Bes M, Camba E, Iung B, Selton-Suty C, Hoen B, Group AS. Temporal trends in infective endocarditis in the context of prophylaxis guideline modifications: Three successive population-based surveys. *J Am Coll Cardiol* 2012; 59:1968-1976.
 3. Correa de Sa DD, Tleyjeh IM, Anavekar NS, Schultz JC, Thomas JM, Lahr BD, Bachuwar A, Pazdernik M, Steckelberg JM, Wilson WR, Baddour LM. Epidemiological trends of infective endocarditis: A population-based study in Olmsted County, Minnesota. *Mayo Clin Proc* 2010; 85:422-426.
 4. Federspiel JJ, Stearns SC, Peppercorn AF, Chu VH, Fowler VG, Jr. Increasing US rates of endocarditis with *Staphylococcus aureus*: 1999-2008. *Arch Intern Med* 2012; 172:363-365.
 5. Thuny F, Grisoli D, Cautela J, Riberi A, Raoult D, Habib G. Infective endocarditis: Prevention, diagnosis, and management. *Can J Cardiol* 2014; 30:1046-1057.
 6. Marelli AJ, Mackie AS, Ionescu-Ittu R, Rahme E, Pilote L. Congenital heart disease in the general population: changing prevalence and age distribution. *Circulation* 2007; 115:163-172.
 7. Khairy P, Ionescu-Ittu R, Mackie AS, Abrahamowicz M, Pilote L, Marelli AJ. Changing mortality in congenital heart disease. *J Am Coll Cardiol* 2010; 56:1149-1157.
 8. Habib G, Hoen B, Tornos P, Thuny F, Prendergast B, Vilacosta I, Moreillon P, de Jesus Antunes M, Thilen U, Lekakis J, Lengyel M, Muller L, Naber CK, Nihoyannopoulos P, Moritz A, Zamorano JL, Guidelines ESCCfP. Guidelines on the prevention, diagnosis, and treatment of infective endocarditis (new version 2009): the Task Force on the Prevention, Diagnosis, and Treatment of Infective Endocarditis of the European Society of Cardiology (ESC). Endorsed by the European Society of Clinical Microbiology and Infectious Diseases (ESCMID) and the International Society of Chemotherapy (ISC) for Infection and Cancer. *Eur Heart J* 2009; 30:2369-2413.
 9. van der Meer JT, Thompson J, Valkenburg HA, Michel MF. Epidemiology of bacterial endocarditis in The Netherlands. II. Antecedent procedures and use of prophylaxis. *Arch Intern Med* 1992; 152:1869-1873.
 10. Niwa K, Nakazawa M, Tateno S, Yoshinaga M, Terai M. Infective endocarditis in congenital heart disease: Japanese national collaboration study. *Heart* 2005; 91:795-800.
 11. Li W, Somerville J. Infective endocarditis in the grown-up congenital heart (GUCH) population. *Eur Heart J* 1998; 19:166-173.
 12. Wilson W, Taubert KA, Gewitz M, Lockhart PB, Baddour LM, Levinson M, Bolger A, Cabell CH, Takahashi M, Baltimore RS, Newburger JW, Strom BL, Tani LY, Gerber M, Bonow RO, Pallasch T, Shulman ST, Rowley AH, Burns JC, Ferrieri P, Gardner T, Goff D, Durack DT, American Heart Association Rheumatic Fever E, Kawasaki Disease C, American Heart Association Council on Cardiovascular Disease in the Y, American Heart Association Council on Clinical C, American Heart Association Council on Cardiovascular S, Anesthesia, Quality of C and Outcomes Research Interdisciplinary Working G. Prevention

of infective endocarditis: Guidelines from the American Heart Association: a guideline from the American Heart Association Rheumatic Fever, Endocarditis, and Kawasaki Disease Committee, Council on Cardiovascular Disease in the Young, and the Council on Clinical Cardiology, Council on Cardiovascular Surgery and Anesthesia, and the Quality of Care and Outcomes Research Interdisciplinary Working Group. *Circulation* 2007; 116: 1736–1754.

13. Baltimore RS, Gewitz M, Baddour LM, Beerman LB, Jackson MA, Lockhart PB, Pahl E, Schutze GE, Shulman ST, Willoughby R. Jr., American Heart Association Rheumatic Fever E, Kawasaki Disease Committee of the Council on Cardiovascular Disease in the Y, the Council on C and Stroke N. Infective endocarditis in childhood: 2015 update: A scientific statement from the American Heart Association. *Circulation* 2015; 132: 1487–1515.
14. van der Linde D, Konings EE, Slager MA, Witsenburg M, Helbing WA, Takkenberg JJ, Roos-Hesselink JW. Birth prevalence of congenital heart disease worldwide: A systematic review and meta-analysis. *J Am Coll Cardiol* 2011; 58:2241–7.
15. Warnes CA, Williams RG, Bashore TM, Child JS, Connolly HM, Dearani JA, del Nido P, Fasules JW, Graham TP, Jr., Hijazi ZM, Hunt SA, King ME, Landzberg MJ, Miner PD, Radford MJ, Walsh EP, Webb GD, Smith SC, Jr., Jacobs AK, Adams CD, Anderson JL, Antman EM, Buller CE, Creager MA, Ettinger SM, Halperin JL, Hunt SA, Krumholz HM, Kushner FG, Lytle BW, Nishimura RA, Page RL, Riegel B, Tarkington LG, Yancy CW, American College of C, American Heart Association Task Force on Practice G, American Society of E, Heart Rhythm S, International Society for Adult Congenital Heart D, Society for Cardiovascular a, Interventions and Society of Thoracic S. ACC/AHA 2008 guidelines for the management of adults with congenital heart disease: A report of the American College of Cardiology/American Heart Association Task Force on Practice Guidelines (Writing Committee to Develop Guidelines on the Management of Adults With Congenital Heart Disease). Developed in Collaboration With the American Society of Echocardiography, Heart Rhythm Society, International Society for Adult Congenital Heart Disease, Society for Cardiovascular Angiography and Interventions, and Society of Thoracic Surgeons. *J Am Coll Cardiol* 2008; 52:e143–e263.
16. Mas JL, Derumeaux G, Amarencio P, Arquizan C, Aubry P, Barthelet M, Bertrand B, Brochet E, Cabanes L, Donal E, Dubois-Randé JL, Durand-Zaleski I, Ernande L, Finet G, Fraisse A, Giroud M, Guerin P, Habib G, Juliard JM, Leys D, Lievre M, Lusson JR, Marcon F, Michel P, Moulin T, Mounier-Vehier F, Pierard L, Piot C, Rey C, Rodier G, Roudaut R, Schleich JM, Teiger E, Turc G, Vuillier F, Weimar C, Woimant F, Chatellier G, and Investigators C. close: Closure of patent foramen ovale, oral anticoagulants or antiplatelet therapy to prevent stroke recurrence: Study design. *Int J Stroke* 2016.
17. Leong MC, Uebing A, Gatzoulis MA. Percutaneous patent foramen ovale occlusion: Current evidence and evolving clinical practice. *Int J Cardiol* 2013; 169:238–243.
18. Chessa M, Carminati M, Butera G, Bini RM, Drago M, Rosti L, Giamberti A, Pome G, Bossone E, Frigiola A. Early and late complications associated with transcatheter occlusion of secundum atrial septal defect. *J Am Coll Cardiol* 2002; 39:1061–1065.
19. Du ZD, Hijazi ZM, Kleinman CS, Silverman NH, Larntz K, Amplatz I. Comparison between transcatheter and surgical closure of secundum atrial septal defect in children and adults: Results of a multicenter nonrandomized trial. *J Am Coll Cardiol* 2002; 39:1836–1844.
20. Masura J, Gavora P, Podnar T. Long-term outcome of transcatheter secundum-type atrial septal defect closure using Amplatz septal occluders. *J Am Coll Cardiol* 2005; 45:505–507.
21. Majunke N, Bialkowski J, Wilson N, Szkutnik M, Kusa J, Baranowski A, Heinisch C, Ostermayer S, Wunderlich N, Sievert H. Closure of atrial septal defect with the Amplatz septal occluder in adults. *Am J Cardiol* 2009; 103:550–554.
22. Haas NA, Soetemann DB, Ates I, Baspinar O, Ditkivskyy I, Duke C, Godart F, Lorber A, Oliveira E, Onorato E, Pac F, Promphan W, Riede FT, Roymanee S, Sabiniewicz R, Shebani SO, Sievert H, Tin D, Happel CM. Closure of secundum atrial septal defects by using the occlutech occluder devices in more than 1300 patients: The IRFACODE project: A retrospective case series. *Catheter Cardiovasc Interv* 2016.
23. O’Byrne ML, Glatz AC, Sunderji S, Mathew AE, Goldberg DJ, Dori Y, Rome JJ, Gillespie MJ. Prevalence of deficient retro-aortic rim and its effects on outcomes in device closure of atrial septal defects. *Pediatr Cardiol* 2014; 35:1181–1190.
24. Kutty S, Hazeem AA, Brown K, Danford CJ, Worley SE, Delaney JW, Danford DA, Latson LA. Long-term (5- to 20-year) outcomes after transcatheter or surgical treatment of hemodynamically significant isolated secundum atrial septal defect. *Am J Cardiol* 2012; 109:1348–1352.
25. Butera G, Biondi-Zoccai G, Sangiorgi G, Abella R, Giamberti A, Bussadori C, Sheiban I, Saliba Z, Santoro T, Pelissero G, Carminati M, Frigiola A. Percutaneous versus surgical closure of secundum atrial septal defects: A systematic review and meta-analysis of currently available clinical evidence. *EuroIntervention* 2011; 7:377–385.
26. Delaney JW, Li JS, Rhodes JF. Major complications associated with transcatheter atrial septal occluder implantation: A review of the medical literature and the manufacturer and user facility device experience (MAUDE) database. *Congenit Heart Dis* 2007; 2:256–264.
27. DiBardino DJ, McElhinney DB, Kaza AK, Mayer JE Jr. Analysis of the US Food and Drug Administration Manufacturer and User Facility Device Experience database for adverse events involving Amplatz septal occluder devices and comparison with the Society of Thoracic Surgery congenital cardiac surgery database. *J Thorac Cardiovasc Surg* 2009; 137: 1334–1341.
28. Sievert H, Babic UU, Hausdorf G, Schneider M, Hopp HW, Pfeiffer D, Pfisterer M, Friedli B, Urban P. Transcatheter closure of atrial septal defect and patent foramen ovale with ASDOS device (a multi-institutional European trial). *Am J Cardiol* 1998; 82:1405–1413.
29. Bullock AM, Menahem S, Wilkinson JL. Infective endocarditis on an occluder closing an atrial septal defect. *Cardiol* 1999; 9:65–67.
30. Goldstein JA, Beardslee MA, Xu H, Sundt TM, Lasala JM. Infective endocarditis resulting from CardioSEAL closure of a patent foramen ovale. *Catheter Cardiovasc Interv* 2002; 55:217–220; discussion 221.
31. Calachanis M, Carrieri L, Grimaldi R, Veglio F, Orzan F. Infective endocarditis after transcatheter closure of a patent foramen ovale. *Catheter Cardiovasc Interv* 2004; 63:351–354.
32. Balasundaram RP, Anandarama S, Juneja R, Choudhary SK. Infective endocarditis following implantation of amplatz atrial septal occluder. *Indian Heart J* 2005; 57:167–169.
33. Divchev D, Podewski EK, Mengel M, Meyer GP, Drexler H, Schaefer A. Inflammatory, abscess-forming foreign body reaction mimics a thrombus formation on an atrial septal defect closure device: A commented case report. *Eur J Echocardiogr* 2007; 8:298–302.

34. Slesnick TC, Nugent AW, Fraser CD Jr., Cannon BC. Images in cardiovascular medicine. Incomplete endothelialization and late development of acute bacterial endocarditis after implantation of an Amplatzer septal occluder device. *Circulation* 2008; 117:e326–e327.
35. Zahr F, Katz WE, Toyoda Y, Anderson WD. Late bacterial endocarditis of an amplatzer atrial septal defect occluder device. *Am J Cardiol* 2010; 105:279–280.
36. Doguet F, Leguillou V, Godin M. Infected amplatzer device. *J Card Surg* 2011; 26:75.
37. Verma SK, Tobis JM. Explantation of patent foramen ovale closure devices: A multicenter survey. *JACC Cardiovasc Interv* 2011; 4:579–585.
38. Walpot J, Amsel B, Rodrigus I, Pasteuning WH, Koeman J, Hokken R. Late infective endocarditis of an atrial septal occluder device presenting as a cystic mass. *Echocardiography* 2011; 28:E131–E133.
39. Sadiq M, Kazmi T, Rehman AU, Latif F, Hyder N, Qureshi SA. Device closure of atrial septal defect: Medium-term outcome with special reference to complications. *Cardiol Young* 2012; 22:71–78.
40. Aruni B, Sharifian A, Eryazici P, Herrera CJ. Late bacterial endocarditis of an Amplatzer atrial septal device. *Indian Heart J* 2013; 65:4501.
41. Krantz SB, Lawton JS. Subacute endocarditis of an atrial septal closure device in a patient with a patent foramen ovale. *Ann Thoracic Surg* 2014; 98:1821–1823.
42. Iezzi F, Cini R, Sordini P, Pristipino C. Bacterial endocarditis on transcatheter Amplatzer device. *J Case Rep Practice* 2014; 2:4–5.
43. Jha NK, Kiraly L, Murala JS, Tamas C, Talo H, El Badaoui H, Tofeig M, Mendonca M, Sajwani S, Thomas MA, Al Doory SA, Khan MD. Late endocarditis of Amplatzer atrial septal occluder device in a child. *World J Cardiol* 2015; 7:703–706.
44. Kim DJ, Shim CY, You SC, Lee SH, Hong GR. Late bacterial endocarditis and abscess formation after implantation of an amplatzer septal occluder device. *Circulation* 2015; 131:e536–e538.
45. Thibodeau-Jarry N, Ibrahim R, Ducharme A, Sia YT. Late infection of an atrial septal defect closure device: A possible complication. *Can J Cardiol* 2015; 31:1204 e9–e11.
46. Bialkowski J, Pawlak S, Banaszak P. Incomplete endothelialisation of an Amplatzer Septal Occluder device followed by meningitis and late acute bacterial endocarditis. *Cardiol Young* 2016; 26:808–810.
47. Nguyen AK, Palafox BA, Starr JP, Gates RN, Berdjis F. Endocarditis and incomplete endothelialization 12 years after amplatzer septal occluder deployment. *Tex Heart Inst J* 2016; 43:227–231.
48. Bressieux-Degueldre S, Sekarski N, Di Bernardo S. Fungal endocarditis after hybrid periventricular closure of muscular ventricular septal defect by Amplatzer occluder in a child. *Circulation* 2015; 131:e339–e340.
49. Tuncer M, Ekim H, Gunes Y, Guntekin U. Atrial septal defect presenting with *Brucella endocarditis*. *Circ J* 2008; 72:2096–2097.
50. Stoica L, Tinica G, Gradinariu G, Butcovan D, Macovei L. Patch abscess after a closure of an atrial septal defect. *Eur Heart J Cardiovasc Imaging* 2014; 15:179.
51. Lock JE, Rome JJ, Davis R, Van Praagh S, Perry SB, Van Praagh R, Keane JF. Transcatheter closure of atrial septal defects. Experimental studies. *Circulation* 1989; 79:1091–1099.
52. Naik RJ, Patel NR, Wang M, Shah NC. Infective endocarditis prophylaxis: Current practice trend among paediatric cardiologists: Are we following the 2007 guidelines? *Cardiol Young* 2015:1–7.
53. Bialkowski J, Pawlak S, Banaszak P. Incomplete endothelialisation of an Amplatzer Septal Occluder device followed by meningitis and late acute bacterial endocarditis. *Cardiol Young* 2015; 1–3.