



HAL
open science

RV function improvement following nitric oxide inhalation demonstrated by gated blood pool SPECT in a patient with primary pulmonary hypertension

Fayçal Ben Bouallègue, Fabien Vauchot, Aurélie Bourdon, Meriem Benkiran, Clement Boissin, Jérémy Charriot, Arnaud Bourdin, Denis Mariano-Goulart

► To cite this version:

Fayçal Ben Bouallègue, Fabien Vauchot, Aurélie Bourdon, Meriem Benkiran, Clement Boissin, et al.. RV function improvement following nitric oxide inhalation demonstrated by gated blood pool SPECT in a patient with primary pulmonary hypertension. *Journal of Nuclear Cardiology*, 2018, 10.1007/s12350-017-1171-x . hal-01789411

HAL Id: hal-01789411

<https://hal.umontpellier.fr/hal-01789411>

Submitted on 2 Jan 2020

HAL is a multi-disciplinary open access archive for the deposit and dissemination of scientific research documents, whether they are published or not. The documents may come from teaching and research institutions in France or abroad, or from public or private research centers.

L'archive ouverte pluridisciplinaire **HAL**, est destinée au dépôt et à la diffusion de documents scientifiques de niveau recherche, publiés ou non, émanant des établissements d'enseignement et de recherche français ou étrangers, des laboratoires publics ou privés.

RV function improvement following nitric oxide inhalation demonstrated by gated blood pool SPECT in a patient with primary pulmonary hypertension

Fayçal Ben Bouallègue, MD, PhD^{a,c}, Fabien Vauchot, MD, PhD,^a
Aurélie Bourdon, MD,^a Meriem Benkiran, MD,^a Clément Boissin, MD,^b
Jérémy Charriot, MD,^b Arnaud Bourdin, MD, PhD,^{b,c} and Denis Mariano-Goulart,
MD, PhD^{a,c}

^a Nuclear Medicine Department, Montpellier University Hospital, Montpellier, France

^b Pneumology Department, Montpellier University Hospital, Montpellier, France

^c PhyMedExp, INSERM, CNRS, Montpellier University, Montpellier, France

A 30-year-old woman with a history of dyspnoea and recurrent syncope was diagnosed with primary pulmonary hypertension (PPH). Right cardiac catheterization demonstrated pre-capillary PH with elevated mean pulmonary arterial pressure at 52 mmHg, low occlusive pulmonary arterial pressure at 5 mmHg, and elevated pulmonary vascular resistance at 638 d.s.cm^{-5} . Pulmonary arterial pressure and resistance were normalized after nitric oxide (NO) inhalation. Calcium blocker medication (nifedipine 150 mg·day) was initiated.

The patient was explored using gated blood pool SPECT at baseline and after NO inhalation (10 ppm).

SPECT data were post-processed using in-house dedicated software (TomPool¹). Figure 1 shows left (LV, in red) and right ventricle (RV, in blue) time-volume curves fitted using a deformable reference curve model. Figure 2 displays bi-ventricular 3D surface rendering and polar plots of local ejection fraction (EF). Baseline acquisition showed normal LV function. Global RV EF was measured at 59%, within the normal range ($56\% \pm 8\%$). There was an RV annular peri-apical area of moderate hypokinesia. After NO inhalation, LV function was globally stable, whereas global RV EF increased to 69%. Segmental contractility maps showed a clear improvement in the RV free wall contractility

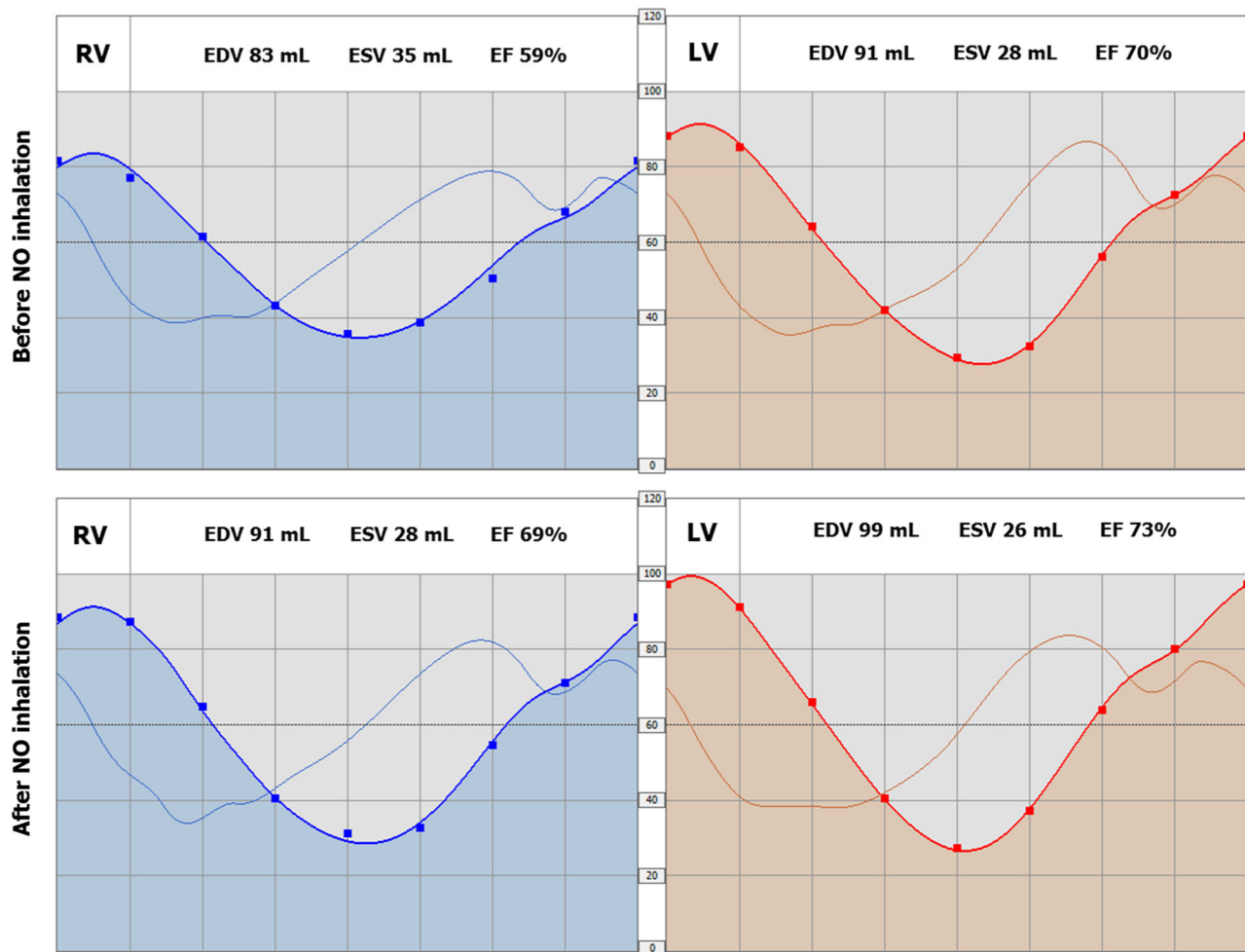


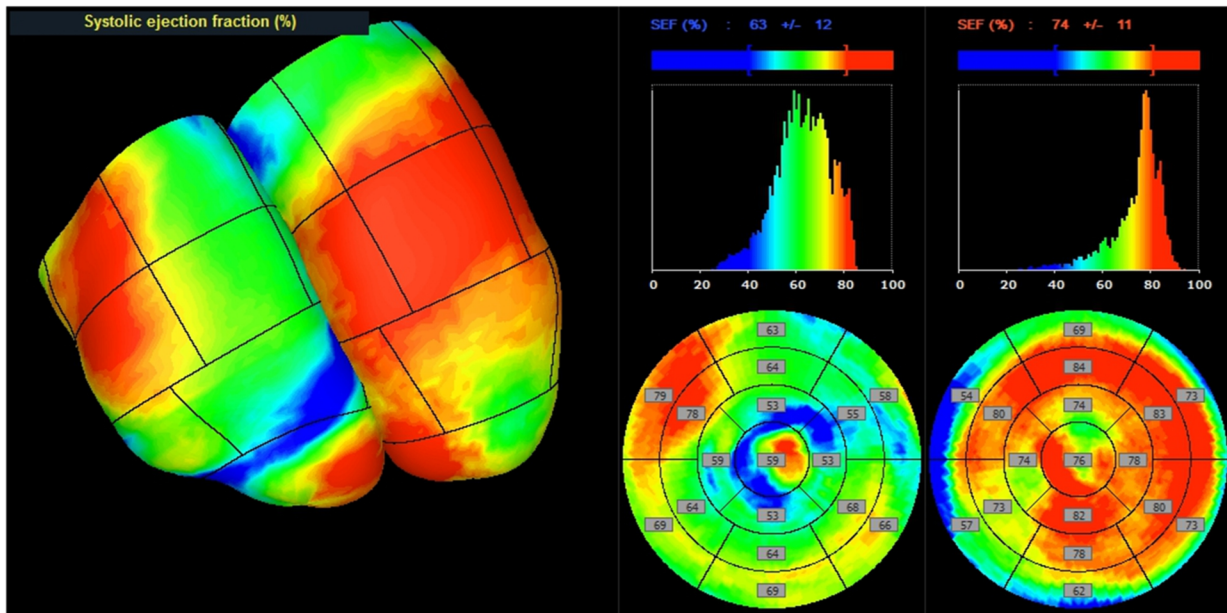
Figure 1. Right (blue) and left (red) ventricle time-volume curves before (top) and after (bottom) NO inhalation showing similar LV EF and significantly improved RV EF after NO inhalation.

with local EFs increasing from $\sim 80\%$ to $\sim 90\%$ in the antero-lateral wall and from $\sim 65\%$ to $\sim 75\%$ in the infero-lateral wall. The RV annular peri-apical hypokinesia remained relatively unchanged.

Inhaled NO is recommended to assess pulmonary vasodilator reserve in PPH and is known to accurately

predict the acute haemodynamic response to nifedipine.^{2,3} Gated blood pool SPECT is a robust and non-invasive method for LV and RV function analysis^{1,4} and should provide a reliable alternative to RV catheterization for the assessment of haemodynamic response to inhaled NO in PPH.

Before NO inhalation



After NO inhalation

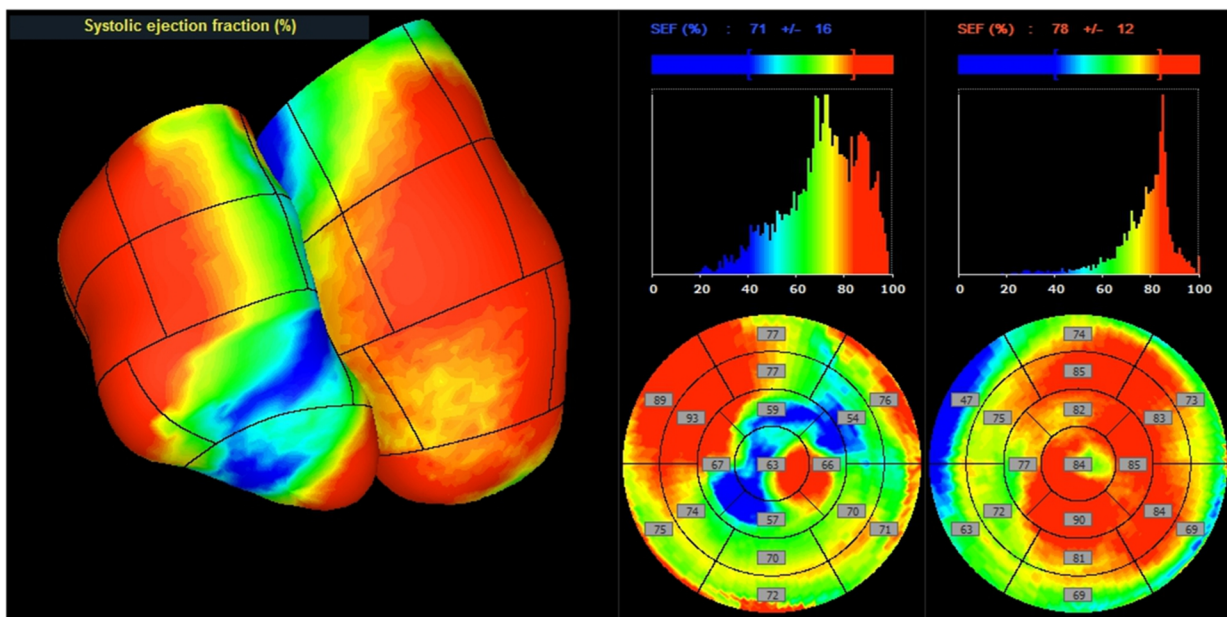


Figure 2. Bi-ventricular 3D surface rendering (left panel) and polar plots (right panel: RV on the right, LV on the left) of local ejection fraction before (top) and after (bottom) NO inhalation. Compared to baseline, NO inhalation induced an improvement in the RV free wall contractility. An RV annular peri-apical hypokinesia is visible at both times of the examination.

References

- Sibille L, Ben Bouallègue F, Bourdon A, Micheau A, Vernhet-Kovacsik H, Mariano-Goulart D. Comparative values of gated blood-pool SPECT and CMR for ejection fraction and volume estimation. *Nucl Med Commun.* 2011;32:121–8.
- Ricciardi MJ, Knight BP, Martinez FJ, Rubenfire M. Inhaled nitric oxide in primary pulmonary hypertension: a safe and effective agent

for predicting response to nifedipine. *J Am Coll Cardiol.* 1998;32:1068–73.

- Tonelli AR, Haserodt S, Aytekin M, Dweik RA. Nitric oxide deficiency in pulmonary hypertension: Pathobiology and implications for therapy. *Pulm Circ.* 2013;3:20–30.
- Dercle L, Ouali M, Pascal P, Giraudmaillet T, Chisin R, Lairez O, et al. Gated blood pool SPECT: The estimation of right ventricular volume and function is algorithm dependent in a clinical setting. *J Nucl Cardiol.* 2015;22:483–92.