



HAL
open science

Fungal complications after Candida preservation fluid contamination in liver transplant recipients

Eric Levesque, Catherine Paugam-Burtz, Faouzi Saliba, Linda Khoy-Ear, Jean-Claude Merle, Boris Jung, Laurent Stecken, Martine Ferrandiere, Liliana Mihaila, Françoise Botterel

► **To cite this version:**

Eric Levesque, Catherine Paugam-Burtz, Faouzi Saliba, Linda Khoy-Ear, Jean-Claude Merle, et al.. Fungal complications after Candida preservation fluid contamination in liver transplant recipients. *Transplant International*, 2015, 28 (11), pp.1308 - 1316. 10.1111/tri.12633 . hal-01761272

HAL Id: hal-01761272

<https://hal.umontpellier.fr/hal-01761272v1>

Submitted on 3 Feb 2020

HAL is a multi-disciplinary open access archive for the deposit and dissemination of scientific research documents, whether they are published or not. The documents may come from teaching and research institutions in France or abroad, or from public or private research centers.

L'archive ouverte pluridisciplinaire **HAL**, est destinée au dépôt et à la diffusion de documents scientifiques de niveau recherche, publiés ou non, émanant des établissements d'enseignement et de recherche français ou étrangers, des laboratoires publics ou privés.

Fungal complications after *Candida* preservation fluid contamination in liver transplant recipients

Eric Levesque,¹ Catherine Paugam-Burtz,^{2,3,4} Faouzi Saliba,⁵ Linda Khoy-Ear,² Jean-Claude Merle,¹ Boris Jung,^{6,7} Laurent Stecken,⁸ Martine Ferrandiere,⁹ Liliana Mihaila¹⁰ and Francoise Botterel¹¹

1 Anesthesiology Department & Intensive Care - Liver ICU, AP-HP GH Henri Mondor, Créteil, France

2 Intensive Care & Anesthesiology Department, AP-HP, Hôpital Beaujon, Hôpitaux Universitaires Paris Nord Val de Seine, Paris, France

3 Sorbonne Paris Cité, Univ Paris Diderot, Paris, France

4 INSERM U773, CRB3, Paris, France

5 Hepato-Biliary Centre – Liver ICU, Hôpital Paul Brousse, Villejuif, France

6 Department of Critical Care Medicine and Anesthesiology, Saint Eloi Teaching Hospital, Montpellier, France

7 INSERM U-1046, University Montpellier I, Montpellier II, Montpellier, France

8 Intensive Care & Anesthesiology Department, CHU Bordeaux, Bordeaux, France

9 Intensive Care & Anesthesiology Department, SAMU, CHU Tours, Tours, France

10 Microbiology Unit, G.H. Kremlin-Bicêtre, Kremlin-Bicêtre, France

11 Mycology Unit – Microbiology Department, DHU VIC, EA Dynamyc UPEC-ENVA-GH Henri Mondor, Créteil, France

Keywords

aneurysm, *Candida*, fungal infection, liver transplantation, preservation fluid.

Correspondence

Dr. Eric Levesque, MD, Anesthesiology Department & Intensive Care - Liver ICU, Hôpital Henri Mondor, 51 avenue du Maréchal de Lattre de Tassigny, 94010 Créteil, France.

Tel.: 00 33 1 49 81 21 11/36449;

fax: 00 33 1 45 17 80 18;

e-mail: eric.levesque@hmn.aphp.fr

Conflicts of interest

The authors have declared no conflicts of interest.

Summary

Donor-derived fungal infections can be associated with severe complications in transplant recipients. Donor-derived candidiasis has been described in kidney transplant recipients where contamination of the preservation fluid (PF) was a commonly proposed source. In liver transplantation, these fungal infections have been less explored. The aim of this study was therefore to determine the incidence and clinical relevance of *Candida* contamination of preservation fluid in the context of liver transplantation. A 5-year (2008–2012) retrospective multicentre study involving six French liver transplantation centers was performed to determine the incidence of *Candida* PF contamination. Postoperative clinical features, outcomes in recipients, and risk factors for *Candida*-related complications of liver transplantation were studied. *Candida* sp. was isolated from 28 of 2107 preservation fluid samples (1.33%). *Candida albicans* was the most common yeast ($n = 18$, 64%). Twenty-two recipients (78.5%) received antifungal therapy (echinocandins in 68%) for 7–37 days. Eight patients developed yeast-related complications (28.6%) including hepatic artery aneurysms ($n = 6$) and *Candida* peritonitis ($n = 2$). The 1-year mortality rate among patients after a yeast-related complication was 62.5%. The incidence of *Candida* PF contamination was low, but was associated with dramatic postoperative complications and high mortality. Close radiological follow-up may enable early recognition of the arterial complications associated with PF contamination by *Candida*.

Introduction

Infectious complications represent a major cause of morbidity and mortality following solid organ transplantation. Donor-derived infections are one possible source of these infections in recipients. Among these, contamination of the preservation fluid (PF) used for the graft

may be one of the mechanisms underlying such donor-derived infections.

Bacterial contamination of the PF has been reported to occur in 9.5–48% of cases following liver transplantation (LT) [1–3]. Yeast contamination of PF after liver transplantation (LT) has been poorly described but seems to be less frequent, occurring in between 0.4 and 4.1% of cases [1,4].

In the renal transplantation setting, *Candida* sp. contamination of the PF has been associated with dramatic postoperative complications, which have even been fatal. Such cases mainly concern mycotic arteritis related to *Candida* sp. as a consequence of a hematogenous spread of fungi to the arterial wall, leading to the destruction of vascular structures [5,6]. Recently, two cases after LT have been reported on patients who developed mycotic hepatic arteritis (aneurysm) associated with *Candida albicans* contamination of PF [7,8]. The paucity of data mainly related to cases or small center study was therefore the reason for this study. Our objective was to assess the incidence of fungal contamination of PF and its clinical consequences with respect to postoperative outcomes following LT in a large multicenter study.

Patients and methods

Study design

This was a retrospective multicenter study (involving six French liver transplantation centers) with the purpose of recording all cases of PF infection by *Candida* spp. between January 2008 and December 2012. According to the French law, the need for informed consent was waived. Conduct of the study was nevertheless approved by the Hospital's Ethics Committee, and database has been declared to the Commission Nationale Informatique et Liberté (no. 1699340).

Procedures

Organ procurement procedures were similar in the six centers during the study period in accordance with the guidelines of the French Transplantation Agency (Agence de Biomedecine) [9].

According to the REMIC (Clinical Microbiology guidelines in France), microbiological culture of PF is mandatory. Briefly, samples of the PF (5–10 mL) were centrifuged. Some of the pellets were used for a wet-mounted observation, and some (1 mL) were cultured on a fungal chromogenic medium at 37 °C for 5 days. *Candida albicans* was identified in 48 h, and for the others *Candida* species, several methods were used for specific identification, depending on the protocols applicable in each center.

Data collections

Microbiological charts of each center were reviewed for PF contamination by yeasts. Variables concerning the donor, procurement procedure, and the graft were collected. This included donor age, gender, biological liver parameters (serum aspartate transaminase (AST) concentration, serum alanine transaminase (ALT) level, total bilirubin (T-Bili)

and gamma glutamyl transpeptidase (GGT)), length of intensive care unit (ICU) stay, antibiotic administration, and cause of death. Variables collected concerning the graft were of cold ischemia time, type of PF, and any problems encountered during the procurement. These donor data were used to calculate the Donor Risk Index (DRI) as described by Feng *et al.* [10].

Variables associated with the recipient were collected from their medical records: age, gender, liver disease, MELD score at LT, surgical and anesthesia parameters, postoperative outcomes, antibiotics and fungal therapy (including prophylactic antifungal therapy), and immunosuppressive therapy. Graft and recipient outcomes were collected with respect to all transplanted patients during the study period. The clinical course of recipients was followed for a minimum of 1 year after liver transplantation.

In liver transplant recipients without yeast PF contamination, rates of candidemia and hepatic artery complications were recorded.

Complications were classified using the method of Dindo *et al.* [11], a grading system based on the treatment needed to manage the complication. Grade I represents any deviation from the normal postoperative course without the need for pharmacologic or invasive intervention. Grade II requires pharmacologic or blood transfusion therapy. Grade III requires invasive intervention with or without general anesthesia. Grade IV is a life-threatening complication involving single- or multiorgan dysfunction. Grade V is death.

Prophylactic antifungal therapy

As part of usual care in all the centers, patients considered at risk for invasive fungal infections received a antifungal prophylaxis [12] (Fig. 1). Risk factors of invasive fungal infections (IFI) are re-transplantation, renal failure, creatinine clearance < 50 ml/min or requiring replacement therapy, fulminant hepatic failure, primary nonfunction, patients receiving thymoglobulin as an immunosuppressive agent, complicated or repeat surgery, recipients with a MELD score prior to LT > 30, more than 40 per-operative transfusions of blood products, and biliary-digestive anastomosis or yeast contamination of the organ PF. According to each center, prophylactic antifungal treatment could require the use of caspofungin at a dose of 70 mg for the first day and then 50 mg per day (or 70 mg per day if the recipient weight was > 80 kg) or micafungin 100 mg per day, or fluconazole 400 mg per day during 2–4 weeks.

Statistical analysis

To compare patients who did or did not develop yeast-related complications (mycotic arteritis and *Candida*

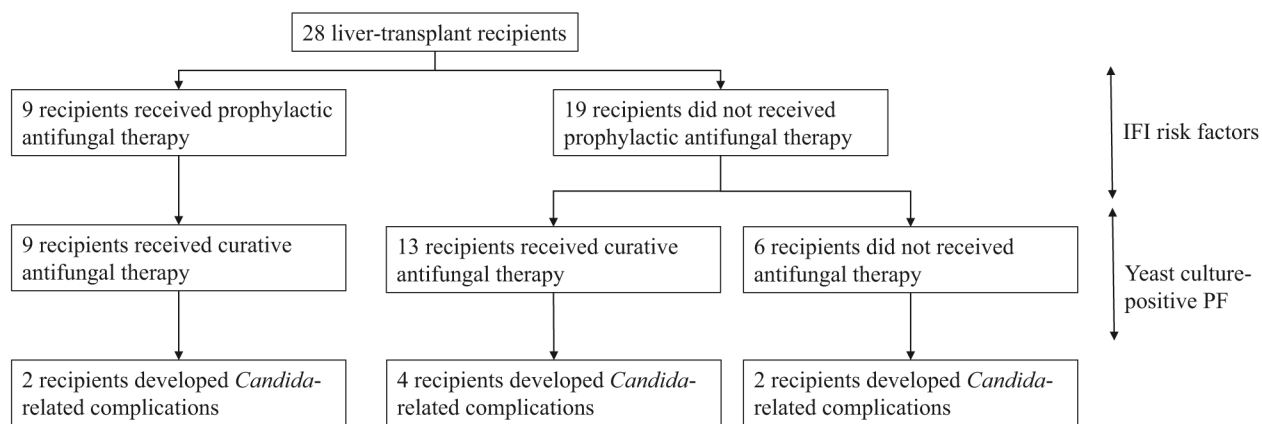


Figure 1 Prophylactic and curative antifungal repartition of patients and *Candida* related complications. IFI, Invasive fungal infection; PF, preservation fluid.

peritonitis), a univariate analysis was carried out using Mann–Whitney and Fischer’s exact tests or the Cramer test for continuous or categorical variables as appropriate. Statistical analyses were performed using JMP 9.0, SAS Institute Inc., Cary, NC, USA. A *P* value lower than 0.05 was considered to be statistically significant. Results are expressed as median [range].

Results

During the study period, 2107 LT were performed in the six centers. Among these, PF microbiological cultures were positive for fungal agents in 28 cases (1.33%). The fungi species included *Candida albicans* (*n* = 16), *Candida glabrata* (*n* = 8), *Candida lusitaniae* (*n* = 2), *Candida kefyr* (*n* = 1), *Candida norvegensis* (*n* = 1), *Candida tropicalis* (*n* = 1), and *Candida* spp. (*n* = 1). Two PF were contaminated with two types of *Candida* (*C. albicans* + *C. glabrata* and *C. albicans* + *C. norvegensis*). In 11 cases (39%), bacterial contamination was associated with the fungal contamination. The most frequent pathogens were Gram-negative microorganisms mainly from *Enterobacteriaceae* family (in 8/11 patients (72%)). The other organisms were Gram-positive cocci (coagulase-negative staphylococci, enterococci, and *Streptococcus parasanguis*).

Liver donors

The characteristics of the donors with positive PF are shown in Table 1. The median age was 56 years [19–88 years], with a gender distribution of 16 males/12 females (sex ratio 1.3). The DRI was 1.81 [1.08–2.65]. Nineteen donors had received broad-spectrum antibacterial agents during their stay in ICU for a suspected (*n* = 14) or documented (*n* = 5) pneumonia. No candidemia, candiduria, or *Candida* peritonitis was reported in their medicals reco-

rd. Only one donor (no. 28) had tracheal aspiration with *C. albicans*. None had received antifungal therapy.

A multiorgan procurement including the small intestine was also performed in one patient. During procurement, a pre-existing digestive tract breach was diagnosed in one patient and procurement was responsible for digestive tract breach in two donors.

Liver recipients

The characteristics and underlying liver diseases concerning the 28 patients who received a liver graft with yeast culture-positive PF are shown in Table 2. No recipient had a presumed or confirmed invasive fungal infection before liver transplantation.

Eight patients (28.6%) developed Grade III *Candida*-related complications, that is, mycotic arteritis or *Candida* peritonitis after PF contamination. Among them, six patients (patients 1, 6, 10, 12, 20, 28) developed a hepatic artery aneurysm at a median of 45 days [range: 22–180] after transplantation. None of these patients had risks factors of hepatic artery complications such as bile leak, hepatic artery reconstruction, or bacteremia. In three patients (1, 12, and 28), the aneurysm was revealed by a hemorrhagic shock with rupture of the hepatic artery, leading to death after prolonged intensive care. The aneurysms were cultured in two cases (patients 1 and 12), which revealed a *C. albicans*. The *C. albicans* could not be compared by genotyping with the *C. albicans* isolated from PF because these samples were not stored. In three other cases (patients 6, 10, 20), radiological examination revealed the aneurysms at 30, 35, and 180 days after transplantation. Two patients were treated by endovascular intervention, with exclusion of the aneurysm used a coated stent (patients 10 and 20). Despite this treatment, the patient 20 died from rupture

Table 1. Characteristics of the 28 donors for whom *Candida* spp. was found in the preservation fluid.

Number donor	Age/ Gender	Origin of death	DRI	ICU stay	Antibiotic	Preservation fluid
1	88/M	CVA	2.43	2	<i>Ofi</i>	IGL-1
2	40/M	HI	1.54	2	<i>Cef</i>	UW
3	57/M	CVA	1.81	6	<i>Cef + Met</i>	IGL-1
4	35/M	Anoxia	1.39	2	<i>Am-Cl</i>	UW
5	83/M	CVA	2.48	2	<i>/</i>	Celsior
6	75/M	HI	1.83	3	<i>Am-Cl</i>	Celsior
7	64/F	CVA	1.96	1	<i>Am-Cl</i>	IGL-1
8	52/F	HI	1.73	5	<i>Pi-Tz</i>	IGL-1
9	48/M	Anoxia	1.62	4	<i>Cef + Am</i>	UW
10	50/F	CVA	1.61	6	<i>Cef</i>	IGL-1
11	81/F	CVA	2.43	1	<i>/</i>	IGL-1
12	19/M	Anoxia	1.26	2	<i>Am-Cl</i>	Celsior
13	60/F	Anoxia	1.91	3	<i>Am-Cl</i>	IGL-1
14	27/F	Anoxia	1.20	1	<i>/</i>	IGL-1
15	55/F	Anoxia	1.82	1	<i>Am-Cl</i>	Celsior
16	71/F	CVA	2.12	1	<i>/</i>	IGL-1
17	30/M	CVA	1.27	3	<i>/</i>	IGL-1
18	42/F	CVA	2.65	1	<i>/</i>	IGL-1
19	68/M	CVA	2.15	3	<i>Am-Cl</i>	UW
20	75/M	CVA	2.20	3	<i>Am-Cl</i>	IGL-1
21	72/M	HI	1.71	1	<i>/</i>	UW
22	43/F	CVA	1.47	1	<i>/</i>	IGL-1
23	37/M	CVA	1.08	5	<i>/</i>	UW
24	79/M	HI	1.85	1	<i>Am-Cl</i>	UW
25	48/M	CVA	1.29	10	<i>Pi-Tz + Cip</i>	Celsior
26	50/F	HI	1.73	16	<i>Am-Cl</i>	IGL-1
27	63/M	CVA	2.25	12	<i>Cef</i>	IGL-1
28	79/F	CVA	2.43	3	<i>Lev + Met</i>	IGL-1

DRI, Donor Risk Index; ICU, intensive care unit; HI, head injury; CVA, cerebrovascular accident; IGL-1, Institut Georges Lopez-1 solution; UW, University of Wisconsin solution; Am-Cl, amoxicillin–clavulanic acid; Lev, levofloxacin; Met, metronidazole; Cef, cefotaxime; Pi-Tz, piperacillin–tazobactam; Cip, ciprofloxacin; Am, amikacin; Ofi, ofloxacin.

of the hepatic artery. The other (patient 10) was still alive 28 months later. The patient 6 had a close radiological follow-up, and 15 months later, no complication had occurred. The last two patients suffered from postoperative *Candida* peritonitis which was diagnosed at postoperative days (POD) 9 and 18, with the isolation of *C. glabrata* as in PF. Unfortunately, no molecular genotyping was performed because isolates of PF have not been kept. One patient (patient 15) died of multiorgan failure 5 months after the peritonitis. The second (patient 27) was still alive 27 months after liver transplantation without having experienced any other complications.

During their management, several cultures (blood, peritoneal fluid) were performed in each of recipients. However, only in the two patients with *Candida* peritonitis (patients 15 and 27) has *C. glabrata* been isolated before the re-operation in the peritoneal fluid drainage.

In the same period, the incidence of candidemia in the recipients in whom the preservation fluid was culture negative for yeast was 1.8% (38/2079 patients) without significant differences between centers. Eight cases of hemorrhagic shock related to rupture of the hepatic artery have been recorded in a subgroup of the cohort (1276 patients in three centers, 0.6%).

Antifungal therapy

Nine of 28 patients (32%) received a prophylactic antifungal therapy and were initiated before the culture results concerning PF contamination became available (Fig. 1). This prophylactic antifungal therapy is becoming a curative treatment after the mycological results. Among the eight patients with *Candida*-related complications, patients 12 and 15 had risk factors of fungal infections (primary nonfunction as LT etiology, more than 40 per operator transfusion blood products and bilio-digestive anastomosis for the patient 12 and acute liver failure and a MELD score superior to 40 for patient 15) and they both received antifungal prophylactic treatment from the first postoperative day. The other patients showed no risk factor for fungal infection. Among the patients who did not develop candidiasis complication, seven patients received antifungal prophylaxis for several reasons: MELD score > 30 (patients 3 and 19), primary nonfunction (patient 16), renal failure requiring replacement therapy (patients 23 and 25), and biliary-digestive anastomosis (patients 7 and 21).

In total, 22 patients received curative treatment with antifungal drugs. The choice of antifungal agents was determined empirically ($n = 13$) or in accordance with a protocol used to determine antifungal prophylaxis ($n = 9$), which was subsequently modified after the results of antifungal drug susceptibility tests ($n = 5$). The duration of antifungal therapy ranged from 7 to 37 days.

Despite PF *Candida* being positive, six recipients did not receive a curative antifungal therapy.

Outcomes

The median follow-up period was 27 months (range: 0–71 months). Survival rates at 6 months and 1 year after LT were 79% (22/28) and 75% (21/28), respectively, in patients with yeast PF contamination and 84% (1745/2079) and 81% (1683/2079) in patients without yeast PF contamination ($P = 0.44$ and 0.42 , respectively). Graft survival rates at 6 months and 1 year were 75% (21/28) and 71% (20/28), respectively.

In patients experiencing yeast-related complications, 1-year patient survival was 37.5% (3/8) versus 90% (18/20) in patients without complications ($P = 0.009$). The

Table 2. Characteristics, underlying liver diseases, complications and outcome of the 28 patients who received a liver transplant with culture-positive PF.

Number recipient	Age/Gender	LT origin	MELD score	PF bacteriological cultures	PF mycological cultures	Antifungal treatment	Start date	Duration of antifungal treatment (days)	Clinical presentation of complications	Delay after LT (days)	Outcome	Duration of follow-up (days)
1	65/M	HCC/NASH	11	<i>M. morganii</i>	<i>C. albicans</i>	Fluconazole	POD 5	10	Aneurysm/hemorrhagic shock/artery hepatic rupture	22	Death	60
2	60/M	HCC/alcohol	16	/	<i>C. glabrata</i>	No	/	/			Alive	2130
3	50/M	HCC/alcohol	40	<i>Enterococcus sp.</i>	<i>C. lusitanae</i>	Caspofungin	POD 1	35			Alive	1560
4	62/M	HCV	23	/	<i>C. albicans</i>	Caspofungin	POD 1	20			Alive	1080
5	65/F	Alcohol	20	/	<i>C. albicans</i>	Fluconazole	POD 3	16			Alive	660
6	64/M	HCC/alcohol	11	<i>E. coli</i>	<i>C. glabrata</i>	Caspofungin	POD 2	20	Aneurysm hepatic artery/no complication	180	Alive	450
7	65/M	HCC/alcohol	10	<i>H. alvei</i>	<i>C. albicans</i>	Fluconazole	POD 1	15			Alive	450
8	55/F	HCC/HCV	9	/	<i>C. glabrata</i>	No	/	/			Alive	1320
9	64/M	HCV	8	/	<i>C. lusitanae</i>	Micafungin	POD 2	18			Alive	1200
10	33/M	Autoimmune disease	28	/	<i>C. glabrata</i>	Caspofungin	POD 1	7	Aneurysm hepatic artery, angioplasty + stent	31	Alive	840
11	59/M	Alcohol	17	/	<i>C. tropicalis</i>	Micafungin	POD 2	20			Death	420
12	55/M	PNF	20	/	<i>C. albicans</i> + <i>C. norvegensis</i>	Micafungin	POD 1	36	Aneurysm/hemorrhagic shock/artery hepatic rupture	60	Death	180
13	51/M	HCC/HCV	16	<i>E. coli</i>	<i>C. albicans</i>	Micafungin	POD 2	20			Alive	900
14	56/M	HCC/alcohol	10	<i>S. parasanguis</i>	<i>C. albicans</i>	Fluconazole	POD 3	14			Alive	900
15	37/M	Acute liver failure	40	<i>S. marcescens</i>	<i>C. glabrata</i>	Fluconazole and then caspofungin	POD 0 POD 3	17	<i>Candida</i> peritonitis	18	Death	180
16	44/M	Alcohol/HBV	24	/	<i>C. albicans</i>	Caspofungin then voriconazole	POD 0 POD 4	15			Alive	1380
17	58/F	HCV	40	/	<i>C. glabrata</i>	No	/	/			Death	2
18	66/M	HCC/alcohol + HCV	10	<i>E. cloacae</i>	<i>C. albicans</i>	Fluconazole	POD 2	12			Death	300
19	41/M	Alcohol	32	<i>C. koseri</i>	<i>C. albicans</i>	Caspofungin	POD 1	14			Alive	390

Table 2. continued

Number recipient	Age/Gender	LT origin	MELD score	PF bacteriological cultures	PF mycological cultures	Antifungal treatment	Start date	Duration of antifungal treatment (days)	Clinical presentation of complications	Delay after LT (days)	Outcome	Duration of follow-up (days)
20	52/M	HCV	16	<i>E. coli</i>	<i>C. kefyr</i>	Fluconazole	POD 2	14	Aneurysm hepatic artery/angioplasty + stent	35	Death	120
21	49/M	HCV + HBV	9	/	<i>C. glabrata</i> + <i>C. albicans</i>	Fluconazole and then caspofungin and voriconazole	POD 0 POD 1	23			Alive	1500
22	63/F	Autoimmune	40	/	<i>C. albicans</i>	Fluconazole	POD 3	15			Alive	1170
23	60/M	Alcohol	21	/	<i>C. albicans</i>	Caspofungin and then fluconazole	POD 0 POD 4	37			Death	390
24	21/F	Wilson disease	9	/	<i>C. albicans</i>	Caspofungin and then fluconazole	POD 5 POD 8	19			Alive	1260
25	64/M	Alcohol	29	/	<i>C. albicans</i>	Caspofungin and then fluconazole	POD 1 POD 10	25			Alive	1080
26	49/F	Alcohol	29	NCS	<i>Candida</i> spp.	No	/	/			Alive	1590
27	69/M	Alcohol	36	/	<i>C. glabrata</i>	No	/	/	<i>Candida</i> peritonitis	9	Alive	810
28	55/F	HCC/Alcohol + HCV	11	/	<i>C. albicans</i>	No	/	/	Aneurysm/hemorrhagic shock/artery hepatic rupture	55	Death	120

LT, liver transplantation; MELD, model for end-stage liver disease; HCC, hepatocellular carcinoma; HCV, hepatitis C virus; HBV, hepatitis B virus; PNF, primary non function; NASH, nonalcoholic steatohepatitis; POD, postoperative day; NCS, negative coagulase *Staphylococcus*.

duration of hospital stay of patients who developed candidiasis complications was statistically significantly longer than those who were not affected by candidiasis [95 (30–181) vs. 30 (1–1215) days, $P = 0.002$, respectively].

Risk factors for yeast-related postoperative complications

The clinical characteristics of the recipients who did or did not develop candidiasis complications after yeast contamination of PF are similar. There were no significant differences between the two groups in terms of donor or recipient variables, intra-operative parameters, or antifungal therapy. Care should, however, be taken of a greater incidence of candidiasis complications when the donor received antibiotics during ICU stay and during procurement [100% (8/8) in the group of patients who developed candidiasis complications vs. 55% (11/20) in the group of patients who did not develop candidiasis complication, $P = 0.02$].

All patients received similar postoperative intensive care with a routine triple immunosuppressive regimen including corticosteroids, mycophenolate mofetil, and FK506 (tacrolimus) ($n = 26$) or cyclosporine ($n = 2$, patients 8 and 9). In addition, 15 patients received basiliximab (day 1 and day 4), without difference between the patients who did or did not develop candidiasis complications after yeast contamination of PF (62.5% vs. 50%, $P = 0.55$). One patient (patient 11) received ATG during the induction phase of immunosuppression after LT.

Twenty-two patients (78.5%) received a post-LT antifungal therapy for various reasons (see above). There were no significant differences, in the use of antifungal treatment, at the time of initiation and of duration of antifungal treatment between patients who did or did not develop candidiasis complications. Thus, the delayed or inappropriate treatment does not appear as a risk factor of candidiasis complications in patients with *Candida* contamination of preservation fluid.

Discussion

To our knowledge, this is the first large multicenter study to have specifically addressed the impact of a yeast contamination of PF in the context of LT. In this study, which included more than 2000 LT, we showed that a contamination of PF by *Candida* species occurred in 1.33% of cases (28/2107). This contamination was associated with a high rate of severe complications (8/28, 28.6%) that caused postoperative morbidity and mortality. No specific risk factors for postoperative yeast-related complications following PF contamination could be determined.

The incidence of yeast contamination after LT reported here agrees with findings in the literature which shows an

incidence of 0.4–4.1% of PF contamination [1,4,13]. This low incidence can be in part related to delayed or missed diagnoses owing to the lack of sensitivity and specificity of actual diagnostic tests. The early positivity and excellent sensibility of BG assay, which we observed in a previous study in a population of liver transplants [14], suggest that the detection of BG in the PF may help the diagnosis of PF yeast contamination and support the decision to promptly start pre-emptive antifungal therapy. However, this test did not exist at the period of our study. This fungal contamination is thought to be linked to exogenous contamination which might occur at different phases during the transplantation process: (i) contamination of PF by the graft, especially from polytrauma donors, or (ii) liver procurement which frequently involves digestive tract breach, particularly during multiorgan procurement [15,16]. However, the design of our study did not enable the identification of risk factors for yeast contamination. Interestingly, three cases in the present study were associated with digestive tract breach at the time of procurement and one case occurred during multivisceral bowel procurement. This suggests that these issues need to be addressed specifically and the physicians in charge of the recipient should be aware of them so that they can consider the need for timely antifungal therapy.

The transmission of pathogens such as fungi via PF is a potential cause of infection in transplant recipients [15]. Historically, the first reports of the clinical consequences of these infections were made in the setting of kidney transplantation, where indeed several publications reported a yeast contamination of PF with an incidence ranging from 0.1% to 3.1% [4,17–19]. Mycotic arteritis and/or an aneurysm on an arterial anastomosis was described in two-thirds of cases following such contamination, leading to vascular rupture responsible for graft loss and even the death of recipients [5,20]. But to our knowledge, little is known about the consequences of the yeast contamination of PF in LT. Case reports have been previously reported mainly in candidiasis peritonitis or mycotic hepatic arterial aneurysms which ultimately led to the patient's death [7,8]. In our observational retrospective study which has specifically screened each case of yeast PF contamination, we observed 28.6% rate of complications. This rate appeared to be lower than that seen in a renal transplant setting. This difference might be explained by the greater use of prophylactic antifungal treatment after LT than after kidney transplantation. Two-thirds of the yeast-related complications concerned vascular arteritis (aneurysm and artery hepatic rupture) ($n = 6$, 21% of recipients) which had a fatal outcome in 66% of cases. These vascular complications had previously been described after kidney transplantation [17,20]. All the species of *Candida*, and particularly *C. albicans*, are known to display vascular tropism and to be capable of penetrating

endothelial cells, leading to the destruction of vascular structures [21,22]. In the present study, several types of *Candida* were responsible for the aneurysmal formation (*C. albicans* $n = 3$, *C. glabrata* $n = 1$, *C. lusitaniae* $n = 1$ and *C. kefyr* $n = 1$), whereas no case involving *C. glabrata* and *C. kefyr* had previously been reported in the context of either renal or liver transplantation [22].

Because of the high morbidity associated with complications related to yeast contamination, it would be helpful to be able to identify risk factors for these complications. Under univariate analysis, the donor being treated with antibiotics during his or her ICU stay and the procurement was the only factor associated with these complications. It is possible that these antibiotics might have selected the yeasts from the donor gastrointestinal tract. Note should also be made of the fact that the modalities of antifungal therapy received after LT (prophylaxis, time of initiation of appropriate treatment, duration of treatment) were not associated with the occurrence of complications. This results may be related to a lack of statistical power required to detect a significant difference in antifungal treatment between the patients who did or did not develop candidiasis complications. However, these results may also suggest that postoperative screening of vascular abnormalities should be considered whatever the antifungal therapy.

At present, the optimum therapeutic strategy for the yeast contamination of PF in liver transplantation remains a subject of debate and no consensus has been achieved [9,15]. The initiation of antifungal therapy is recommended, although in our study, of the six patients with PF contamination who did not receive any antifungal treatment (prophylactic or curative), only two developed a candidiasis complication. Nevertheless, our findings show that the choice of antifungal therapy requires identification of the *Candida* species. Indeed, in seven cases (25%), the infection was due to azole-resistant *Candida* or intermediate resistance with variable minimum inhibitory concentrations [*C. glabrata* ($n = 7$)]. When these species are found, echinocandins could be recommended. As for the duration of treatment, 15-day period was the most frequently proposed [15] or the treatment was pursued until a negative culture (of peritoneal fluid, etc.) was obtained [4,7].

The principal limitation of our study was its retrospective nature which did not allow us to demonstrate by genetic or molecular analysis that *Candida* affecting the PF was the source of infection in the recipient. This retrospective design implied that some parameters (such as the yeast concentration in the PF and isolates conserved) were unavailable to definitively understand the role of yeasts contamination of the PF and candidiasis complications. We are aware that in our study, there was no definitive

proof, only circumstantial evidence, that the PF *Candida* affecting the PF was the source of infection in the recipient. In the French recommendations about fungal and bacterial contamination [9], it is recommended to keep isolates in order to compare strains if necessary. Unfortunately, these recommendations are not always followed. However, the incidence of aneurysm (21%) observed in our cohort was greater than usually reported in the literature (ranging from 0.4 to 2.5%) [23–25]. In addition, the incidence of hemorrhagic shock related to rupture of the hepatic artery was greater than that observed in patients without yeast PF contamination, that is, 0.6% (analysis performed on 1276 patients from three centers). Typically, vascular *Candida* infection leading to anastomotic leak and/or vessel rupture as previously described in renal transplantation [16] is due to the ability of the *Candida*, especially *C. albicans*, to penetrate into endothelial cells, leading to destruction of vascular structures [22]. These results emphasize the link between yeast PF contamination and post-LT vascular complications.

In order to make the epidemiological association between the cultures and post-transplant infection, a control group with negative cultures would need to be explored in large prospective study. However, this study may be difficult to conduct because of the small incidence of PF contamination with yeast.

Meanwhile, based on these results (notably a high rate of vascular arteritis), the early and close radiologic follow-up screening of these patients could probably be strongly recommended to enable the early detection of silent ongoing endovascular pathological processes and the proposal of preventive treatment before any potential rupture.

In conclusion, the incidence of PF contamination by yeast is low. However, this contamination is associated with a high rate of vascular complications (21%) with a 60% mortality rate. Only the antibiotic treatment in the donor has been identified as a risk factor for candidiasis complications after PF contamination. The use of antifungal treatment did not seem to prevent the occurrence of vascular complications. Based on our results, we recommend a strict follow-up of hepatic artery radiological abnormalities after PF contamination to keep all bacteria and yeasts isolated to PF for at least b. This may be useful for early recognition and treatment of these dramatic complication.

Authorship

EL, CPB, FB and FS: participated in research design. EL, JCM, LKE, BJ, MF, LS and LM: collected data. EL, CPB and FB: participated in the writing of the paper. EL, CPB and FB: participated in data analysis. CPB, FB, FS and BJ: participated in the performance of the research.

Funding

No funding or financial support was received for this study.

Acknowledgements

The authors would like to thank Drs. I. Accoceberry, E. Bailly, J. Chandénier, F. Foulet, S. Jaber, L. Lachaud A. Prades, F. Remérand, S. Rousset, and A. Toussaint for assistance with data management.

References

1. Janny S, Bert F, Dondero F, *et al.* Microbiological findings of culture-positive preservation fluid in liver transplantation. *Transpl Infect Dis* 2011; **13**: 9.
2. Audet M, Piardi T, Panaro F, *et al.* Incidence and clinical significance of bacterial and fungal contamination of the preservation solution in liver transplantation. *Transpl Infect Dis* 2011; **13**: 84.
3. Cerutti E, Stratta C, Romagnoli R, *et al.* Bacterial- and fungal-positive cultures in organ donors: clinical impact in liver transplantation. *Liver Transpl* 2006; **12**: 1253.
4. Botterel F, Foulet F, Legrand P, *et al.* Yeast contamination of kidney, liver and cardiac preservation solutions before graft: need for standardisation of microbial evaluation. *J Hosp Infect* 2010; **76**: 52.
5. Matignon M, Botterel F, Audard V, *et al.* Outcome of renal transplantation in eight patients with *Candida* sp. contamination of preservation fluid. *Am J Transplant* 2008; **8**: 697.
6. Mai H, Champion L, Ouali N, *et al.* *Candida albicans* arteritis transmitted by conservative liquid after renal transplantation: a report of four cases and review of the literature. *Transplantation* 2006; **82**: 1163.
7. Addeo P, Saouli AC, Woehl-Jaeglen ML, *et al.* *Candida albicans* arteritis transmitted by preservation fluid after liver transplantation. *Ann Transpl* 2014; **19**: 64.
8. Levesque E, Suet G, Merle JC, *et al.* *Candida* vascular complication in a liver-transplant recipient due to yeast preservation solution contamination. *Transpl Infect Dis* 2014; **16**: 827.
9. Agence de la Biomédecine. Prévention de la transmission de bactéries et d'agents fongiques aux receveurs d'organes. Recommandations professionnelles. Septembre 2008.
10. Feng S, Goodrich NP, Bragg-Gresham JL, *et al.* Characteristics associated with liver graft failure: the concept of a donor risk index. *Am J Transplant* 2006; **6**: 783.
11. Dindo D, Demartines N, Clavien PA. Classification of surgical complications: a new proposal with evaluation in a cohort of 6336 patients and results of a survey. *Ann Surg* 2004; **240**: 205.
12. Gavalda J, Meije Y, Fortún J, *et al.* Invasive fungal infections in SOT recipients. *Clin Microbiol Infect* 2014; **20**(Suppl. 7): 27.
13. Grąt M, Ligocka J, Lewandowski Z, *et al.* Incidence, pattern and clinical relevance of microbial contamination of preservation fluid in liver transplantation. *Ann Transplant* 2012; **17**: 20.
14. Levesque E, El Anbassi S, Sitterle E, Foulet F, Merle JC, Botterel F. Contribution of (1,3)-beta-D-Glucan (BG) to the diagnosis of invasive candidiasis after liver transplantation. *J Clin Microbiol* 2015; **53**: 771.
15. Singh N, Huprikar S, Burdette SD, *et al.* Donor-derived fungal infections in organ transplant recipients: guidelines of the American Society of Transplantation, infectious diseases community of practice. *Am J Transplant* 2012; **12**: 2414.
16. Yannam GR, Wrenshall L, Stevens RB. Loss of renal allografts secondary to *Candida* vascular complications in two recipients from the same donor. *Case Rep Transplant* 2012; **2012**: 364735.
17. Albano L, Bretagne S, Mamzer-Bruneel MF, *et al.* Evidence that graft-site candidiasis after kidney transplantation is acquired during organ recovery: a multicenter study in France. *Clin Infect Dis* 2009; **48**: 194.
18. Wakelin SJ, Casey J, Robertson A, *et al.* The incidence and importance of bacterial contaminants of cadaveric renal perfusion fluid. *Transpl Int* 2005; **17**: 680.
19. Majeski JA, Alexander JW, First MR, Munda R, Fidler JP, Craycraft TK. Transplantation of microbially contaminated cadaver kidneys. *Arch Surg* 1982; **117**: 221.
20. Canaud G, Timsit MO, Zuber J, *et al.* Early conservative intervention for *Candida* contamination of preservative fluid without allograft nephrectomy. *Nephrol Dial Transplant* 2009; **24**: 1325.
21. Ren Z, Litovsky S, Eckhoff DE, DuBay DA. Hemorrhagic shock one month following uncomplicated liver transplantation. *Am J Transplant* 2014; **14**: 1461.
22. Sanchez AA, Johnston DA, Myers C, Edwards JE Jr, Mitchell AP, Filler SG. Relationship between *Candida albicans* virulence during experimental hematogenously disseminated infection and endothelial cell damage *in vitro*. *Infect Immun* 2004; **72**: 598.
23. Iida T, Kaido T, Yagi S, *et al.* Hepatic arterial complications in adult living donor liver transplant recipients: a single-center experience of 673 cases. *Clin Transplant* 2014; **28**: 1025.
24. Volpin E, Pessaux P, Sauvanet A, *et al.* Preservation of the arterial vascularisation after hepatic artery pseudoaneurysm following orthotopic liver transplantation: long-term results. *Ann Transpl* 2014; **19**: 346.
25. Panaro F, Miggino M, Bouyabrine H, *et al.* Reversed saphenous bypass for hepatic artery pseudoaneurysm after liver transplantation. *Ann Vasc Surg* 2013; **27**: 1088.