



**HAL**  
open science

## Titanium Implant Failure After Chest Wall Osteosynthesis

Philippe Berthet, Abel Gomez Caro, Laurence Solovei, Matthieu Gilbert,  
Sebastien Bommart, Philippe Gaudard, Ludovic Canaud, Pierre Alric,  
Charles-Henri Marty-Ané

► **To cite this version:**

Philippe Berthet, Abel Gomez Caro, Laurence Solovei, Matthieu Gilbert, Sebastien Bommart, et al..  
Titanium Implant Failure After Chest Wall Osteosynthesis. *Annals of Thoracic Surgery*, 2015, 99 (6),  
pp.1945 - 1952. 10.1016/j.athoracsur.2015.02.040 . hal-01756816

**HAL Id: hal-01756816**

**<https://hal.umontpellier.fr/hal-01756816>**

Submitted on 30 Jan 2020

**HAL** is a multi-disciplinary open access archive for the deposit and dissemination of scientific research documents, whether they are published or not. The documents may come from teaching and research institutions in France or abroad, or from public or private research centers.

L'archive ouverte pluridisciplinaire **HAL**, est destinée au dépôt et à la diffusion de documents scientifiques de niveau recherche, publiés ou non, émanant des établissements d'enseignement et de recherche français ou étrangers, des laboratoires publics ou privés.

# Titanium Implant Failure After Chest Wall Osteosynthesis

Jean-Philippe Berthet, MD, PhD, Abel Gomez Caro, MD, PhD, Laurence Solovei, MD, Matthieu Gilbert, MD, Sébastien Bommart, MD, PhD, Philippe Gaudard, MD, Ludovic Canaud, MD, PhD, Pierre Alric, MD, PhD, and Charles-Henri Marty-Ané, MD, PhD

Thoracic Surgery Department, University Hospital Arnaud de Villeneuve, Montpellier; U1046, INSERM, Montpellier University, Montpellier, France; and General Thoracic Surgery Department, Hospital Clinic, University of Barcelona, Barcelona, Spain

**Background.** Our objective was to assess potential contributing factors to implant failure (displacement or rupture) after titanium chest wall osteosynthesis.

**Methods.** We retrospectively reviewed the clinical data and preoperative and postoperative computed tomographic scans of patients undergoing chest wall osteosynthesis with titanium implants: the Stratos or the Matrix Fixation System in two European departments of thoracic surgery. The indications for titanium chest wall osteosynthesis, the type and number of implants, the topography of the reconstruction, surgical site infection, and role of associated flap and mesh were assessed.

**Results.** Between January 2009 and January 2013, 54 patients underwent osteosynthesis after surgical correction of chest wall deformities ( $n = 25$ , 46.2%) or to bridge the defect after tumor removal ( $n = 29$ , 53.7%). The topography of osteosynthesis was anterior ( $n = 20$ ), lateral ( $n = 3$ ), or posterior ( $n = 1$ ), an average of  $1.9 \pm 0.9$  implants (range, 1 to 5 implants) being used. A combined mesh restored continuity of the chest wall in 15 patients,

and muscle flap coverage was performed in 20. The mean follow-up time was  $20.2 \pm 8.4$  months (range, 3 to 48 months). Among these 54 patients, 24 (44%) experienced an implant failure. Seven (29%) were symptomatic. Broken ( $n = 20$ , 83.3%) or displaced ( $n = 4$ , 16.7%) implants were removed with or without replacement. In patients with broken or displaced implants, the mean duration without implant failure was  $6.6 \pm 3.1$  months (range, 1 to 12 months). There was a significant relationship between the anterior topography of osteosynthesis and implant failure ( $p = 0.02$ ).

**Conclusions.** Long-term follow-up after chest wall osteosynthesis using titanium implants is required, especially in anteriorly placed implants. The high rate of implant failure at 1 year advocates for early removal whenever possible and suggests the need for improvements in design.

Chest wall reconstruction after oncologic resections, repair of chest wall deformities (pectus excavatum, carinatum, and arcuatum), and flail chest management has been reported to be easier and to be optimized with the use of novel titanium implants as a rib-and-sternum osteosynthesis system [1–4]. Thus, titanium chest wall osteosynthesis (TCWO) is currently indicated to reestablish the rigidity of the chest wall and ensure its stability [1, 2, 4].

TCWO has been reported to prevent paradoxical motion of the chest wall during the early postoperative course [1, 2] and to maintain chest wall shape after treatment for pectus deformities [4, 5]. Last, functional and aesthetic issues can be avoided when TCWO has been appropriately used for reconstruction [1, 2, 6].

In support of TCWO, several reports have underlined the drawbacks of some thoracic implants (Kirschner pins,

stainless steel bars, methylmethacrylate sandwich), such as technical difficulties, time-consuming operations, the need for experienced hands, and numerous local complications (early rupture, extrusion, infection) [1, 2, 7]. A decrease in the rate of infectious complications to 4% [1] and low rates (13%) of early implant rupture [2] since the introduction and use of modern titanium implants has been described and analyzed as being related to the technical specifications of titanium implants.

However, considering cases of titanium implant rupture [8], displacement, or implementation difficulties, modern TCWO has been described as “less than perfect” [8, 9]. For others, TCWO is unable to resist metal fatigue resulting from the numerous respiratory movements [2, 10]. Data regarding the long-term reliability of titanium implants are not available among reports [4, 11] dealing with TCWO indicated for elective surgical procedures (from the immediate postoperative course to a mean of 6 postoperative months [2–14]) and are considered to be interesting [5, 8, 10].

To better understand titanium implant failure (displacement or fracture) after TCWO, we aimed to focus

on the potential clinical and morphologic contributing factors by reporting the experience at two surgical centers using similar therapeutic strategies.

## Material and Methods

From the patient records of TCWOs performed in our thoracic surgery departments, both in university hospitals (Montpellier and Barcelona), from January 2009 to January 2013, we systematically checked clinical examination reports, chest roentgenograms, and computed tomography (CT) scan images obtained during follow-up. We selected patients with TCWO indicated for elective operations (trauma cases were excluded). All patients initially operated on in our thoracic surgery departments received oral and written information before consenting to TCWO. Both hospitals implemented similar therapeutic and operative strategies consisting of rigid reconstruction using titanium implants, and the treatment plans were approved by a multidisciplinary committee. Both ethics committees approved this study. Briefly, TCWO was indicated in large chest wall defects defined as any resection involving more than three ribs or a combined resection of three ribs (at least) and the sternum. TCWO was not indicated in resections of fewer than three ribs and those located in the posterior chest wall beneath the scapula [2]. TCWO was indicated in pectus carinatum, in pectus arcuatum, and in severe asymmetric pectus excavatum considered inappropriate for the Nuss procedure.

The implants used for TCWO were either the Stratos (Strasbourg thoracic osteosynthesis system, MedXpert GmbH, Heitersheim, Germany) or the Matrix Fixation System (DePuy Synthes, West Chester, PA). The Stratos implants were placed as previously described [2], and the Matrix implants were placed as described by Voss and colleagues [12]. The Stratos system combines two rib clips and a connecting bar. The Matrix system is based on plate-and-screw osteosynthesis. The technical characteristics of both systems are given in Table 1.

### Initial Titanium Chest Wall Osteosynthesis

Patients with two types of TCWO were included, depending on the initial pathologic condition (tumor

removal, pectus deformity correction) needing chest wall defect bridging or chest wall support:

### Chest Wall Defect Bridging

Chest wall resection for a primary chest wall tumor or T3/T4 non-small cell lung carcinoma (NSCLC) can lead to a larger chest wall defect. As previously described [2, 7], the key principle of chest wall reconstruction is to restore the continuity and the rigidity of the chest wall and to cover all the synthetic hardware in a one-step surgical procedure. To do so, we used titanium implants to bridge the defect, along with polytetrafluoroethylene mesh (W. L. Gore & Associates, Inc, Flagstaff, AZ) or polyglactin mesh Vicryl 910, Ethicon, Inc, Somerville, NJ) sewn to the implants and ribs under maximum tension. A muscular or omental flap was used to cover the material. According to the location of the defect, the reconstruction was anterior, lateral, or posterior.

### Chest Wall Support

Severe asymmetric pectus excavatum was repaired by use of an open technique through a transverse or infra-mammary skin incision. Our standard technique was a modified Ravitch procedure with overcorrection of the deformity. After pectoralis major flap mobilization, appropriate segments of costal cartilage (third to common costal cartilage) were resected from the chondrosternal junction, and a wedge osteotomy was performed across the anterior cortex of the upper sternum at the site of maximum angulation. In consideration of the risk of deformity recurrence [8, 13], one to three implants were passed below the body of the sternum and secured bilaterally to the ribs with clips or screws, respectively. Pectus carinatum was repaired by the same strategy except for the osteosynthesis, which was performed anterior to the sternum.

In both indications, the choice of the implant, either Stratos or Matrix, depended on the surgeon's experience. Both types of implants are characterized by a connecting bar or plate and a rib fixation system; TCWO was performed by fixing the implant to intact segments of ribs distant from the operative field; chest wall stability was the main intraoperative goal and was assessed by the surgeon; and chest wall stability required one or more

Table 1. Technical Characteristics of the Thoracic Osteosynthesis Systems Used

Characteristic	DePuy Synthes	MedXpert
Osteosynthesis system	MatrixRib and MatrixMandible	Stratos
System features	Plate and screw	Bar and clip
Material (implant/rib fixation)	Pure titanium/titanium alloy	Titanium alloy
Plate thickness	1.0 to 2.8 mm	Unknown
Technology	Conical locking technology for screw to plate security	Grip locking technology for bar to clip security
Profiles and edges	Rounded	Rounded
Adaptable length and shape	Yes	Yes
Variable thickness and largeness	Yes	No
AO basic principle conformity	Yes	No

implants, depending on the location and size of the defect, and was obtained without the systematic rebuilding of all involved ribs.

The different types of implants and procedures are shown in [Figures 1 and 2](#), respectively.

### Implant Management and Failure

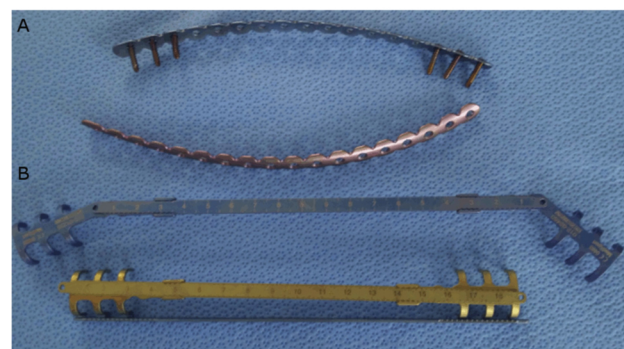Titanium implants used to support the sternum after a modified Ravitch procedure were removed 12 to 18 months after operation. We did not plan to remove implants used as a defect bridge, and we scheduled classic follow-up visits according to tumor type. Implants were systematically removed in the case of failure to avoid their invasion of soft tissues or the risk of displacement across the mediastinum [8, 14, 15].

Implant failure was assessed on chest roentgenogram confirmed by computed tomographic (CT) scan and involved at least one of the following criteria: (1) fracture of the rib fixation system (clip or screw), (2) fracture of the connecting bar or plate, or (3) displacement without fracture of bars, plates, screws, or rib clips, or disconnection between the bar and clip. A distortion of the implant, involving the curvature of the bar or plate, was not identified as an implant failure but was recorded. The different types of implant failure are shown in [Figure 3](#).

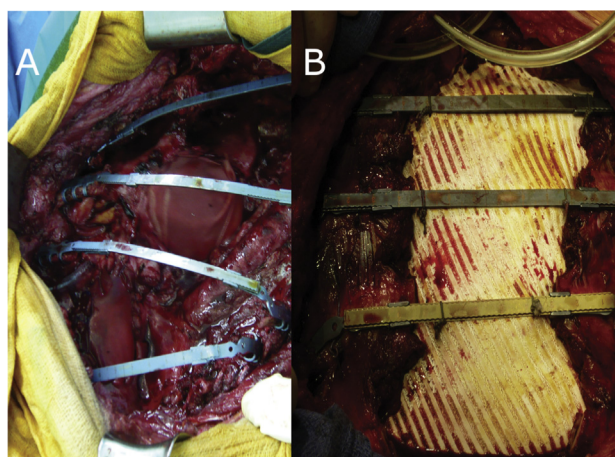
### Data and Follow-Up

Surgical data were obtained from operation notes, pathologic reports, and postoperative care reports of perioperative complications.

Chest roentgenograms and thoracic contrast CT scans with multiplanar reconstruction (for chest implant integrity surveillance) were performed before discharge and were scheduled every 3 months for the first year and every 6 months until implant removal, or for 5 years after tumor removal. The presence of either unusual chest pain or recurrence after a symptom-free period, or swelling in contact with the implants, was considered to be related to a chest wall reconstruction difficulty and indicated a dedicated chest roentgenogram. In case of doubt regarding implant failure, a CT scan was then performed.



*Fig 1. Different types of implants associating a connecting bar or plate and rib fixation system. (A) Plate and screw (Matrix, DePuy Synthes). (B) Bars and clips (Stratos, MedXpert).*



*Fig 2. Large defect bridging after tumor resection. (A) Lateral defect of the left chest wall; reconstruction with four Stratos implants associating bars and clips (Stratos). (B) Anterior defect of the chest wall; reconstruction with a combination of bars and clips (Stratos) and 2-mm-thick polytetrafluoroethylene mesh.*

Data concerning the indication, the type of procedure, the number of resected ribs, the extent of sternal resection, the location and extent of chest wall reconstruction, the type of implants used, reconstruction results, possible infection of the operative site [7], and morbidity and mortality were collected.

### Statistical Analysis

All values are expressed as means  $\pm$  standard deviations. Quantitative variables were compared when appropriate, with a level of significance of  $p < 0.05$ . The expected survival in months without implant failure was calculated by means of survival charts, with Kaplan-Meier and log rank tests for the comparison of curves for indications, extent of TCWO, type and number of implants, and association with a mesh or flap. The expected survival time in months without implant failure was calculated from the day of operation until proof of implant rupture or displacement, or the date of last follow-up without implant failure. Implant failures occurring within 30 days of the operation were taken into account.

## Results

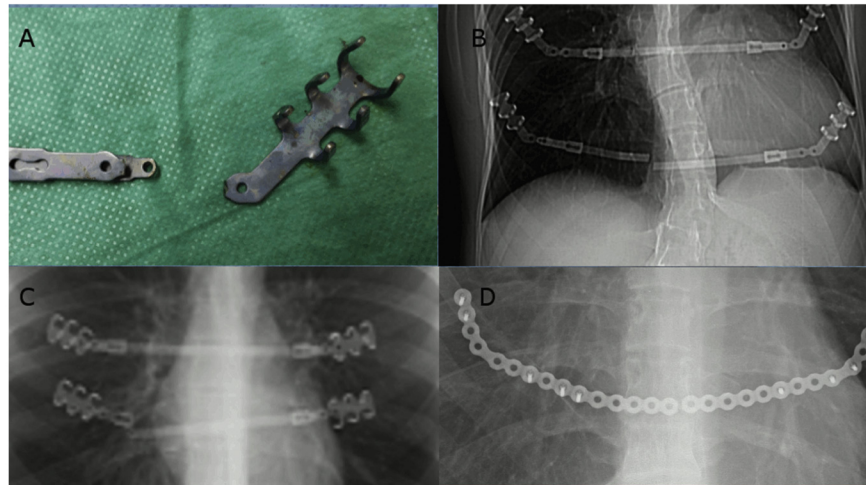
### Patient Profile

Between January 2009 and January 2013, of 184 chest wall reconstructions, 23 (12.5%) were performed for chest wall trauma, 117 (63.5%) for correction of chest wall deformities, and 44 (23.9%) for defect management (with and without osteosynthesis) after tumor removal.

Titanium chest wall osteosynthesis was performed in 54 patients (29.3%) (39 male) with a median age of  $44.7 \pm 23.6$  years (range, 7 to 79 years). Twenty-one (38.8%) patients were younger than 30 years.

The indications for TCWO and the type of implants used are given in [Table 2](#). A single implant was used in 21 cases (38.8%), two implants in 22 cases (40.7%), and more

Fig 3. Different types of implant failure. Stratos; MedXpert: (A) Fracture of the rib fixation system at the joint, this part has been reinforced by the manufacturer. (B) Fracture of the connecting bar. (C) Disconnection between bar and clip. Matrix mandible, DePuy Synthes: (D) fracture of the plate.



than two implants in 11 cases (20.5%). The location of TCWO was anterior (n = 27), lateral (n = 14), both anterior and lateral (n = 10), or posterior (n = 3). The sternum was bridged or supported in 35 cases (64.8%). TCWO was combined with a mesh in 23 cases (42.6%) or a flap in 44 cases (81.4%).

The mean follow-up time was  $20.2 \pm 8.4$  months (range, 3 to 48 months). No patients were lost to follow-up.

### Objectives of TCWO

**CHEST WALL DEFECT BRIDGING.** All patients but 1 (1.8%) underwent a complete R0 resection with removal of  $4.2 \pm 1.5$  ribs (range, 3 to 8 ribs). TCWO was performed with the use of  $2.0 \pm 0.9$  implants (range, 1 to 5 implants), it was associated with a mesh in 23 cases (79.3%), and a flap was used to cover the synthetic framework in 22 cases (75.8%). The reconstructed chest wall area was  $189 \pm 85.1$  cm<sup>2</sup> (range, 110 to 370 cm<sup>2</sup>). We succeeded in reestablishing the rigidity of the thoracic wall in all patients but 1 (1.8%), who experienced postoperative flail chest and respiratory failure that required prolonged mechanical ventilation.

There was one postoperative death related to massive cardiac failure.

**CHEST WALL SUPPORT.** A satisfactory chest contour was obtained intraoperatively in all patients with pectus deformity. The reconstructed chest wall area was  $166 \pm 58$  cm<sup>2</sup> (range, 83 to 260 cm<sup>2</sup>). Sternum stabilization by means of  $1.84 \pm 0.4$  implants (range, 1 to 3 implants) (2 implants in 76% of cases) was obtained in all cases during the early postoperative period. The median in-hospital stay was  $6.4 \pm 1.6$  days (range, 5 to 12 days), including a median stay of 1.2 days in the intensive care unit.

### Implant Failure

Twenty-four patients (44.4%) experienced implant failure. The characteristics of implant failure are reported in Tables 3 and 4. Implant rupture or displacement was expected in all but 7 patients from an analysis of the chest roentgenograms. A CT scan with multiplanar reconstruction identified the rupture in these cases. All implant failures occurred within 14 months after operation, including 65% between the 6th and 14th months.

Table 2. Indications for Using MedXpert and Synthes Osteosynthesis Systems

System	Demographics 54 Patients Age $44.7 \pm 23.6$ (7–79) Years	Indication	
		Chest Wall Defect Bridging (Tumor Removal) Type of Tumor n = 29 (53.7%)	Chest Wall Supporting (Pectus Deformity) n = 25 (46.3%)
MedXpert (Stratos)	47 (87%)	27 Primary tumor = 24 Secondary tumor = 3	20 PE = 13, PC = 6, PA = 1
Synthes (Matrix)	7 (13%)	2 Primary tumor = 2 Secondary tumor = 0	5 PE = 4, PC = 1, PA = 0
Mean number of implants used	$1.9 \pm 0.9$ (1–5)	Mean = $2.0 \pm 0.9$ (1–5)	Mean = $1.8 \pm 0.4$ (1–3)

Primary tumors were 14 sarcoma and 12 T3/T4 non-small cell lung cancer.

PA = pectus arcuatum; PC = pectus carinatum; PE = pectus excavatum.

Table 3. Implant Failure in 24 Patients

Global Population n = 54	Population With Implant Failure n = 24 (44.4%)				Symptomatic Implant Failure n = 7 (29.1%)
	Postoperative Course	Implant Deformation	-n- Evidence of Failure on Chest Roentgenogram	Indications for Implant Removal	
Chest wall defect bridging (Tumor removal) n = 29 (53.7%)	Flail chest with respiratory failure = 1 (1.8%) Secondary infection = 3 (5.5%)	n = 5	-13 (54.1%) -n = 7(53.8%)	Symptomatic failure 3 (12.5%) Removal related to failure 10 (41.6%)	Pain = 2 Skin wound = 2 Swelling = 1
Chest wall supporting (Pectus deformity) n = 25 (46.3%)	Flail chest with respiratory failure = 0 Secondary infection = 1 (1.8%)	n = 17	-11 (45.9%) -n = 10(90.9%)	Symptomatic failure 4 (16.6%) Removal related to failure 7 (29.1%)	Pain = 4 Skin wound = 0 Swelling = 3

No severe event occurred related to implant failure, but the skin was pierced or in danger of being pierced (n = 6) and the pericardium was in danger of being pierced (n = 3).

The implant was broken in 83.3% of patients and displaced in 16.7%. The rupture of the implant occurred at the level of the clip (n = 7) where it is angled to be adapted to rib shape at the bar (n = 10) or at the plate (n = 2). Implant displacement consisted of loose implants (disjunction between the rib and clip (n = 1) or disjunction between clips and bars (n = 3) (Fig 4). Interestingly, deformations (anteroposterior bending) of the Stratos implants occurred in 22 patients (40.7%) and were associated with rupture in 13 cases. No deformations occurred with the Matrix system.

Among the population with implant failure, the mean duration without implant failure was  $6.6 \pm 3.1$  months (range, 1 to 12 months). The global proportion of undamaged implants during follow-up is shown in Figure 4.

Factors contributing to implant failure were as follows: among factors potentially contributing to implant failure given in Table 2, two significantly influenced the survival curve without implant failure (Figs 5 and 6): the anterior location of TCWO ( $p = 0.01$ ) and the presence of three or more implants ( $p = 0.03$ ). The initial pathologic condition, type of implants, extent of the defect, and combination of flap or mesh did not influence the risk of implant failure.

### Comment

The use of implants is recommended to maintain the shape of the correction during the healing of cartilages after open techniques for chest wall deformities and to avoid paradoxical motion of the chest wall by restoring chest wall rigidity after the removal of large chest wall tumors [1–8]. The feasibility of TCWO and impressive early results have been described with the Stratos [2, 4] and Matrix implants [12, 16], both characterized by rib fixation. Titanium implants are currently preferred because of their well-known intrinsic qualities [1, 2, 3, 7] and are therefore considered compatible with long-term or permanent implantation. However, cases of implant failure are increasingly reported, demonstrating defects of the implants [8], the risk of dangerous potential intrapericardial migration [5, 14, 15, 17], and cases of untimely rupture or bending [18]. By analyzing cases of scheduled TCWO performed in two university hospitals for deformity and defect bridging, this study assesses the long-term results of TCWO.

Our main findings regarding implant failure are these:

1. A global rate of 44.4%. Failures are delayed until after the fourth postoperative month, excluding early postoperative implant displacement caused by technical issues as previously described [15], and none occur after the 14th postoperative month.
2. Most (87%) failures are asymptomatic.
3. The anterior location of TCWO is a significant risk factor.

Regarding postoperative results, TCWO has been considered reliable, complications being uncommon. We

Table 4. Proportion of Undamaged Implants According to Type and Number of Implants, Associated Flap and Mesh, and Indications

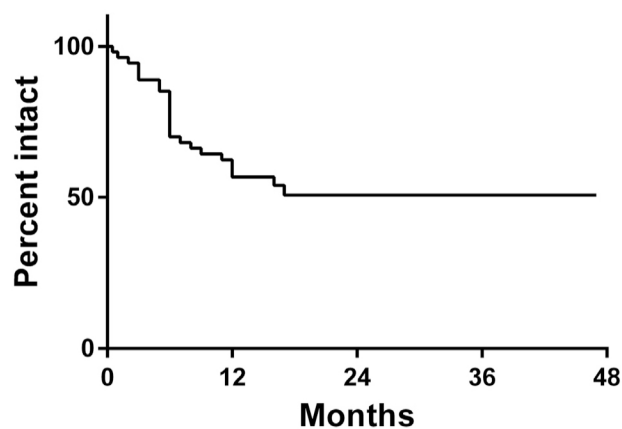
Type of Reconstruction	Global Population, n = 54 Population With Implant Failure, n = 24	Comparison of Curve X (Chi square) p (Log Rank)
Pectus deformity (support)	n = 25	0.26
Tumor (bridging)	n = 29	p = 0.6 NS
Bar and clip	n = 47	0.04
Plate and screw	n = 7	p = 0.83 NS
Sternum ± ribs TCWO	n = 37	6.42
Ribs only TCWO	n = 17	p = 0.01
One implant	n = 21	0.39
More than one implant	n = 33	p = 0.53 NS
More than 2 implants	n = 11	4.6
Fewer than 2 implants	n = 43	p = 0.03
Titanium implants	n = 31	2.2e005
Titanium implants + mesh	n = 23	p = 0.99 NS
Titanium implants	n = 10	2.4
Titanium implants + flap	n = 44	p = 0.12 NS

TCWO = titanium chest wall osteosynthesis.

previously reported a rupture rate of 10.5% after chest wall reconstruction [2]. By contrast, Fabre and colleagues [1] did not observe any failure. However, radiologic follow-up after TCWO is focused on evidence of cancer recurrence, not on TCWO systematically performed in for pectus repair. Moreover, TCWO failure is mainly reported when it is associated with a life-threatening intrapericardial migration of implants [14, 15, 17]. Therefore, we believe TCWO failure to be highly under-reported, explaining our 44.4% rate after systematic follow-up and dedicated CT scans to assess implants. Contrary to previous reports [15, 17], the ineffectiveness

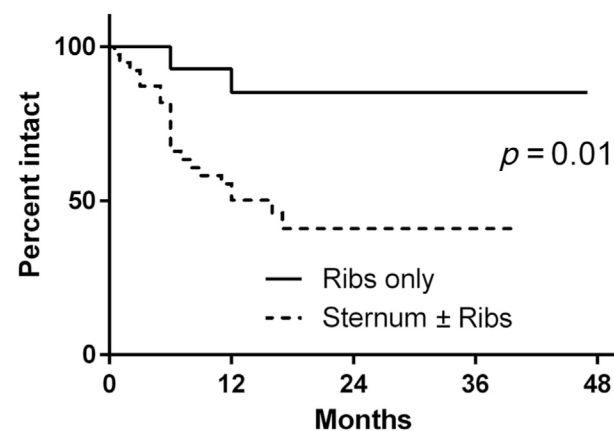
of chest roentgenography in detecting implant failure in 29.1% of patients and the low rate of symptomatic patients (12.7%) lead us to advocate for systematic CT scans during follow-up after TCWO.

The potential risk of cardiac, lung, and great vessel injury has led a few authors to recommend implant removal 6 to 18 months after open pectus excavatum repair, in preference to systematic follow-up, despite an increased risk of early deformity recurrence [17]. Conversely, titanium implant removal is generally not scheduled after chest wall defect bridging, in light of a potentially complicated operation.



months	1	12	24	36	48
<b>Titanium implant</b> No. at risk	53	33	10	5	2

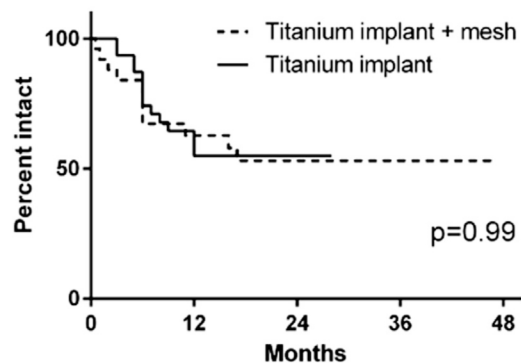
Fig 4. Global survival without implant failure.



months	1	12	24	36	48
<b>Sternum ± ribs</b> No. at risk	39	22	4	2	1
<b>Ribs only</b> No. at risk	15	14	5	3	1

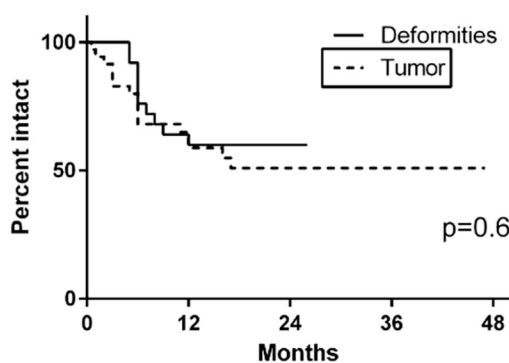
Fig 5. Survival without implant failure according to the location of chest wall defect and titanium chest wall osteosynthesis.

**A Not damaged implant proportions**



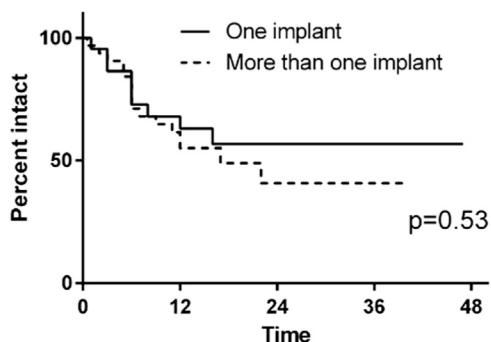
months	1	12	24	36	48
<b>Implant + mesh</b>					
No. at risk	25	14	7	5	2
<b>Implant</b>					
No. at risk	31	20	3	.	.

**B Not damaged implant proportions**



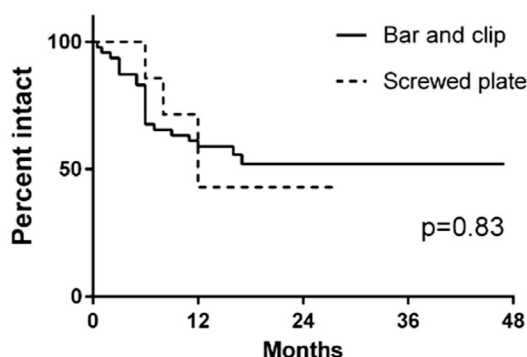
months	1	12	24	36	48
<b>Deformities</b>					
No. at risk	25	16	4	2	.
<b>Tumor</b>					
No. at risk	35	21	8	5	2

**C Not damaged implant proportions**



months	1	12	24	36	48
<b>One implant</b>					
No. at risk	22	14	8	3	1
<b>More than one implant</b>					
No. at risk	32	19	6	2	1

**D Not damaged implant proportions**



months	1	12	24	36	48
<b>Bar and clip</b>					
No. at risk	47	29	9	5	2
<b>Screwed plate</b>					
No. at risk	7	5	2	.	.

Fig 6. Survival without titanium implant failure according to the combination with (A) a mesh, (B) the indication for reconstruction, (C) the number of implants, and (D) the type of implants.

Aware of the potential risk of life-threatening complications, the manufacturer of the Stratos system has reinforced a point of minor resistance (joint), the designer and some surgical teams have advised that forces and pressures be better distributed by multiplying implants [4, 6, 11] or combining with a mesh [18], and others have proposed that implants be removed 6 to 12 months after repair [10, 19] or that stronger [5, 10], modified [9], or absorbable [20] fixation material be used. In our experience, the combination of TCWO with a synthetic mesh or flap did not lessen the failure rate.

The prevalence of implant rupture in the anterior portion of the chest wall may be related to the substantial displacement of the rib cage during inspiration in the cranial, lateral, and ventral directions. They are known to

be more important in the anterior and lower portions of the chest wall than elsewhere [21]. The continuous “bucket-handle” motion of the anterior portion of the chest wall subjects implants to stress rupture, which may be increased in terms of deformity owing to the additional ventral-to-posterior pressure of the reconstructed sternum. When an implant is located laterally, its posterior end is fixed to a motionless portion of the chest wall, which may explain the reliability of the device at this level [21, 22]. Considering the first reports of implant ruptures, we used stronger screwed plates (Matrix mandible DePuy Synthes) or multiple implants. Neither the use of thicker material (Matrix mandible DePuy Synthes) nor the multiplication of implants modified our rate of implant failure (Table 2), and, paradoxically, the use of three or



more implants was associated with a higher risk of rupture. We hypothesize that this was related to more extensive defects in these cases. Moreover, the multiplication of implants leads to a concern about the increased amount of prosthetic material, extensive dissection, increased intercostal pain, and significantly higher costs (€2680 for one bar fixed to two rib clips and €5360 when two bars are used [10]).

The population included in this study was not totally homogenous regarding the variety of pathologic conditions (tumor and deformity). This may conflict with a meaningful statistical comparison between subgroups. However, we do consider our study a first step in the understanding of titanium implant failure depending on TCWO topography.

Our experience seems to highlight issues regarding the principle of sternum support with a rib fixation system, particularly when implants have to be kept in place. The main concerns involve anterior defect bridging related to the necessity of fixation to disease-free segments of ribs or the sternum. With regard to the lateral portion of the chest wall, TCWO requiring horizontal or vertical rib, sternal fixation, or both showed long-term reliability.

In conclusion, potentially life-threatening TCWO failure is mainly asymptomatic and is sometimes undetectable by chest roentgenography, indicating a need for systematic follow-up by means of three-dimensional reconstruction of CT scan images. The high prevalence of early failure when used in the anterior portion of the chest wall advocates for early removal when possible, and it suggests that material design should be improved or alternative osteosynthesis devices should be used.

## References

1. Fabre D, El Batti S, Singhal S, et al. A paradigm shift for sternal reconstruction using a novel titanium rib bridge system following oncological resections. *Eur J Cardiothorac Surg* 2012;42:965–70.
2. Berthet JP, Canaud L, D'Annoville T, Alric P, Marty-Ane CH. Titanium plates and Dualmesh: a modern combination for reconstructing very large chest wall defects. *Ann Thorac Surg* 2011;91:1709–16.
3. Billè A, Okiror L, Campbell A, Simons J, Routledge T. Evaluation of long-term results and quality of life in patients who underwent rib fixation with titanium devices after trauma. *Gen Thorac Cardiovasc Surg* 2013;61:345–9.
4. Wihlm JM, Grosdidier G, Chapelier A. Thoracic osteosyntheses for chest wall malformations, traumas and tumors using the Stratos titanium system: initial experience. *Interact Cardiovasc Thorac Surg* 2007;6:273.
5. Wurtz A, Rousse N, Benhamed L, et al. Simplified open repair of pectus deformities. Analysis of results in 205 patients. *Orthop Traumatol Surg Res* 2012;98:319–26.
6. Mier JM, Fibla JJ, Molins L. Another application of the Stratos system for the correction of chest wall deformities. Repeat surgery of pectus excavatum after failure of Ravitch procedure. *Cir Esp* 2011;89:558–9.
7. Berthet JP, Solovei L, Tiffet O, et al. Chest-wall reconstruction in case of infection of the operative site: is there any interest in titanium rib osteosynthesis? *Eur J Cardiothorac Surg* 2013;44:866–74.
8. Stefani A, Nesci J, Morandi U. Stratos™ system for the repair of pectus excavatum. *Interact Cardiovasc Thorac Surg* 2013;17:1056–8.
9. Krüger M, Zinne N, Zhang R, et al. Multidirectional thoracic wall stabilization: a new device on the scene. *Ann Thorac Surg* 2013;96:1846–9.
10. Benhamed L, Hysi I, Wurtz A. eComment. Substernal metal support after pectus excavatum open repair. *Interact Cardiovasc Thorac Surg* 2013;17:1058.
11. Billè A, Okiror L, Karenovics W, Routledge T. Experience with titanium devices for rib fixation and coverage of chest wall defects. *Interact Cardiovascular Thorac Surg* 2012;15:588–95.
12. Voss B, Bauernschmitt R, Will A, et al. Sternal reconstruction with titanium plates in complicated sternal dehiscence. *Eur J Cardiothorac Surg* 2008;34:139–45.
13. Wurtz A, Hysi I, Rousse N, Benhamed L, Conti M. Simplified open repair of pectus deformities. Available at: <http://www.ctsnet.org/article/simplified-open-repair-pectus-deformities>.
14. Bibiloni Lage I, Khan K, Kaabneh A, Kendall S. Late coronary artery and tricuspid valve injury post pectus excavatum surgery. *Interact Cardiovasc Thorac Surg* 2013;17:748–50.
15. Aydemir B, Sokullu O, Hastaoglu O, Bilgen F, Celik M, Dogusoy I. Aorta-to-right ventricular fistula due to pectus bar migration. *Thorac Cardiovasc Surg* 2011;59:51–2.
16. Boerma LM, Bemelman M, van Dalen T. Chest wall reconstruction after resection of a chest wall sarcoma by osteosynthesis with the titanium MatrixRIB (Synthes) system. *J Thorac Cardiovasc Surg* 2013;146:e37–40.
17. Zhang R, Hagl C, Bobylev D, et al. Intrapericardial migration of dislodged sternal struts as late complication of open pectus excavatum repairs. *J Cardiothorac Surg* 2011;6:40.
18. Berthet JP, Wihlm JM, Canaud L, et al. The combination of polytetrafluoroethylene mesh and titanium rib implants: an innovative process for reconstructing large full thickness chest wall defects. *Eur J Cardiothorac Surg* 2012;42:444–53.
19. Onursal E, Toker A, Bostanci K, Alpagut U, Tireli E. A complication of pectus excavatum operation: endomyocardial steel strut. *Ann Thorac Surg* 1999;68:1082–3.
20. Tuggle DW, Mantor PC, Foley DS, Markley MM, Puffinbarger N. Using a bioabsorbable copolymer plate for chest wall reconstruction. *J Pediatr Surg* 2004;39:626–8.
21. De Groote A, Wantier M, Cheron G, Estenne M, Paiva M. Chest wall motion during tidal breathing. *J Appl Physiol* 1997;83:1531–7.
22. Jordanoglou J. Rib motion in health and disease. In: Roussos C (ed). *The Thorax. Part B: Applied Physiology* Vol. 85. 2nd ed. New York: Dekker; 1995:1071–98.